



Research Article

PALATAL RUGAE PATTERNS IN INDIVIDUALS IDENTIFICATION: A FORENSIC STUDY

Janardhanam Dineshshankar¹, Nalliappan Ganapathy², Thukanaykanpalayam Ragunathan Yoithappabhunath³, Vadivel Ilayaraja⁴, Arumugasamy Niranjana⁵ and Akbarsait Rosun⁶

^{1,2,3,4}Department of Oral and Maxillofacial Pathology, Vivekanandha Dental College for Women

⁵Department of Pedodontics and Preventive Dentistry Vivekanandha Dental College for Women

⁶Dental Surgeon, Amsa Dental Surgery

ARTICLE INFO

Article History:

Received 26th October, 2016

Received in revised form 7th November, 2016

Accepted 10th December, 2016

Published online 28th January, 2017

Key words:

Palatal Rugae, Rugae pattern, Forensic identification

ABSTRACT

Introduction: The anatomical folds of Rugae those are located on the anterior third of palate behind the incisive papillae. They are also known as "Plica palatine," and the study of these patterns is called Palatal rugoscopy. Rugae pattern will remain unchanged during life time of an individual. Personal identification can be possible based on the rugae pattern since palate would remain intact till 7 days after death, due to their internal position in the head when most other anatomical structures are destroyed or burned. Rugae pattern is as unique to a human as his or her fingerprints.

Objectives: The purpose of the study was to identify this present study is an attempt to determine the various patterns of rugae and to see which rugae pattern is predominant in male and female population.

Materials and Methods: 300 maxillary study models, 150 from each group are taken from the outpatient of Vivekanandha Dental College included in the present study. Palatal rugae pattern were examined in both sexes to see which pattern is predominant.

Results: The study revealed that although there were significant differences in the pattern of rugae in both genders. The females showed more of the wavy type of rugae, while males had curved type.

Conclusion: It can be concluded that different rugae patterns are present which show sexual dimorphism among the population. Rugae pattern can be used as a significant method for identification in forensic science.

© Copy Right, Research Alert, 2017, Academic Journals. All rights reserved.

INTRODUCTION

Personal identification represents one of the major issues in forensic odontology since dental identification can be used as the sole method for postmortem identification due to high resistance of dental tissue to adverse conditions such as fire, trauma and decomposition¹. Dental print, finger print², lip print³, denture coding^{4,5} and DNA comparison are the common forensic technique are used in the context of allowing fast and secure identification¹. Since they cannot be used all the time simple technique can be used successfully in human identification, such as "palatal rugoscopy" which is the study of palatal rugae⁶.

Palatal rugae are irregular transverse ridges of the mucosa in the anterior third of the palate, radiating from the palatine raphae behind the incisive papillae⁷. During the early intrauterine life period from 12th to 14th week they are formed and it will remain stable throughout the person's life and will not undergo any changes, except for increase in length as a normal process of growth¹. Physiologically, they are involved in the oral swallowing and improve the

relationship between food and taste receptors in the dorsal surface of the tongue. Palatal rugae were found to be stable in shape and structure during the life of the individual and are not changed by disease, trauma, chemicals or heat. Once formed, they remain in the same position and even if they are destroyed, are reproduced exactly on their original site⁷. Their stability is due to their anatomical position inside the oral cavity which makes them protected by the lips, cheeks, tongue, teeth and bone and prosthetic devices⁵. Also, they were found to withstand thermal effects in burn victims and decomposition changes for up to seven days after death. Therefore, Palatal rugae have been used in medicolegal identification processes and they have been equated with fingerprints due to their stability and uniqueness to individuals⁷.

Furthermore, palatal rugae can be used for identification of edentulous subjects when other odontological methods cannot be used. Many attempts have been done in this field to improve recording and analysis of data in order to develop an easy and reliable way for personal identification⁸. Several studies reported a significant association between rugae forms

and ethnicity which may represent a valuable finding in forensic investigations especially in disasters. Studies on the pattern of palatal rugae among female population of South India are limited⁹. Therefore, this present study is an attempt to determine the various patterns of rugae and to see which rugae pattern is predominant in male and female population, thereby highlighting the importance of palatal rugae in establishing person's identity.

MATERIALS AND METHODS

Materials for the study comprised of 300 subjects, 150 males and 150 females are taken from the outpatient of Vivekanandha Dental College and were chosen randomly and included in the present study. Maxillary impression trays were selected according to the shape and size of the patient's arches. Two levels of alginate impression material were taken in the scoop and mixed with 40 ml of water (using a measuring jar provided by the manufacturer), in a water/powder (W/P) ratio of 40 ml: 15 g, in a flexible rubber bowl with a mixing spatula. A vigorous figure-eight motion was used for mixing. The mix was immediately transferred to the impression tray for insertion into the patient's mouth. The tray was held passively and motionless during the setting of impression material. After about 2 minutes (setting time of Alginate), the tray was separated quickly from the teeth to avoid rocking and possible deformation of the fine areas of the impression. Excess material at the periphery was trimmed. Dental stone was mixed and poured on alginate impression tray. The cast was separated from the impression after 60 minutes. Base for the study casts was made using the base former and dental stone. Each cast was numbered for easy identification (Fig: 1). All the measurements were taken by a two observer. The rugae were highlighted by a sharp graphite pencil on the cast (Fig: 2).

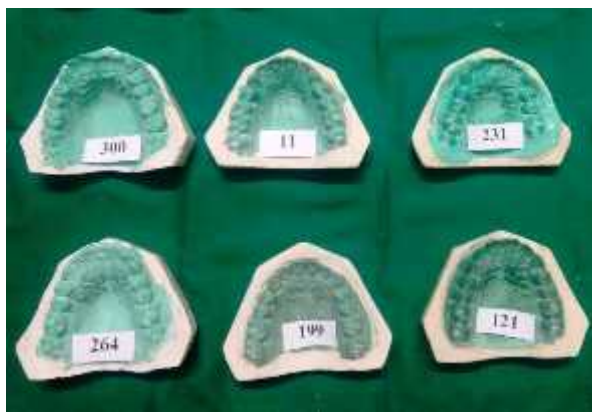


Figure.1 showing the cast was numbered for identification purpose

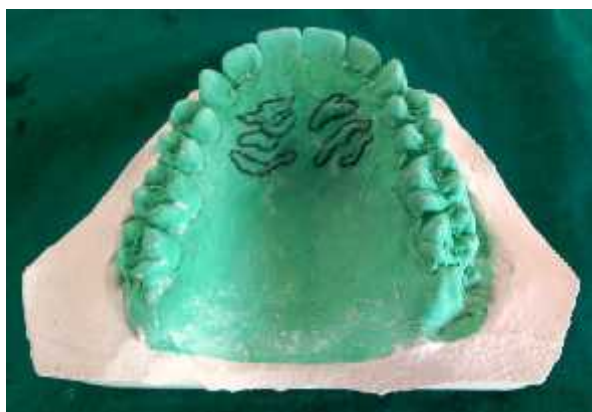

Figure.2 showing the highlighting of rugae on the cast with lead pencil

Classification of rugae pattern according to Thomas and Kotze¹⁰

The rugae were divided based on their shape as

- **Curved:** They had a crescent shape and curved gently. Evidence of even the slightest bend at origin or termination of rugae led to it being classified as curved rugae.
- **Wavy:** If there was a slight curve at the origin or termination of a curved ruga, it was classified away.
- **Straight:** They run directly from their origin to termination.
- **Circular:** Rugae that form a definite continuous ring were classified as circular rugae.
- Unification was said to have occurred when two rugae are joined at their origin or termination
- **Inclusion Criteria:**
 - Subjects without braces, removable partial dentures, fixed partial dentures and population belonging to outpatient of Vivekanandha Dental College were included.
- **Exclusion Criteria:**
 - The subjects with abnormalities of palate and lips like the cleft palate and cleft lip,
 - The subjects who were wearing partial dentures and braces were excluded.
 - The subjects with congenital anomalies/malformations, previous orthognathic surgery, bony and soft tissue protuberances, active lesions, deformity or scars and trauma of the palate were not selected.

RESULT

A total of 300 maxillary dental casts of 150 males and 150 females taken from the outpatients of Vivekanandha Dental College and were examined for the palatal rugae patterns by applying the classification of Thomas & Kotze. The occurrence of different rugae shapes in the two populations in the present study is presented in table 1. The Wavy rugae showed predominant pattern in females (78 out of 150) than males with a p value of 0.001 which shows that difference is highly statistically significant (table:1). Whereas curved rugae is more predominant pattern in males (80 out of 150) than in females with a p value of 0.001 which shows that difference is highly statistically significant (Table:1). Straight rugae are common forms in both groups. Circular rugae and unification constituted less than 10% of rugae in the entire sample of 300 casts.

Table 1

	Proportion				Z	P	Inference
	Male	Female	Male	Female			
Wavy	22	78	0.15	0.52	6.79	< 0.001	HS
Straight	35	55	0.23	0.37	2.65	0.008	HS
Curved	80	5	0.53	0.03	9.64	< 0.001	HS
Circular	5	7	0.03	0.05	0.884	0.379	NS
Unification	8	5	0.05	0.03	0.884	0.379	NS
	150	150	1.00	1.00			

DISCUSSION

The typical pattern of the palatal rugae does not change during growth of an individual and remains stable until the oral mucosa degenerates at death¹¹. Events such as extreme finger sucking in infancy, trauma, persistent pressure from

orthodontic treatment and dentures can contribute to the change in rugae patterns. Changes in rugae form seen in chemical aggression or trauma, diseases conditions, are less pronounced than those seen in the generalized body state. The palatal rugae have the ability to resist decomposition for up to seven days after death¹².

Researchers had found difficulty in the task of classification of the rugae patterns due to the subjective nature of observation and interpretation within and between observers. Thomas and Kotze in their literature highlighted the difficulties in observing, classifying and interpreting the limitless and minute variations in palatal rugae and emphasized the necessity for standardizing the procedures in recording¹⁰.

The present study was an attempt to determine the predominant pattern of rugae among the outpatients of Vivekanandha Dental College, trichengode. An attempt was also made to determine the differences in rugae pattern among two genders in the selected groups. Several studies done in the past have revealed and have statistically proved that the rugae patterns are highly individualistic and there are differences between races and gender.

In the present study, the wavy rugae were most common followed by straight rugae for females. It is different from other studies where curved form was found to be more common^{13, 14}. Among males in our study curved is more prominent followed by wavy and straight which is contradicted with Swetha.S et al in her study Wavy shapes were most commonly observed¹⁵ and also study by Aparna et.al straight pattern is predominant among Madhya Pradesh population¹³.

The present study found that wavy form was more in females than males, while curved form was more in males than female. This finding goes in accordance with Sandeep Goyal et al in their study of palatal rugae¹⁶. We also found that few are having circular and Unification pattern which is absent in the study done by preethi et.al on western and Indian population¹⁴. Thus the comparative study shows varying patterns of palatal rugae shapes between the populations. As proposed this may be due to the apparent lack of systemic trends and the need for more comprehensive understanding by further studies.

CONCLUSION

Overall stability and the uniqueness of palatal rugae pattern in individual are promising for forensic identification. In our study palatal rugae for male subjects showed curved pattern which is significantly predominant. Similarly we saw for the female subjects showed wavy pattern is significantly predominant. This needs further extensive study for establishing its significance in personal identification. Thus, analysis of palatal rugae pattern is a complementary technique for human identification, providing a significant contribution in cases of criminal investigation

References

1. Byatnal A, By atnal A, Kiran AR, Samata Y, Guruprasad Y, Telagi N. Palatoscopy: An adjunct to forensic odontology: a comparative study among five different populations of India. *J Nat Sci Biol Med* 2014; 5(1):52–5.

2. Yamunadevi A, Dineshshankar J, Banu S, Fathima N, Ganapathy, Yoithaprabhunath TR, Maheswaran T, Ilayaraja V. Dermatoglyphic patterns and salivary pH in subjects with and without dental caries: A cross-sectional study. *Journal of Natural Science, Biology and Medicine* 2015; 6 (2): 295-299
3. Dineshshankar J, Ganapathi N, Yoithaprabhunath TR, Maheswaran T, Kumar MS, Aravindhnan R. Lip prints: Role in forensic odontology. *J Pharm Bioallied Sci* 2013; 5:S95-7.
4. Venkateshwaran R, Manoharan PS, Karthikeyan S, Konchada J, Ramaswamy M, Janardhanam D. Denture markers: A comparison. *Journal of Indian Academy of Dental Specialist Researchers* 2014;1:9-11.
5. Dineshshankar J, Venkateshwaran R, Vidhya J, Anuradha R, Mary G P, Pradeep R, Senthilegappan AR. Denture bar-coding: An innovative technique in forensic dentistry. *J Pharm Bioallied Sci* 2015; 7(2):S350-353.
6. Deeksha Kiran Shetty, Priyanka S Machale, Suyog Chandrashekar Savant, Syed Ahmed Taqi. Comparison of palatal rugae patterns in Kodava and Malayalee populations of South India Year : 2013; 5(2): 85-89
7. Bharath TS, Govind Rajkumar N, Raghu D, Saraswathi TR. Sex determination by discriminant function analysis of palatal rugae from a population of Coastal Andhra. *Journal of Forensic Dental Sciences*. 2011;3(2):58-62
8. Hoggan BR, Sadowsky C. The use of palatal rugae for the assessment of antero-posterior tooth movements. *Am J Orthod Dentofacial Orthop* 2001;119(5):482-488
9. Kapali S, Townsend G, Richards L, Parish T. Palatal rugae patterns in Australian aborigines and Caucasians. *Aust Dent J* 1997;42(2):129–33
10. Thomas CJ, Kotze TJ. The palatal rugae pattern: A new classification. *J Dent. Assoc. S Afr* 1983; 38: 153-76.
11. Indira AP, Manish Gupta, Maria Priscilla David: Rugoscopy for Establishing Individuality. *Indian Journal of Dental Advancements*. IJDA, 3(1), January-March, 2011 427 – 432.
12. Fahmi. F. M, Al-Shamrani. S. M, Talic. Y. F.: Rugae pattern in a Saudi population sample of males and females. *Saudi Dental Journal*, Vol. 13, No. 2, May - August 2001. 92-5.
13. Indira AP, Manish Gupta, Maria Priscilla David: Rugoscopy for Establishing Individuality. *Indian Journal of Dental Advancements*. IJDA, 3(1), January-March, 2011 427 – 432
14. Nayak P, Acharya A. B. , Padmini A. T. , Kaveri H. “Differences in the palatal rugae shape in two populations of India”. *Archives of Oral Biology*. 2007;52: 977-982
15. Shetty S.K. Kalia S. Patil K Mahima VG. Palatal rugae pattern in Mysorean and Tibetan populations *Indian J Dent Res* 2005; 16:51-5.
16. Sandeep. Goyal, Sonia. Goyal. Study of palatal rugae pattern of rwandan patients attending the dental department at king faisal hospital, kigali, rwanda: a preliminary study. *Rwanda Medical Journal* 2013; 70 (1):19-25.