



ISSN: 2319-6505

Available Online at <http://journalijcar.org>

International Journal of Current Advanced Research
Vol 5, Issue8, pp 1143-1145, August 2016

**International Journal
of Current Advanced
Research**

ISSN: 2319 - 6475

CASE REPORT

CESAREAN SCAR ENDOMETRIOSIS -- A CASE REPORT

Seema Nagger*, KalpanaGoyal., IrbinderKaur., ArunSaxena and Rajkumar Gupta

Medical and Health Sciences, SGT University, Haryana (Gurgaon)

ARTICLE INFO

Article History:

Received 8th May, 2016
Received in revised form 28th June, 2016
Accepted 15th July, 2016
Published online 24th August, 2016

Key words:

Abdominal Wall, Painful Scar, Menstruation,
Scars Endometriosis

ABSTRACT

Endometriosis is described as the presence of functioning endometrial tissue outside the uterine cavity. Scar endometriosis is a rare disease, and is difficult to diagnose. The symptoms are non-specific, typically involving abdominal wall, common complaint is pain at the incision site at the time of menstruation. It commonly follows obstetrical and gynaecological surgeries. The diagnosis is frequently made only after excision of the diseased tissue. We present here a case of abdominal wall scar endometriosis in a 45-year woman who had undergone a caesarean section two years ago. Surgical excision led to the diagnosis of scar endometriosis. The pathogenesis, diagnosis and treatment of this rare condition are discussed.

© Copy Right, Research Alert, 2016, Academic Journals. All rights reserved.

INTRODUCTION

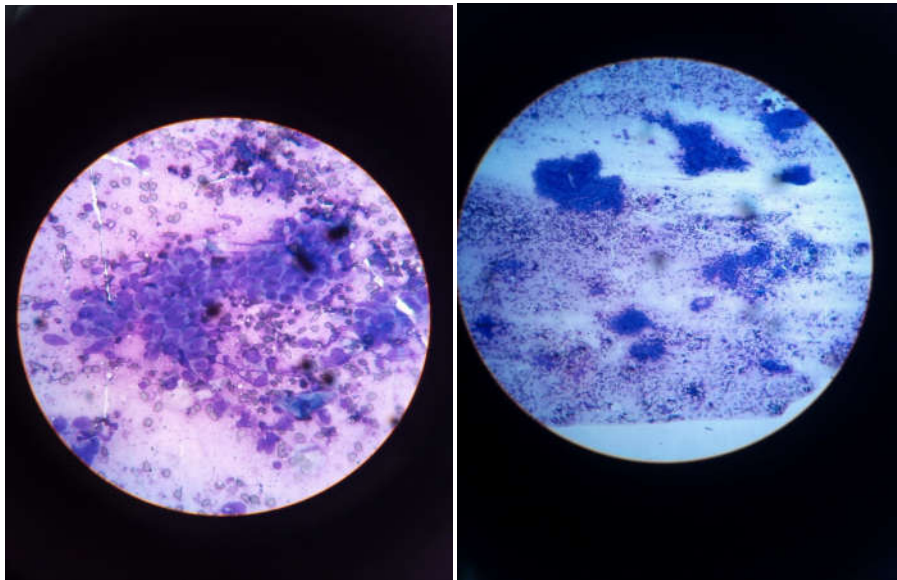
Scar endometriosis first described by Rokitansky in 1860, Endometriosis is admitted as the presence of endometrial like stroma and glands outside the uterine endometrial area [1]. It generally occurs in the pelvic sites such as the ovaries, posterior cul-de-sac, uterine ligaments, pelvic peritoneum, bowel, and rectovaginal septum. Extrapelvic endometriosis can be found in unusual places like in the nervous system, thorax, urinary tract, gastrointestinal tract, and in cutaneous tissues unless its most frequent location is the abdominal wall [2]. Majority of the scar endometriosis have been reported after obstetrical or gynecological procedures such as caesarean section, hysterotomy, hysterectomy, episiotomy, and tubal ligations. The incidence of scar endometriosis has been estimated to be only 0.03% to 0.15% of all cases of endometriosis [3]. Endometriosis, in patients with scars, is more common in the abdominal skin and subcutaneous tissue. There are various theories concerning the scar endometriosis. One of them is the direct implantation of the endometrial tissue in scars during the operation [4]. Under proper hormonal stimulus, these cells may proliferate (cellular transport theory) or the neighborhood tissue may undergo metaplasia, which leads to scar endometriosis (coelomic metaplasia theory). By lymphatic or vascular pathways, the endometrial tissue may reach the surgical scar and then generate to scar endometriosis.

DISCUSSION

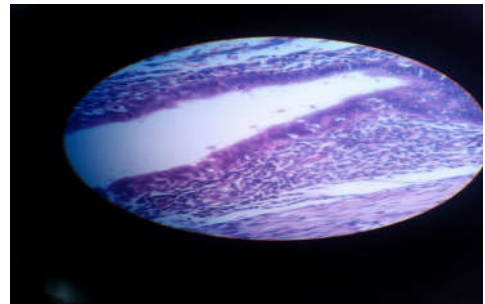
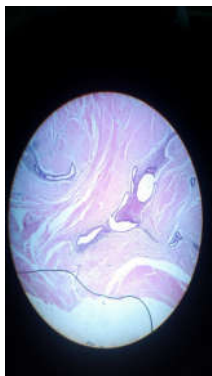
Scar endometriosis usually follows previous abdominal surgery, especially early hysterotomy and cesarean section. Minaglia et al. who analyzed 30 years of incisional endometriosis after caesarean section found the incidence of scar endometriosis to be 0.08% [5]. The reported incidence after midtrimester abortion is about 1% also after cesarean sections ranging from 0.03% to 0.45% [6]. Direct mechanical implantation seems to be the most plausible theory for

explaining scar endometriosis. During caesarean section, endometrial tissue might be seeded into the wound, and under the same hormonal influences these cells proliferate [7]. The endometrial tissue may have certain abilities that make implantation and transplantation during pregnancy. The reason for higher incidence after hysterotomy has been given as the early decidua has more pluripotential capabilities and can result in cellular replication. Many theories as to the cause of scar endometriosis have been postulated; however, the most generally accepted theory is the iatrogenic transplantation of endometrial implants to the wound edge during an abdominal or pelvic surgery [8]. Time interval between operation and presentation has varied from 3 months to 10 years in different series (Sax *et al.*, 1996) [9]. The diagnosis of scar endometriosis may be challenging. Cyclical changes in the intensity of pain and size of the endometrial implants during menstruation are usually characteristic of classical endometriosis. Patients usually complain of tenderness to palpation and a raised, unsightly hypertrophic scar. A high index of suspicion is recommended when a woman is presented with a post-operative abdominal lump. Good history taking and thorough examination with appropriate imaging techniques (ultrasound, CT or MRI) usually lead to the correct diagnosis. When a proper pre-diagnosis cannot be achieved, scar endometriosis can be easily mixed with other surgical conditions like hematoma, neuroma, hernia, granuloma, abscess, scar tissue, neoplastic tissue, or even metastatic carcinoma [10], which are a simple excuse to refer the patient to the general surgeon. Often, the diagnosis of endometriosis is not suggested until after histology has been performed. Correct preoperative diagnosis is achieved in 20% to 50% of these patients [11].

Ultrasonography is the best and most commonly used investigational procedure for abdominal masses, given its practicality and lower cost. The mass may appear hypoechoic and heterogeneous mass with messy internal echoes.



FNAC from abdominal wall swelling shows glandular epithelium and stroma



Gross - 3 cm x 3 cm x 2 cm, grey white irregular mass. H&E showed endometrial glands scattered in stromal tissue and haemorrhagic

On computed tomography, the endometrioma may appear as a circumscribed solid or mixed mass, enhanced by contrast, and show hemorrhages. Kinkel et al. revealed the sensitivity and specificity of MRI in diagnosing endometriomas to be 90%–92% and 91%–98%, respectively [12]. MRI is also a useful modality for presurgical mapping of deep pelvic endometriosis. Infiltration of abdominal wall and subcutaneous tissues is much better assessed by MRI [13]. Tomographic scans and magnetic resonance imaging are more useful in demonstrating incisional hernias and differential diagnosis [14]. Fine-needle aspiration cytology (FNAC) was reported in some studies for confirming the diagnosis [15]. However, FNAC cytology is a liable method to make the diagnosis of scars, and surgeons must be aware of some diagnosis such as inguinal hernia and reimplantation of potential malignancies during process. Our opinion of FNAC is accurate only in cases of large masses, doubtful diagnosis, and atypical clinical presentations. Management includes both surgical excision and hormonal suppression (Wolf and Singh, 1989; Schoelefield et al., 2002) [16]. Hormonal suppression with the use of Medical therapy with danazol, progesterone, and GnRH produces only partial recovery, and mostly recurrence occurs after cessation of the treatment with extreme side effects [17]. Medical treatment is not very much effective and gives only partial relief in symptoms and does not ablate the lesion. The treatment of choice is always total Local wide excision, with at least a 1 cm margin, is accurate

Recurrence of scar endometriosis seldom happens with only a few cases reported. Which is diagnostic and therapeutic at the same time. Follow up of endometriosis patients is important because of the chances of recurrence, which may require re excision. In cases of continual recurrence, possibility of malignancy should be ruled out.

Hence, good technique and proper care during cesarean section may help in preventing scar endometriosis.

References

1. B. Nahir, T. Eldar-Geva, J. Alberton, and U. Beller, "Symptomatic diaphragmatic endometriosis ten years after total abdominal hysterectomy," *Obstetrics and gynecology*, vol. 104, no. 5, pp. 1149–1151, 2004.
2. K. J. Jubanyik and F. Committee, "Extrapelvic endometriosis.," *Obstetrics and Gynecology Clinics of North America*, vol. 24, no 2, pp. 411–440, 1997
3. (Francica et al., 2003; Kaloo et al., 2002). Francica G et al., (2003). Abdominal wall endometriosis near cesarean delivery scars. *Journal of Ultrasound in Medicine* 22 1041–7
4. W. D. Steck and E. B. Helwig, "Cutaneous endometriosis," *Clinical Obstetrics and Gynecology*, vol. 9, no. 2, pp. 373–383, 1966
5. S. Minaglia, D. R. Mishell, and C. A. Ballard, "Incisional endometriomas after cesarean section: a case series," *Journal of Reproductive Medicine for the*

- Obstetrician and Gynecologist*, vol.52, no. 7, pp. 630–634, 2007
6. Y. Wolf, R. Haddad, N. Werbin, Y. Skornick, and O. Kaplan, "Endometriosis in abdominal scars: a diagnostic pitfall," *American Surgeon*, vol. 62, no. 12, pp. 1042–1044, 1996
 7. M. Gunes, F. Kayikcioglu, E. Ozturkoglu, and A. Haberal, "Incisional endometriosis after cesarean section, episiotomy and other gynecologic procedures," *Journal of Obstetrics and Gynaecology Research*, vol. 31, no. 5, pp. 471–475, 2005.
 8. Francica *et al.*, 2003; Kaloet *et al.*, 2002; Tanos and Anteby, 1994; Douglas and Rotimi 2004).
 9. Sax HC *et al.*, (1996). Extrapelvic endometriosis: Diagnosis and treatment. *The American Journal of Surgery* 171 239-241.
 10. R. G. Blanco, V. S. Parithivel, A. K. Shah, M. A. Gumbs, M. Schein, and P. H. Gerst, "Abdominal wall endometriomas," *The American Journal of Surgery*, vol. 185, no. 6, pp. 596–598, 2003.
 11. A. S. Sevdal, S. J. Sickel, E.D. Warner, and H. C. Sax, "Extrapelvic endometriosis: diagnosis and treatment," *The American Journal of Surgery*, vol. 177, no. 2, pp. 243–246, 1993.
 12. K. Kinkel, K. A. Frei, C. Balleyguier, and C. Chapron, "Diagnosis of endometriosis with imaging: a review," *European Radiology*, vol. 16, no. 2, pp. 285–298, 2006.
 13. C. Balleyguier, C. Chapron, N. Chopin, O. H'el'eron, and Y. Menu, "Abdominal wall and surgical scar endometriosis: results of magnetic resonance imaging," *Gynecologic and Obstetric Investigation*, vol. 55, no. 4, pp. 220–224, 2003.
 14. C. Y. Yu, M. Perez-Reyes, J. J. Brown, and J. A. Borrello, "MR appearance of umbilical endometriosis," *Journal of Computer Assisted Tomography*, vol. 18, no. 2, pp. 269–271, 1994.
 15. S. K. Pathan, K. Kapila, B. E. Haji *et al.*, "Cytomorphological spectrum in scar endometriosis: a study of eight cases," *Cytopathology*, vol. 16, no. 2, pp. 94–99, 2005.
 16. Wolf G and Singh K (1989). Cesarean scar endometriosis: A review. *Obstetrical & Gynecological Survey* 44 89–95.
 17. M. E. Rivlin, S. K. Das, R. B. Patel, and G. R. Meeks, "Leuprolide acetate in the management of cesarean scar endometriosis," *Obstetrics and Gynecology*, vol. 85, no. 5, pp. 838–839, 1995.
