



Research Article

**RETINOPATHY OF PREMATURETY: INCIDENCE AND RISK FACTORS:
A HOSPITAL BASED STUDY**

**Ankur Gupta¹, Vidya Sukumar², Zaheer M³, Santosh Pandurang Kait⁴
and Jayachandran A.K⁵**

¹Specialist in Neonatology, Aster Medcity, Kochi, Kerala

²Senior Resident in Department of Pediatrics, Sree Narayana Institute of Medical Sciences,
Chalakkal, Kochi, Kerala

³Specialist in Pediatrics and Neonatology, Malabar hospital, Manjeri, Kerala

⁴Specialist in Pediatrics and Neonatology Sahayadri hospital, Pune, Maharashtra

⁵Chief consultant, Neobless, Moulana Hospital, Perinthalamanna, Malappuram-Dist, Kerala

ARTICLE INFO

Article History:

Received 06th May, 2019

Received in revised form 14th June, 2019

Accepted 23rd July, 2019

Published online 28th August, 2019

Key words:

Retinopathy of Prematurity, Oxygen therapy,
Sepsis, Blood transfusion.

ABSTRACT

Background: Survival rate of preterm neonates have reported to be higher compare to previous due to recent advancement in neonatal care with subsequent increase in the number of babies affected by retinopathy of prematurity (ROP). This study evaluates the incidence of ROP and estimates associated potential risk factors.

Methods: Prospective study on infants fulfilling the screening criteria admitted to Neobless between November 2017 to April 2018. Aim: To evaluate the risk factors predisposing to severity of retinopathy of prematurity (ROP) in a level III neonatal unit. ROP screening was done by experts from Aravind Eye Hospital, Coimbatore, Kerala using RETCAM. Treatment was offered for Type I ROP and aggressive posterior retinopathy of prematurity (AP-ROP) with intravitreal Injection Bevacizumab (Avastin) and LASER.

Results: Out of that 91 babies, who fulfilled the screening criteria, were included in the study. Out of 91 infants screened 9 (9.8%) were diagnosed as Severe ROP and required treatment, the remaining 82 babies (90.2%) did not require treatment (Non ROP group). Out of the 9 cases with Severe ROP, 8 were treated with intravitreal injection of Bevacizumab (Avastin) and only one case required Laser treatment. All of them had good outcome on subsequent follow ups.

Conclusions: There was found to be significant association between duration of oxygen therapy (p value <0.001), sepsis (p value <0.001) and blood transfusions(p value 0.001) with Severity of ROP.

Copyright©2019 Ankur Gupta et al. This is an open access article distributed under the Creative Commons Attribution License, which permits unrestricted use, distribution, and reproduction in any medium, provided the original work is properly cited.

INTRODUCTION

Retinopathy of prematurity (ROP) is a vasoproliferative disorder that affects premature infants. The World Health Organization's "VISION 2020" programme has identified ROP as an important cause of blindness in both high and middle income countries.¹ WHO estimates that there are 15 million preterm births (<37 weeks) in a year and India has the largest number of preterm births in the world.² The reported incidence of ROP in the Western world ranges from 21% to 65.8%, in India it ranges from 38% to 51.9% among low birth weight babies. Approximately 2 million babies out of 26 million annual live births in India are born with birth weight <2000 g and are at risk of developing ROP.³

Aim

To evaluate the incidence of retinopathy of prematurity (ROP), identification of prenatal and postnatal risk factors which predispose for development of ROP, and to assess the treatment outcomes in newborns.

Type of study

Prospective study on infants fulfilling the screening criteria admitted to Neobless NICU, Moulana Hospital, Perinthalamanna, Kerala between November 2017 to April 2018.

MATERIALS & METHODS

Babies admitted to Neobless who met the following criteria for ROP screening, according to Neobless guidelines for screening, were included in the study: (a) ≤34 weeks of gestation, (b) ≤1800 g of birth weight, (c) Babies >1800g or

*Corresponding author: **Ankur Gupta**

Specialist in Neonatology, Aster Medcity, Kochi, Kerala

born after 34 weeks with unstable clinical course requiring cardio respiratory support.

ROP was graded into stages and Zones as per International Classification of ROP (ICROP). Type I ROP or Threshold ROP, is defined as Zone 1 any stage ROP with plus disease Zone 1 stage 3 ROP without plus disease and zone II stage 2 or 3 ROP with plus disease.⁴

Aggressive Posterior ROP (APROP) is defined as severe plus disease, flat neovascularization in Zone I or Posterior Zone II, intra-retinal shunting, hemorrhages and rapid progression to retinal detachment. Type I ROP and APROP have been grouped into Severe ROP Group, who required treatment for ROP. Type 2 ROP or pre-threshold ROP is defined as zone 1 stage 1 or 2 ROP without plus disease and zone II stage 3 ROP without plus disease. ROP screening was done by experts from Aravind Eye Hospital, Coimbatore using RETCAM. Treatment was offered for Type I ROP and APROP with intravitreal Injection Bevacizumab (Avastin) and LASER.

RESULTS

Total number of admissions in our NICU during the 6 month period was 698, out of that 91 babies, who fulfilled the screening criteria, were included in the study. The average weight of the babies requiring ROP screening was 1.589 Kg and the average gestation was 32.6 weeks. Out of the 91 babies screened 36 (39.5%) were males and 55 (60.5%) were females. Out of 91 infants screened 9 (9.8%) were diagnosed as Severe ROP and required treatment, the remaining 82 babies (90.2%) did not require treatment (Non ROP group). Surfactant administration was required in 66.67% babies who were in Severe ROP group for treatment of Respiratory distress syndrome owing to their prematurity. In comparison only 13.41% required surfactant therapy in Non ROP group. Details are given in table:1, figure1 and 2.

Table 1

	Severe ROP Group	Non ROP Group	P - Value
Gestational Age (weeks)	29.03 ± 1.91	32.99 ± 2.05	0.05
Birth Weight	1.14 ± 0.2	1.64 ± 0.39	0.009
Nasal Prong O2	206.67 ± 203.36	43.35 ± 37.3	< 0.001
Ventilator	37.89 ± 42.83	5.99 ± 21.84	0.008
CPAP	65.56 ± 38.6	16.66 ± 20.79	0.007
Sepsis	5 (55.56%)	11 (13.41%)	<0.001
Blood Transfusions	7 (77.78%)	5 (6.17%)	< 0.001

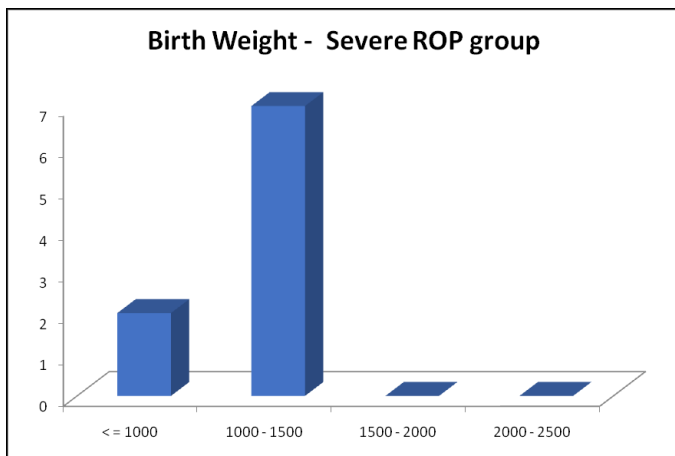


Figure 1

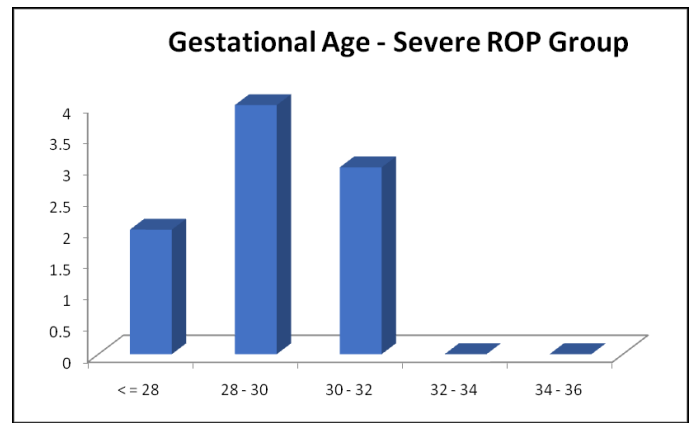


Figure 2

Out of the 9 cases with Severe ROP, 8 were treated with intravitreal injection of Bevacizumab (Avastin) and only one case required Laser treatment. All of them had good outcome on subsequent follow ups.

DISCUSSION

Incidence of Severe ROP was 9.8% in our study. Incidences of ROP in various studies in India have been reported to be 51% from Delhi (79 patients), 47% in a study from Chandigarh (165 patients), 44% from north east (50 patients), 38% from Chennai (50 patients), 22% from Bangalore (7106 images), 22.3% from Pune (552 infants) and 11.8% from AIIMS, Delhi (704 patients).⁵⁻¹¹ All treated cases had good outcome and no case had visual impairment on follow up. Those Severe ROP Group that required treatment had smaller gestation age (average 29 weeks) and lower birth weight (average 1.142 kg). There was found to be significant association between duration of oxygen therapy (p value <0.001), sepsis (p value <0.001) and blood transfusions (p value < 0.001) with Severe ROP.

CONCLUSION

Significant association was documented between duration of oxygen therapy (p value < 0.001), sepsis (p value <0.001) and blood transfusions (p value < 0.001) with Severity of ROP. Better oxygen control, judicious use of blood transfusions and sepsis prevention remain the most important strategies in prevention of ROP and its complications.

References

1. Pejaver R, Vinekar A, Bilagi A, National Neonatology Foundation's Evidence -based Clinical Practice Guidelines (2010), Retinopathy of Prematurity, New Delhi: NNF India; 2010 p253-62.
2. Howson CP, Kinney MV, Lawn JE, editors .March of Dimes, PMNCH, Save the Children, WHO. Born Too Soon: The global action report on preterm birth, Geneva: World Health Organization: 2012.
3. Gilbert C, Foster A. Childhood blindness in the context of "VISION 2020"-The right to sight. Bull World Health Organization 2001; 79:227-32.
4. Wheatley CM, Dickenson JL, Mackey DA, Craig JE, Sale MM, Retinopathy of Prematurity: Recent advances in our understanding. *Br J Ophthalmol* 2002 ; 86: 696-700
5. Charan R, Dogra MR, Gupta A, Narang A. The incidence of retinopathy of prematurity in a neonatal care unit. *Indian J Ophthalmol*. 1995; 43:123-6.

6. Gopal L, Sharma T, Ramchandran S, Shanmugasundaram R, Asha V. Retinopathy of prematurity. *Indian J Ophthalmol.* 1995; 43:50-61.
7. Varughese S, Jain S, Gupta N, Singh S, Tyagi V, Puliye JM. Magnitude of the problem of retinopathy of prematurity experience in a large maternity unit with a medium size level-3 nursery. *Indian J Ophthalmol.* 2001;49:187-8.
8. Chattopadhyay MP, Pradhan A, Singh R, Datta S. Incidence and risk factors for retinopathy of prematurity in neonates. *Indian Pediatr.* 2015;52(2):157-8.
9. Vinekar A, Gilbert C, Dogra M, Kurian M, Shainesh G, Shetty B. The kidrop model of combining strategies for providing retinopathy of prematurity screening in underserved areas in India using widefield imaging, tele-medicine, non-physician graders and smart phone reporting. *Indian J Ophthalmol.* 2014; 62(1):41-9.
10. Chaudhari S, Patwardhan V, Vaidya U, Kadam S, Kamat A. Retinopathy of prematurity in a tertiary care center, risk factors and outcome. *Indian Pediatr.* 2009;46:219-24.
11. Kumar P, Sankar MJ, Deorari A, Azad R, Chandra P, Agarwal R, *et al.* Risk factors for severe retinopathy of prematurity in preterm low birth weight neonates. *Indian J Pediatr.* 2011; 78:812 -6.

How to cite this article:

Ankur Gupta *et al* (2019) 'Retinopathy of Prematurity: Incidence and Risk Factors: A Hospital Based Study', *International Journal of Current Advanced Research*, 08(08), pp. 19578-19580. DOI: <http://dx.doi.org/10.24327/ijcar.2019.19580.3787>
