



Research Article

## CLINICAL PATTERN AND ANTIFUNGAL SUSCEPTIBILITY OF CRYPTOCOCCUS NEOFORMANS FROM CRYPTOCOCCAL MENINGITIS PATIENTS IN NORTHERN INDIA

Pushpa Yadav<sup>1</sup>, Manodeep Sen\*<sup>2</sup>, Anupam Das<sup>3</sup>, Janmejai Kumar Srivastava<sup>4</sup>, Ajai Kumar Singh<sup>5</sup>, Pradeep Kumar Maurya<sup>6</sup>, Poonam Chaturvedi<sup>7</sup>, Hardeep Singh Malhotra<sup>8</sup>, Gaurav Raj Agrawal<sup>9</sup> and Tanushri Chaterji<sup>10</sup>

<sup>1,2,3</sup>Department of Microbiology Dr. Ram Manohar Lohia Institute of Medical Sciences Vibhuti Khand, Gomti Nagar Lucknow, 226010, India

<sup>4</sup>Amity University Uttar Pradesh, Lucknow Campus, Malhour, GomtiNagar Extension Lucknow-227105, India

<sup>5,6,7</sup>Dept. of Neurology Dr. Ram Manohar Lohia Institute of Medical Sciences Vibhuti Khand, Gomti Nagar Lucknow, 226010, India

<sup>8</sup>Dept. of Neurology King George's Medical University, Lucknow, India

<sup>9</sup>Dept. of Radiodiagnosis Dr. Ram Manohar Lohia Institute of Medical Sciences Vibhuti Khand, Gomti Nagar Lucknow, 226010, India

<sup>10</sup>Dept. of Microbiology, Babu Banarsi Das College of Dental Sciences Babu Banarsi Das University, Lucknow-226028, India

### ARTICLE INFO

#### Article History:

Received 12<sup>th</sup> May, 2019

Received in revised form 23<sup>rd</sup> June, 2019

Accepted 7<sup>th</sup> July, 2019

Published online 28<sup>th</sup> August, 2019

#### Key words:

Cryptococcal meningitis, Human Immunodeficiency Virus, Cryptococcal Latex Agglutination Test, Automated Yeast System, Antifungal Sensitivity.

### ABSTRACT

**Background:-** Cryptococcal meningitis (CM) is recognized as a disease of the immunocompromised or HIV patients. Early diagnosis and treatment is the key to reducing morbidity and mortality associated with CM.

**Method:** - CSF from all cases of Cryptococcal meningitis were tested for positive India ink, Cryptococcal Antigen Latex Agglutination test, followed by fungal culture and Urease Biochemical test. For Pathological examination, CSF cell count, Biochemical Analysis and corresponding blood sugar level were recorded.

These isolates were further subjected to an automated yeast identification and susceptibility system- VITEK 2-Compact™ (Biomérieux, India) and observe antifungal sensitivity pattern for Amphotericin B, Fluconazole and Voriconazole based on Clinical and Laboratory Standards Institute (CLSI) guidelines.

**Result:** - In two years of study, there were 31 cases of Cryptococcal meningitis including 10 cases with HIV co-infection. The most common (in all 31 patients) complaint was fever and headache. In all, 31 cases India ink and CALAS test results were positive in 100%, but 58.06% (18/31) were culture positive. Out of 31, 18 isolates were culture positive for *Cryptococcus neoformans*; which were 100% sensitive to Amphotericin B and Fluconazole. 38.8% (7/18) were resistant to Voriconazole.

**Conclusion:** - In present study, headache and fever were the commonest manifestation. Antifungal testing is more helpful to document the emergence of resistance.

Copyright©2019 Pushpa Yadav et al. This is an open access article distributed under the Creative Commons Attribution License, which permits unrestricted use, distribution, and reproduction in any medium, provided the original work is properly cited.

### INTRODUCTION

*Cryptococcus neoformans* var. *neoformans* is an opportunistic fungal pathogen that causes cryptococcal meningitis, which is mostly in HIV-infected and immunocompromised/immunocompetent patients.<sup>1</sup> The incidence of Cryptococcal meningitis increase is attributed to an enlarging population of high risk immunosuppressed patients, which is due in part to more successful pharmacological immunosuppression and chemotherapies and the frequent use of antibacterial and antiviral therapies. In addition seemingly immunocompetent individuals can acquire this CNS infection with fungi such as *Cryptococcus neoformans* being the commonest.<sup>2</sup> In Human Immunodeficiency virus (HIV) infected patients Cryptococcal meningitis is a leading cause of death.

\*Corresponding author: Manodeep Sen

Department of Microbiology Dr. Ram Manohar Lohia Institute of Medical Sciences Vibhuti Khand, Gomti Nagar Lucknow, 226010, India

CSF fungal burden, altered mental status and rate of clearance of infection predict acute mortality in HIV-associated cryptococcal meningitis.<sup>3</sup> In 2017, the incidence of cryptococcal meningitis (CM) in the developed world has declined with widespread, early antiretroviral therapy (ART) but cryptococcal disease remains a major opportunistic infection and leading cause of mortality in patients infected with HIV in much of the developing world.

The global annual burden of CM is estimated at 957,900 cases resulting in an estimated 624,700 deaths within 3 months of cryptococcal infection. [1] Even with ART availability, CM-related mortality remains high (20%-30%).<sup>4</sup>

Among AIDS patients, the rate of infection ranges from 23% to 48.6%, and approximately 70% to 90% of cryptococcal patients have signs and symptoms of subacute meningitis or meningoencephalitis with high mortality rates.<sup>5</sup> The mortality rate may be high as 30%, particularly with delay of Diagnosis

and definitive treatment.<sup>6</sup> Cryptococcal meningitis is treated in three phases: Induction, Consolidation and Maintenance. Combination Antifungal therapy treatment is induction. Liposomal Amphotericin B and flucytosine is preferred because of improved survival with this regimen.

#### Alternative induction regimen is

1. Amphotericin B lipid complex 5 mg/kg IV q 24 h + flucytosine 25 mg/kg PO q 6 h
2. Amphotericin B (liposomal or deoxycholate, dosed as above) + fluconazole 800 mg PO or IV q 24 h  
Amphotericin B (liposomal or deoxycholate, dosed as above) monotherapy
3. Fluconazole (400 mg or 800 mg PO or IV q 24 h) + flucytosine 25 mg/kg PO q 6 h
4. Fluconazole 1200 mg PO or IV daily monotherapy

Induction therapy should be continued for 2 weeks, but increased to 4 weeks in the case of Amphotericin B monotherapy. Many experts obtained a CSF fungal culture at the end of induction to document clearance of viable organisms, continuing induction therapy until the cultures have cleared. In Consolidation therapy, Patients take Fluconazole 400 mg by oral or intravenous (IV) daily for 8 weeks. At least 1 year of maintenance therapy with fluconazole 200 mg daily is recommended.<sup>7</sup> With the advent of Antiretroviral therapy (ART), Acquired Immunodeficiency Syndrome (AIDS) related cryptococcal infection has been declining. Similar regime can be used in immunocompetent individuals though standard therapy recommended is to extend the intensive phase to 6-10 weeks followed by consolidation with Fluconazole. Treatment of cryptococcal meningitis in immunocompromised individuals consist of Amphotericin B 0.7 mg/kg/day along with Flucytosine 100mg/kg/day for 2 weeks followed by consolidation with fluconazole 400 mg /day for 10 weeks.<sup>8,9</sup>

The treatment of cryptococcal meningitis is intravenous amphotericin B in combination with oral flucytosine for a minimum of 2 weeks, followed by oral fluconazole for at least 8 weeks. Liposomal amphotericin B is associated with lower risks of renal toxic effects and other side-effects than conventional amphotericin B and has similar efficacy, but it is more expensive. Combined flucytosine with amphotericin B leads to faster and greater sterilisation of CSF than does amphotericin B alone.<sup>9</sup>

In Now-a-days several recent innovations in the diagnosis and radiological investigations, has resulted in improved management of Cryptococcal meningitis, there by leading to improve care of patients. These new investigations, provide an update in the field of cryptococcal diagnosis and management.<sup>10,11</sup>

A prospective study was conducted at our institute with the purpose of analyzing clinical and laboratory manifestations of Cryptococcal meningitis in HIV/ Immunocompromised/ Immunocompetent patients and to better understand the antifungal treatment.

In the developing countries, introduction of retroviral therapy has reduced morbidity and mortality in all cryptococcal meningitis patients.

## METHODS

### Case definition and sample collection

The present study was conducted between June 2016 to June 2018 in Department of Microbiology, Dr. Ram Manohar Lohia Institute of Medical Sciences, Lucknow, India. In the present study 71 subjects were enrolled for the study and were classified into cases (n=31) and control (n=40). Cases comprised of Cryptococcal meningitis and control group includes (non infectious neurological disorders like Dementia, Post polio syndrome, Multiple sclerosis etc.) Cryptococcal meningitis was defined on the basis of clinic-radiological / pathological and/or microbiological evidence. Further, defining Cryptococcal meningitis- the following criteria were considered which included common clinical picture compatible with evidence of fever, headache, meningismus or altered mental status, with a cerebrospinal fluid (CSF), and who were those with a cryptococcal antigen (CALAS; cryptococcal latex agglutination system) titer of  $\geq 1:8$  and/or positive India Ink preparation for capsulated yeast cells and/or a positive CSF culture yielding *Cryptococcus neoformans*.<sup>12</sup>

These isolates were further subjected to an automated yeast identification and susceptibility system- VITEK 2 Compact™ (Biomerieux, India) and observe antifungal sensitivity pattern for Amphotericin B, Fluconazole, Voriconazole, Flucytosine based on Clinical and Laboratory Standards Institute (CLSI) guidelines. Radiological evidence of cryptococcal meningitis was based on imaging which considers exudates in basal cisterns or in sylvian fissure, hydrocephalus, infarcts (basal ganglionic), gyral enhancement, parenchymal mass in the form of cryptococcoma.<sup>8</sup> Exclusion criteria was age <18 yrs, pregnant women, patient with end stage organ damage, patient who refused for the consent.

Before collection of CSF samples, the informed consent from subjects as cryptococcal meningitis and controls were obtained. CSF samples were collected under aseptic conditions by lumbar puncture involving minimum or no risk to patients. Further follow-up, standard history-taking examination and basic investigations (including radiological investigations, wherever required) were carried out for all subjects under investigation.

### Sample processing /Investigations

**Microbiological Investigations:** The CSF samples were microbiologically analysed for wet mount examination, Gram and India ink staining (Fig.1), Cryptococcal Latex Agglutination Test (LAT) was performed with CALAS (Bio-Rad, Pastorex™Crypto plus) (Fig.2).

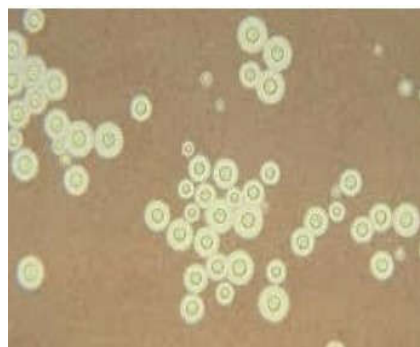

Fig 1 India ink preparation showing encapsulated budding yeast cells of *C. neoformans*. Narrow based budding yeast cells variable sized measuring in 5-25 $\mu$ .



Fig 2 Cryptococcal latex Agglutination Test (Biorad Kit)

CSF culture was performed on Sabouraud Dextrose Agar (SDA) and Bird Seed Agar (BSA) and incubated at 25<sup>0</sup>C & 37<sup>0</sup>C for 48-72 hrs. (Fig. 3)

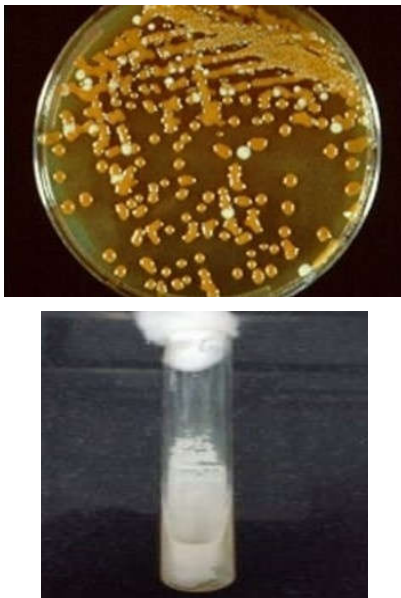

Fig 3 Brown colour colonies on Bird Seed Agar Creamy white colour colonies on Sabouraud Dextrose Agar

Further positive culture isolates were identified and their antifungal susceptibility testing was performed by standard/automated techniques (Vitek 2YST ID- Ref. 21343 and Vitek 2 AST- YS08 Ref. 420739 ) (Fig. 4).



Fig 4 Automated yeast identification and susceptibility system- VITEK 2 Compact™ (Biomérieux, India)

On the other hand, 31 cases of Cryptococcal meningitis were also tested for HIV antigen/antibodies (as per the NACO HIV testing guidelines).

**Pathological Investigations:** Cytological & Biochemical evaluation of the CSF sample was done as per routine standard protocol tested for CSF Cell count, CSF blood sugar and CSF protein level. The blood collected in Sodium Fluoride vial were tested for corresponding blood glucose level.

**Statistical analysis**

Clinical data were analyzed using Statistical package for Social Sciences (ver 16.0). The percentage occurrence of clinical symptoms is expressed along with the total number of patients (n) for whom a particular symptoms was observed. The clinical data comprising Clinical signs and symptoms, microbiological analysis and biochemical investigations were calculated to compare the data for their statistical significance. Statistical significance was defined when  $P < 0.05$ .

**RESULTS**

**Clinical Presentation**

During the study period total 71 patients were enrolled which were further categorized in Cryptococcal meningitis cases (n=31) including 11 cases with HIV co-infection. Majority of cases were aged between 31 to 45yrs (n=11, 35.5%). With increasing age, a decrease in the number of patients suffering from meningitis was observed and presented in Table.1.

Table 1 Gender Wise Distributions

S.No.	Gender	Cases		Controls	
		No.	%	No.	%
1	Male	24	77.4	14	35
2	Female	7	22.6	26	65

Cryptococcal meningitis cases (n=31) included 11 cases with HIV co-infection. Male (77.4%) were prominent in female (22.6%) gender. Mean & SD of CSF sugar 47.83±36.81 mg/dl and random blood sugar was 117.73±34.60 mg/dl was calculated in all cases.

On the basis of clinical signs and symptoms, presence of fever and headache was found to be significant ( $p < 0.005$ ) and other symptoms was taken into consideration for the statistical analyses, but no statistical significance was observed, as compared to the control group shown in Table. 2.



**Table 2** Clinical Sign and symptoms

Characteristic	Cases (n=31)		Controls (n=40)	
	No.	%	No.	%
Fever	29	93.5	27	67.5
Headache	25	80.6	17	42.5
Convulsions-generalised	1	3.2	4	10.0
Convulsions-focal	2	6.5	2	5.0
Nausea/vomiting	20	64.5	24	60.0
Altered sensorium	14	45.2	10	25.0
Abnormal movement	3	9.7	3	7.5
Signs of meningeal irritation	0	0	3	7.5
Evidence of source of infection	1	35.5	38	95
Sensitivity of light	1	3.2	0	0
Stiff neck	0	0	3	7.5
<b>CSF Cell count/cmm</b>		<b>CSF Sugar</b>		
0-5	7	22.6	18	47.4
6-50	8	25.8	12	31.6
50-100	10	32.3	2	5.3
100-500	4	12.9	5	13.2
>500	2	6.5	1	2.6
<b>CSF Protein (mg%)</b>		<b>CSF Protein</b>		
0-8	0	0	2	5.3
9-43	2	6.7	4	10.5
44-200	20	66.7	28	73.7
201-1000	8	26.7	4	10.5
>1000	0	0	0	0

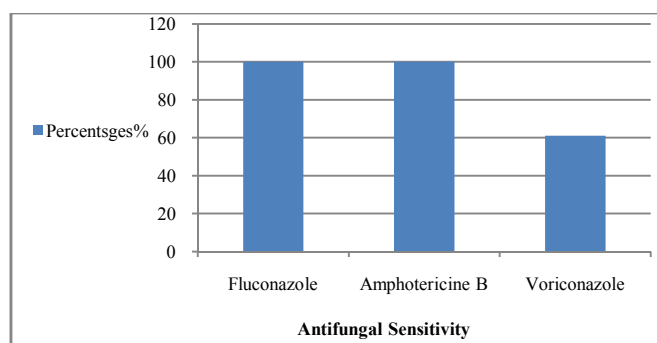
In Biochemical Profiling include CSF cell count, CSF protein and CSF Blood sugar, which resulted significant for CSF cell count only summarized in Table 2. CSF microbiological investigation shown in Table 3.

**Table 3** Microbiological Investigations

S.N.	Feature	Cases (N=31)		Controls (N=40)	
		No.	%	No.	%
1	Wet mount of CSF Pus Cells	25	80.65	8	20
2	Wet mount positivity for CSF organisms	23	74.19	0	0.0
3	CSF India Ink Positivity	31	100	0	0.0
4	Gram Stain positivity for CSF pus Cells	28	90.32	8	20
5	Gram Stain Positivity for CSF organism	14	45.16	0	0.0
6	CSF CALAS Positivity	31	100	0	0.0
7	CSF CALAS Titre				
	1:10	6	19.35	NA	NA
	1:100	11	35.48	NA	NA
	1:1000	14	45.16	NA	NA
8	CSF Fungal Culture Positivity	18	58.06	0	0

All negative culture results were reviewed for relevance with respect to subject's clinical course and treatment and were found to be previously treated with antibiotics &/or antifungals.

Antifungal sensitivity pattern showed that all cases were sensitive to Fluconazole and Amphotericine B (100%) while 61.1% were sensitive to Voriconazole presented in Graph 1.



**Graph 1** The Antifungal sensitivity pattern against, *C. neoformans* is depicted. 100% of (18/18) isolates were sensitive to Fluconazole and Amphotericine B. 61.1% of (11/18) isolates were sensitive to Voriconazole and 38.8% of (7/18) isolates were resistant.

All the 18 patients in our study responded to induction therapy to Amphotericine B (1mg/kg daily) for 2 weeks, followed by Fluconazole 400 mg daily for 2 months. No relapse was observed in any of these patients.

Inhibitory activities of Amphotericine B, Fluconazole and Voriconazole against clinical isolates of *Cryptococcus neoformans* (n=18) from initial Cerebro-spinal fluid culture is shown in Table 4.

**Table 4** MIC % of Antifungal Agents

Antifungal Drug	Percentages % at MIC (µg/ml)						
	0.125	0.25	0.5	1	2	4	8
Fluconazole	0	0	0	0	72.2	27.78	0
Amphotericine B	0	5.5	72.2	22.2	0	0	0
Voriconazole	61.1	0	0	0	0	0	38.8

Out of 11, 9 patients were initially on ART since 3 months and 2 (6.45%) were on ART for >1 year.

Out of the all 31 patients who were suspected in *Cryptococcal meningitis* of follow-up, by the effect of induction therapy, 25 patients survived, 2 expired, and remaining 4 patients were lost to follow up.

## DISCUSSION

In Present study male patients were more than female patients. In a study conducted by Bhargava *et.al.* most common signs and symptoms were headache (90%), fever (85%) and vomiting (60%). In a study conducted by Lakshmi *et.al.*<sup>13</sup> most common signs and symptoms were a headache (92.31%), fever (79.49%). Vasant *et.al.*<sup>14</sup> noted a headache, altered sensorium, and fever in all cases (100%).

[In present study, *Cryptococcal meningitis* cases, 2 were HbsAg positive and one was HCV positive.]

Prasad *et.al.* 2003 at SGPGIMS Lucknow observed that 33 (73.3%) were male while 12 (26.7%) were female. 13 (28.9%) were HIV infected. The presenting symptoms were headache in 39 (89.5%), fever in 34 (78.9%), altered sensorium in 11 (23.7%), neck rigidity in 6 (13.2%), seizure in 4 (10.5%), hydrocephalus in 5 (11.1%) patients.<sup>15</sup>

Chaurasia S. *et.al.* 2017 observed in their study, that out of the 22 cases of *cryptococcal meningitis* which 18 (81.8%) were HIV positive patients. Majority of 14 (77.8%) were male while 4 (22.2%) were female patients. Majority of cases were aged between 16 to 45 yrs (n=17, 94.4%).<sup>16</sup> Our study showed that majority of immunocompromised patients, who had AIDS or HIV infection also suffered from *cryptococcal meningitis*.

In the present study, India ink preparation was positive in all 31 (100%) cases. In a study conducted by Satishchandra *et.al.*, >90% of patients had India ink test positive.<sup>17</sup> A study by Abassi M *et.al.* observed <86% sensitivity of India ink.<sup>11</sup> Chaurasia S *et.al.* in their study found that India ink preparation was positive in 15 (83.3%) out of the 18 cases. All cases (100%) were culture positive for *Cryptococcus neoformans*.<sup>16</sup> Heyderman *et.al.* observed that India ink staining was positive in 76(85.39%) and culture positive for 77 (87%) out of total 89 patients.<sup>18</sup> In the study conducted by Taneja J *et.al.* 2009, 85% of patients had positive India ink staining test<sup>19</sup>, whereas in the study conducted by Kanchan *et.al.* 2012 observed that 90% positivity of CSF india ink among patients with *cryptococcal meningitis*.<sup>20</sup>

The rapid diagnosis of Cryptococcal meningitis depends on detection of *Cryptococcus* spp. in CSF. India ink staining is simple and easy method for the diagnosis of cryptococcal infection but few organisms can be missed. So, we used CALAS test (Cryptococcal Latex Agglutination Test) in CSF which showed 100% result. In previous study (Bhargava *et. al.* 2009) Cryptococcal latex Agglutination test was done on CSF sample and showed 100% result. Kumar *et. al.* observed similar results on CALAS test.<sup>21</sup> Capoor *et. al.* observed in their study that sensitivity of Latex Agglutination Test was 95-100% and culture positive for 80-92% respectively.<sup>22</sup>

In their other study done by Mitchell *et.al.* sensitivity of Cryptococcal antigen detection test and culture positivity was 95% and 75%.<sup>23</sup>

Fungal culture is the gold standard diagnostic test for Cryptococcal meningitis, but it takes time in the duration of 2 to 3 weeks. It is useful to identify species of *C. neoformans* and check their susceptibility to drugs. In present study, fungal culture positivity in CSF was 83.87%. In Prasad *et. al.* 2003 at Sanjay Gandhi Post Graduate Institute of Medical Sciences, Lucknow observed 77.8% fungal culture positivity<sup>15</sup>. A study by Chaurasia S. *et. al.* observed that Cryptococcal antigen Detection test was more sensitive (100%) as compared to fungal culture (81.8%).<sup>16</sup>

False negative test results are unusual and can be due to a prozone effect or immune complexes, or low production of antigen.<sup>24</sup> Cryptococcal Latex Agglutination Test is not 100% accurate, either due to poor sensitivity or chance of false positivity/ negativity etc. False-positive reactions with serum or CSF may be caused by rheumatoid factor<sup>25</sup>, *Trichosporon beigelii* (J.M. Jones *et al.* 1985), *Bacterium DF-2*(*Capnocytophaga canimorsus*)(Petell RJ,*et al.*1987),*Systemic Lupus Erythematosus* (Hay R.J.& D.W.R. Mackenzie 1982). Contamination of specimens with surface condensation from agar media or talc from latex gloves, disinfectants and soaps used for cleaning slides cause false-positive reactions. (Boom WH *et.al.*1985; Blevins LB *et.al.*1995).Sensitivity for CSF samples ranges from 93% to 100% and for serum samples ranges from 83% to 97% (Tanner DC *et al.*1994; Raux P *et al.*1996).

In Present study, MRI (brain/Spine) were performed in 12 patients. Focal edema (n=6), encephalomalacia (n=2), infarct (n=4) was observed. Among the 9 patients who underwent Computed Tomography (CT) head, 4 had diffuse atrophy hydrocephalus and 5 had diffuse cerebral atrophy. In previous study (Duarte *et.al.* 2017) observed leptomeningeal enhancement, in 5 (55.5%); perivascular space involvement, in 3 (33.3%); cryptococcal granulomas, in 3 (33.3%); cryptococcoma, in 1 (11.1%); ventriculitis, in 1 (11.1%); and hydrocephalus, in 1 (11.1%). 4 of the patients (44.4%) had 2-3 concomitant different MRI findings, the remaining 5 patients (55.6%) presenting with a single finding. Several authors have described the radiological patterns in HIV-infected patients with CNS cryptococcosis.<sup>26,27,28,29,30</sup>

The immunocompromised patients examined in the present study showed some findings that diverge from those reported in previous studies.<sup>31,32,33,34,35</sup>

A granulomatous reaction, with contrast enhancement, was more common among our patients than among those evaluated in previous studies.<sup>30,31,33,36,37</sup>

A Previous study observed that interpretation criteria for the Fluconazole and voriconazole disc diffusion tests and published in CLSI document Susceptible (S) zone diameter of  $\geq 19$ mm (fluconazole) and  $\geq 17$ mm (voriconazole); susceptible dose dependent (SDD), zone diameters of 15 to 18 mm (Fluconazole) and 14 to 16 mm (voriconazole) and resistant (R), zone diameters of  $\leq 14$ mm (fluconazole) and  $\leq 13$ mm (voriconazole).<sup>38</sup>

A Previous study observed no evidence of resistance among clinical isolates of *Cryptococcus neoformans* which are 100% susceptible to fluconazole (MIC 4 $\mu$ g/ml) and Voriconazole exhibited the highest inhibitory activity (MIC 0.056 $\mu$ g/ml).<sup>45</sup>

Another study observed that 31% out of 198, 61 isolates were *Cryptococcus* spp., MIC values have increased in Fluconazole and 99% out of 198, 197 were sensitive to Amphotericine B. 137/198 isolates (69%) were susceptible to Fluconazole (ie MIC  $\leq 8\mu$ g/ml) wherever, 56/198 isolates (28% of culture sensitive to Susceptible Dose Dependent (SDD) (ie MIC 16to 32  $\mu$ g/ml) and 3% (6/198) of cultures exhibited an MIC of  $\geq 64\mu$ g/ml, categorized as Fluconazole resistant.<sup>46</sup>

A previous study observed that among Cryptococcal meningitis cases, Fluconazole were sensitive in 77.1% and 11.2 % resistant. Voriconazole was sensitive in >90% and resistant in 1.7%<sup>38</sup> isolates. Another study observed that Cryptococcal meningitis 13 cases out of 35, 37.1% were found to have an elevated MIC to fluconazole (MIC $\geq 16\mu$ g/ml).<sup>39</sup> In Other study observed that Cryptococcal meningitis 16 cases out of 46, 34.8% were found to have an MIC value of Amphotericine B 0.25 $\mu$ g/ml (0.063-0.5  $\mu$ g/ml), Fluconazole 16  $\mu$ g/ml (0.5-64  $\mu$ g/ml) and voriconazole 0.125  $\mu$ g/ml (0.008-0.25  $\mu$ g/ml).<sup>44</sup>

Present study observed that among Cryptococcal meningitis cases, MIC range for Amphotericine B from 0.25-1  $\mu$ g/ml, and for Fluconazole was 2-4  $\mu$ g/ml, whilst the MIC range of voriconazole was found to be broader (0.125-8 $\mu$ g/ml). Antifungal Susceptibility of Cryptococcal Meningitis cases 100% sensitive to Amphotericine B and Fluconazole; 61.1% sensitive and 38.8% resistant to Voriconazole.

Koshy JM *et.al.* observed that with, the advent of Antiretroviral therapy (ART), Acquired Immunodeficiency Syndrome(AIDS) related cryptococcal infection is declining. 45% participants of this study were non-HIV patients. Initiation of ART within 1 to 2 weeks after diagnosis of Cryptococcal meningitis in patients not on ART has been shown to have higher risk for mortality compared with starting ART 5 weeks after diagnosis (45%vs 36% mortality at 26 weeks).<sup>8</sup> A Previous study showed that the treatment for cryptococcal meningitis is intravenous amphotericin B in combination with oral Flucytosine for a minimum of 2 weeks, followed by oral fluconazole for at least 8 weeks. Liposomal amphotericin B is associated with lower risks of renal toxic effects and other side-effects than conventional amphotericin B and has similar efficacy, but it is more expensive. Combined flucytosine with amphotericin B leads to faster and greater sterilisation of CSF than does amphotericin B alone.<sup>6</sup>

Several control trials performed before and after the introduction of ART have been used to develop therapeutic guidelines for the management of HIV-associated CM.<sup>8,40,41,42,43</sup>

The current therapy for CM is based on the WHO and the infectious disease Society of America Guidelines which recommend 2 weeks induction phase with combination therapy of Amphotericin B and Flucytosine followed by a 10 week consolidation therapy with Fluconazole.<sup>39</sup>

## CONCLUSION

In conclusion, Cryptococcal meningitis is a opportunistic infection with high mortality and morbidity. Combination of amphotericin B 0.7 to 1 mg/kg of body weight/day for 2 weeks and Fluconazole (800-1200mg/day) can be used. After induction therapy, using enhanced consolidation therapy with fluconazole 800 mg/day until documentation of CSF sterility and ART initiation should decrease the risk of persistent infection. ART should be initiated 4-6 weeks after the diagnosis of cryptococcal meningitis. The contribution of resistance to failure and death is unclear. Early initiation of ART in patients with HIV has been associated with increased mortality. In addition, novel oral drug treatments, such as adjunctive sertraline, need to be developed for use in rural areas where intravenous amphotericin B treatment may not be possible.

## Acknowledgement

The authors are thankful to Department of Science and Technology (WOS-A) scheme for extramural funding to carry out the study.

## Compliance with ethical standards

Conflict of interest The authors have no potential conflict of interest. The disclosure of potential conflict of interest in the prescribed format has been obtained from all the authors.

Ethical approval The study was ethically approved and the work was performed in strict accordance with the guidelines of Institutional Ethical Committee of Dr. Ram Manohar Lohia Institute of Medical Sciences (IEC 6/14).

Informed Consent The subjects were explained the study procedure and written and informed consent were obtained from them prior to study. The authors: Pushpa yadav, Manodeep Sen, Anupam Das, J.K. Srivastava, A.K. Singh, P.K. Maurya, Poonam Chaturvedi, H. S. Malhotra, Gaurav Raj Agarwal, Tanushri Chatterji are aware of ethical policy.

## References

1. Gottfredsson M, Perfect J R, Fungal Meningitis 2000, Seminars in Neurology;20:3.
2. John R. Perfect,1 William E. Dismukes,2 Françoise Dromer,11 David L. Goldman,3 John R. Graybill,4 Richard J. Hamill,5 Thomas S. Harrison,14 Robert A. Larsen,6,7 Olivier Lortholary,11,12 Minh-Hong Nguyen,8 Peter G. Pappas,2 William G. Powderly,13 Nina Singh,10 Jack D. Sobel,10 and Tania C. Sorrell15 Clinical Practice Guidelines for the Management of Cryptococcal Disease: 2010 Update by the Infectious Diseases Society of America Clinical Infectious Diseases 2010;50:291-322
3. Bicanic T, Meintjes G, Wood R, *et al.* Fungal burden, early fungicidal activity, and outcome in cryptococcal meningitis in antiretroviral-naïve or antiretroviral-experienced patients treated with amphotericin B or fluconazole. Clin Infect Dis 2007;45:76-80.
4. Badave RR, Basavaraj A, Clinical Profile of Cryptococcal Meningitis in Patients Living with HIV Infection: An Experience from Western India 2017, Medical Journal of Dr. D.Y. Patil Vidyapeeth;11(1).
5. Coen M, Tania SC, Kuchei WP, Proton Nuclear Magnetic Resonance-Based Metabonomics for Rapid Diagnosis of Meningitis and Ventriculitis 2006, Clinical Infectious Diseases 41:1582-90.
6. Marco CA, Rothman RE, HIV infection & Complications in Emergency Medicine, 2008, Emerg Med Clin N Am;26:367-387.
7. Summers NA, Armatrong WS, Management of Advanced Human Immunodeficiency Virus Disease, 2019, Infect Dis Clin N Am <https://doi.org/j.idc.2019.05.005>.
8. Koshy JM, Mohan S, Deodhar D, John M, Oberoi A, Pannu A, Clinical Diversity of CNS Cryptococcosis, 2016, Journal of the Association of Physicians of India; 64:15-19.
9. Tan IL, Smith BR, Geldern G, Mateen FJ, McArthur JC, HIV Associated Opportunistic Infections of the CNS, 2012, Lancet Neurol;11:605-17.
10. Dai YN, Huang HJ, Song WY, Tong YX, Yang DH, Wang MS, Huang YC, Chen MJ, Zhang JJ, Ren Z, Zheng W, Pan HY, Identification of potential metabolic biomarkers of cerebrospinal fluids that differentiate tuberculous meningitis from other types of meningitis by a metabolomics study 2017, Oncotarget 59;8:100095-100112.
11. Abassi M, Boulware RD, and Rhein J, Cryptococcal Meningitis: Diagnosis and Management Update; Curr Trop Med Rep. 2015 June 1; 2(2): 90-99. doi:10.1007/s40475-015-0046-y.
12. Manodeep Sen\*, Tanushri Chatterji, Vivek Singh, Pushpa Yadav, Anupam Das and Vineeta Mittal, Cryptococcal meningitis in HIV (AIDS) patients, AABS.2017.1344.
13. Lakshmi V, Sudha T, Teja VD, Umabala P. Prevalence of central nervous system cryptococcosis in human immunodeficiency virus reactive hospitalized patients. Indian J Med Microbiol 2007;25:146-9.
14. Kumar S, Wanchu A, Chakrabarti A, Sharma A, Bambery P, Singh S, *et al.* Cryptococcal meningitis in HIV infected: Experience from a North Indian tertiary center. Neurol India 2008; 56:444-9.
15. Prasad KN, Agarwal J, Nag V L, Verma A K, Dixit AK, Ayyagari A, Cryptococcal infection in patients with clinically diagnosed meningitis in a tertiary care center; Neurological Society of India 2003; 51:3;364-366.
16. Chaurasia S, Waghmare A, Joshi A, Study the utility of Cryptococcal Latex Agglutination Test in HIV-Positive and Negative Patients Suspected of having Cryptococcal meningitis & Compare with India Ink Preparation & Fungal Culture 2017, Int. J. Curr. Microbiol. App. Sci 6(1):484-491.
17. Satishchandra P, Nalini A, Gourie-Devi M, Khanna N, Santosh V, Ravi V, *et al.* Profile of neurologic disorders associated with HIV/AIDS from Bangalore, South India (1989-96). Indian J Med Res 2000;111:14-23.
18. Heydermann S, Gangaidzo T, Hakim G, Mielke J, Taziwa A, Musvaire P, Robertson J and Mason R, Cryptococcal meningitis in Human Immunodeficiency

- Virus- Infected Patients in Harare, Zimbabwe,1998 , *Clinical Infectious Diseases*;26:284-9.
19. Taneja J, Mishra B, Bhargava A, Loomba P, Dogra V, Thakur A, Cryptococcal Meningitis in a Tertiary Care Hospital, 2009, *Japan J. Med. Mycol*;50:95-99.
  20. Kanchan M, Patil S, Kumaer R, Bhushan N, Mahale R, Prevalence of Cryptococcal meningitis among Immunocompetent & Immunocompromised individuals in Bellay, South India- A Prospective Study,2012, *Journal of Clinical & Diagnostic Research*;6(3):388-392.
  21. Kumar S, Wanchu A, Chakrabarti A, Sharma A, Bambery P, Singh S, *et al.* Cryptococcal meningitis in HIV infected: Experience from a North Indian tertiary center. *Neurol India* 2008;56:444-9.
  22. Capoor MR, Nair D, Deb M, Gupta B, Aggarwal P. Clinical and mycological profile of cryptococcosis in a tertiary care hospital. *Indian J Med Microbiol* 2007;25:401-4
  23. Mitchell DH, Sorrell TC, Allworth AM, Health CH, McGregor AR, Papanoum K, *et al.* Cryptococcal disease of the CNS in immunocompetent hosts: influence of cryptococcal variety on clinical manifestations and outcome. *Clin Infect Dis* 1995; 20:611-16.
  24. Hamilton, J. R., A. Noble, D. W. Denning, and D. A. Stevens. 1991. Performance of cryptococcus antigen latex agglutination kits on serum and cerebrospinal fluid specimens of AIDS patients before and after pronase treatment. *J. Clin. Microbiol.* 29:333-339.
  25. Bennett, J. E. and J. W. Bailey. 1971. Control for rheumatoid factor in the latex test for cryptococcosis. *Am.J.Clin.Pathol.* 56:360-365.
  26. Mathews VP, Alo PL, Glass JD, *et al.* AIDS-related CNS cryptococcosis: radiologic-pathologic correlation. *AJNR Am J Neuroradiol.* 1992; 13:1477-1486. [PubMed] [Google Scholar]
  27. Smith AB, Smirniotopoulos JG, Rushing EJ. From the archives of the AFIP: central nervous system infections associated with human immunodeficiency virus infection: radiologic-pathologic correlation. *Radiographics.* 2008; 28:2033-2058. [PubMed] [Google Scholar]
  28. Starkey J, Moritani T, Kirby P. MRI of CNS fungal infections: review of aspergillosis to histoplasmosis and everything in between. *Clin Neuroradiol.* 2014; 24:217-230. [PubMed] [Google Scholar]
  29. Corti M, Villafañe MF, Negroni R, *et al.* Magnetic resonance imaging findings in AIDS patients with central nervous system cryptococcosis. *Rev Iberoam Micol.* 2008;25:211-214. [PubMed] [Google Scholar]
  30. Loyse A, Moodley A, Rich P, *et al.* Neurological, visual, and MRI brain scan findings in 87 South African patients with HIV-associated cryptococcal meningoencephalitis. *J Infect.* 2015;70:668-675. [PubMed] [Google Scholar]
  31. Miszkial KA, Hall-Craggs MA, Miller RF, *et al.* The spectrum of MRI findings in CNS cryptococcosis in AIDS. *Clin Radiol.* 1996;51:842-850. [PubMed] [Google Scholar]
  32. Smith AB, Smirniotopoulos JG, Rushing EJ. From the archives of the AFIP: central nervous system infections associated with human immunodeficiency virus infection: radiologic-pathologic correlation. *Radiographics.* 2008;28:2033 2058. [PubMed] [Google Scholar]
  33. Cheng YC, Ling JF, Chang FC, *et al.* Radiological manifestations of cryptococcal infection in central nervous system. *J Chin Med Assoc.* 2003; 66:19-26. [PubMed] [Google Scholar]
  34. Andreula CF, Burdi N, Carella A. CNS cryptococcosis in AIDS: spectrum of MR findings. *J Comput Assist Tomogr.* 1993; 17:438-441. [PubMed] [Google Scholar]
  35. Grosse P, Tintelnot K, Söllner O, *et al.* Encephalomyelitis due to *Cryptococcus neoformans var gattii* presenting as spinal tumour: case report and review of the literature. *J Neurol Neurosurg Psychiatry.* 2001;70:113-116. [PMC free article] [PubMed] [Google Scholar]
  36. Kamezawa T, Shimozuru T, Niuro M, *et al.* MRI of a cerebral cryptococcal granuloma. *Neuroradiology.* 2000; 42:441-443. [PubMed] [Google Scholar]
  37. Berkefeld J, Enzensberger W, Lanfermann H. *Cryptococcus meningoencephalitis* in AIDS: parenchymal and meningeal forms. *Neuroradiology.* 1999; 41:129-133. [PubMed] Google Scholar]
  38. Pfaller M, Diekema DJ, Gibbs DL, *et al.* Results from the ARTEMIS DISK Global Antifungal Surveillance Study, 1997-2007: 10.5 -year analysis of susceptibilities of noncandidal yeast species to fluconazole and voriconazole determined by CLSI standardized disk diffusion testing. *Eur J Clin Microbiol* 2009;47:117-23.
  39. Nasri H, Kabbani S, Alwan MB, Wang YF, Rebolledo PA, Kraft CS, Nguyen ML, Anderson AM, Roupheal N, Retrospective study of Cryptococcal meningitis with elevated Minimum Inhibitory Concentration to Fluconazole in Immunocompromised Patients,2016, OFID:1-5.
  40. Vidal JE, Miranda PD, Gerhardt J, Croda M, Boulware DR, Is it possible to differentiate tuberculous & Cryptococcal meningitis in HIV-infected patients using only clinical and basic cerebrospinal fluid Characteristics? 2017, *S Afr Med J* 107(2):156-159.
  41. Baradkar V, Mathur M, De A, Kumar S, rathi M, Prevalence and clinical presentation of Cryptococcal meningitis among HIV seropositive patients, *Indian J Sex Transm Dis & AIDS* 2009; 30:1 DOI:10.4103/0253-7184.55474.
  42. Badave R.R., BasavarajA., Clinical Profile of Cryptococcal Meningitis in Patients Living with HIV Infection: An Experience from Western India; *Medical Journal of Dr. D.Y. Patil Vidyapeeth* 2018; 30:1 DOI: 10.4103/MJDRDYPU.MJDRDYPU\_86\_17
  43. Raberahona M, Rakotoarivelo RA, Randriamampionona N, Rakotomalala F A, finambinintsoa RT, Bénét T, Vanhems P, MamyJ.D.,Randria D, Cornet M, Andrianarivelo MR, Rapid Fatal Outcome of Cryptococcal Meningoencephalitis in a Non-HIV Immunocompromised Patient with a Low Fluconazole Susceptibility Isolate: A Case Report from Madagascar; *Case Reports in Infectious Diseases* 2016 <http://dx.doi.org/10.1155/2016/3492504>
  44. Tomazin R, Matos T, Meis JF, Hagen F, Molecular characterization and Antifungal Susceptibility Testing of Sequentially Obtained Clinical *Cryptococcus*

- deneoformans and *Cryptococcus neoformans* Isolates from Ljubljana, Slovenia, 2018, *Mycopathologia*, 183; 2:371-380.
45. Sharma r, Duggal N, Malhotra S, Shrivastava D, Hans C; Antifungal Susceptibility of *Cryptococcus neoformans* isolates from fungal meningitis in AIDS Patients in India; *International journal of Pharmacy & Pharmaceutical Sciences*; 2014:6(7).
46. Smith KD, Achan B, Hullsiek KH, McDonald TR, Okagaki LH, Alhadab AA, Akampurira A, Rhein JR, Meya DB, Boulware DR, Nielsen K, Increased Antifungal Drug Resistance in Clinical isolates of *Cryptococcus neoformans* in Uganda; Antimicrobial agents and Chemotherapy. *Journal ASM org*; 2015:59(7197-7204).

**How to cite this article:**

Pushpa Yadav *et al* (2019) 'Clinical Pattern and Antifungal Susceptibility of *Cryptococcus Neoformans* from Cryptococcal Meningitis Patients in Northern India', *International Journal of Current Advanced Research*, 08(08), pp.19581-19588.  
DOI: <http://dx.doi.org/10.24327/ijcar.2019.19588.3788>

\*\*\*\*\*