



Research Article

CHOLESTEATOMA INVADING THE INTERNAL AUDITORY CANAL : RARE CASE REPORT

Hicham Attifi¹, Nabil Touihem¹, Mounir Elhmidi¹, Taoufiq Africha², Karim Nadour¹, Ali Elboukhari¹, Brahim Zainoun²and Mohammed Zalagh³

¹Department of Otorhinolaryngology, Military Hospital Moulay Ismail, Meknes, Morocco

²Department of Radiology, Military Hospital Moulay Ismail, Meknes, Morocco

³ Department of Otorhinolaryngology, Military Hospital Mohammed V, Rabat, Morocco

ARTICLE INFO

Article History:

Received 15th March y, 2019

Received in revised form 7th

April, 2019

Accepted 13th May, 2019

Published online 28th June, 2019

Key words:

Cholesteatoma, Internal auditory canal , Facial paralysis.

ABSTRACT

Cholesteatoma invading the internal auditory canal (IAC) is rare and usually exposes the facial and vestibulo-cochlear nerves functions to a serious threat. We reported the case of a 47-years-old patient having severe hearing loss in his left ear and facial paralysis in the affected side. Otomicroscopic examination of the left ear showed a whitish mass in the attic region covered by a reddish polypoidal tympanic membrane. Audiometric evaluation objectified the absence of response in the left ear. Temporal bone imagery revealed a left supra-labyrinthine petrous bone Cholesteatoma involving the IAC. A Transmastoid translabyrinthine (TL) with transcotic surgical approach has been programmed. Early diagnosis of cholesteatoma invading the IAC is important to prevent severe functional damage.

Copyright©2019 Hicham Attifi et al. This is an open access article distributed under the Creative Commons Attribution License, which permits unrestricted use, distribution, and reproduction in any medium, provided the original work is properly cited.

INTRODUCTION

Petrous bone cholesteatoma (PBC) is epidermoid cyst which expands in the petrous portion of the temporal bone. It may be congenital or acquired. The involvement of the membranous labyrinth and IAC is rare and usually causes irreversible, complete hearing loss and facial paralysis in the affected side. Computed tomography (CT) and magnetic resonance imaging (MRI) of the temporal bone should establish the final diagnosis [1]. Surgery for cholesteatoma invading the IAC can be complicated. Lateral transtemporal and middle fossa approaches are classically used to remove PBC [2]. The aim of our work, through a case of PBC invading the IAC, was to describe the clinical, paraclinical and therapeutic aspects of this unusual pathological entity.

Case Report

A 47-years-old patient with history of severe hearing loss in his left ear and facial paralysis in the affected side (Fig. 1), which started 3 years before coming to our department, and no balance disorder. Otomicroscopic examination of the left ear showed a whitish mass in the attic region covered by a reddish polypoidal tympanic membrane. The patient had a normal looking right ear.. The facial palsy was evaluated as IV grade according to the House–Brackmann.

*Corresponding author: Hicham Attifi

Department of Otorhinolaryngology, Military Hospital Moulay Ismail, Meknes, Morocco

Audiometric evaluation objectified the absence of response in the left ear with normal hearing level in the right ear. Temporal bone CT revealed that the left middle ear cavity was completely occupied by a soft tissue mass, the erosion of the tegmen tympani and the bone around the geniculate ganglion and the invasion of the IAC via translabyrinthine route (Fig. 2). T1-weighted MRI showed a low signal intensity mass and the T2- weighted MRI images revealed a high signal intensity mass without intracranial extension (Fig. 3). Taking into account the combination of various factors (location and extension of the lesion, hearing loss, preoperative facial nerve paralysis and anatomic position of the internal carotid artery and jugular bulbe), a transmastoid translabyrinthine (TL) with transcotic surgical approach has been programmed.

Table 1 Sanna’s Classification

Classification	Definition
Supralabyrinthine	It involves the anterior epitympanum and extends medially toward the internal auditory canal and anteriorly toward the carotid artery. The basal turn of the cochlea may be involved. Posteriorly, the cholesteatoma may spread toward the posterior aspect of the bony labyrinth and the retrolabyrinthine mastoid cells
Infralabyrinthine	It involves the hypotympanic and infralabyrinthine regions and extends anteriorly toward the internal carotid artery and posteriorly toward the posterior cranial fossa.
Massive labyrinthine	It involves the entire anterior and posterior labyrinth
Infralabyrinthine-apical	It extends either anteriorly into the petrous apex and may involve the sphenoid sinus and the

horizontal portion of the internal carotid artery, or arises in the apical compartment and extends superiorly to the sphenoid sinus and inferoposteriorly to the infralabyrinthine compartment.

Apical

It involves only the apical compartment of the temporal bone; it can cause erosion of the internal auditory canal and extend toward the posterior cranial fossa or anteriorly to the trigeminal nerve.

invades the bony labyrinth and erodes the petrous apex and the skull base around the internal auditory canal (IAC) and may extend as far as the cerebellopontine angle. Furthermore, these lesions may affect other vital soft tissue structures within the temporal bone such as the sigmoid sinus or the jugular vein and carotid artery[1]. As regard the source and extension of cholesteatomas, Sanna *et al* classified [4] five types of PBC lesion: supralabyrinthine, infralabyrinthine, massive labyrinthine, infralabyrinthine–apical, and apical (**table 1**). The invasion into the IAC is rare and originates from either acquired giant cholesteatomas, which aggressively erode the labyrinth, or from congenital cholesteatomas that develop in the vicinity of the IAC [1].

Clinical presentation of petrous bone cholesteatoma invading the IAC may be misleading. we agree with and highlight the recommendation of Sanna *et al*, that a petrous bone cholesteatoma should be suspected in a patient with medical history of chronic otitis media and mastoid surgery or/and a clinical history of progressive sensorineural hearing loss, and progressive facial nerve palsy[4]. In the present case, facial palsy was associated with the ipsilateral hearing. Facial palsy is frequently associated with extensive cholesteatoma. This symptom is often related to the involvement of the geniculate ganglion and the tympanic segment of the nerve following the extension of the cholesteatoma to the supratubal recess from the attic compartment. Preoperative facial nerve palsy, which is present in more than 50% of cases in the literature deserves a poor prognosis[5].

The preoperative radiological examination of an extensive cholesteatoma is based on temporal bone CT revealing a mass with bony destruction extending from the middle ear cavity into the IAC, sometimes widening the fallopian canal. MRI can provide important information in cases with intracranial extension, as well as suggesting the probable histological type of the lesion [6].

The value of a high resolution CT scan and MRI is not only in the detection of petrous bone cholesteatoma but in the exact localization of the lesion as well as in the determination of its route of spread. This is of a paramount importance in planning for the surgical access and the technique[3]. Based on the imagery location and extension and following the classification of Sanna *et al*, our case of was classified into supralabyrinthine PBC.

The IAC region is usually inaccessible in mastoid surgery and so it presents a real surgical challenge for the neuro-otologist. Removal of a cholesteatoma from this region requires special surgical techniques such as an STP, an MCF approach or a TL approach [7]. The choice of the best surgical approach is based on the location and extension of the lesion, hearing, preoperative facial nerve paralysis, and anatomic position of the internal carotid artery and jugular bulb. It must guarantee that the cholesteatoma is visible in its entirety and ensure a sufficient exposure of the middle and posterior fossa dura, carotid artery, lateral sinus, jugular bulb, and facial nerve[8]. The Transmastoid translabyrinthine (TL) with transcotic surgical approach is the procedure of choice for an cholesteatoma invading the IAC where hearing preservation is impossible[1].

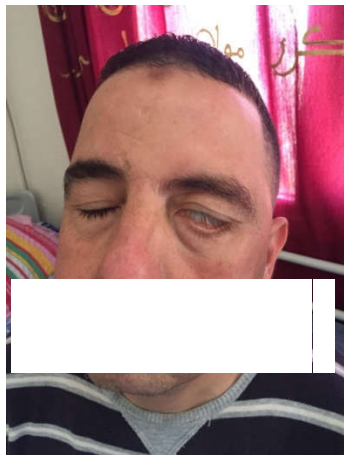


Figure 1 Charle Bell's sign

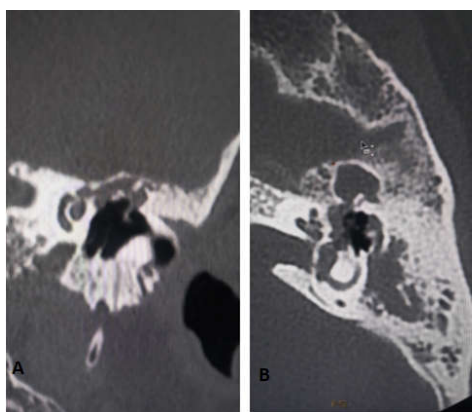


Figure 2 A + B: An axial CT scan.of the Temporal bone revealing a left middle ear cavity completely filling by a soft tissue mass with an erosion of the tegmen tympani and the bone around the geniculate ganglion with the invasion of the IAC via translabyrinthine route

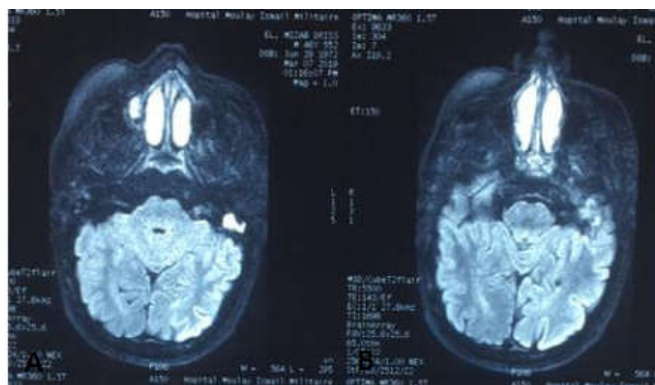


Figure 3 A+B : the T2- weighted MRI revealing a high signal intensity mass the left middle ear cavity without intracranial extension

DISCUSSION

Petrous bone cholesteatoma describes an epidermoid cyst affecting the petrous portion of the temporal bone. It is a rare pathological entity with a reported incidence of 4 to 9% of all lesions affecting the petrous pyramid [3]. A PBC gradually

CONCLUSION

Cholesteatoma invading the IAC is an uncommon pathology but may cause severe functional damage and negatively affect the quality of life. The value of imaging is not only in the detection of cholesteatoma but in the exact localization of the lesion as well as in the determination of its path of spread and provide the required information to the surgeon for planning the surgical access and technique.

References

1. Iannella, G., Savastano, E., Pasquariello, B., Re, M., & Magliulo, G. Giant petrous bone cholesteatoma: combined microscopic surgery and an adjuvant endoscopic approach. *Journal of neurological surgery reports*. 2016; 2(01) : 46-49
2. Zanoletti, E., *et al.* 106th Congress of the Italian Society of Otorhinolaryngology Head and Neck Surgery Official report: Surgery of the lateral skull base: a 50-year endeavour. *Acta Otorhinolaryngologica Italica*, 2019 39(3) :1
3. Naguib, M. B. Surgical Management of Cholesteatoma Growing Medially into the Petrous part of the Temporal Bone. *Surgery*.2013 ;12(12) : 2161-1076.
4. Sanna, M., Pandya, Y., Mancini, F., Sequino, G., & Piccirillo, E. Petrous bone cholesteatoma: classification, management and review of the literature. *Audiology and Neurotology*, 2011,16(2) : 124-136.
5. Aubry, K., Kovac, L., Sauvaget, E., Huy, P. T. B., & Herman, P. Our experience in the management of petrous bone cholesteatoma. *Skull Base*. 2010 , 20(03) : 163-167.
6. Moffat D, Jones S, Smith W. Petrous temporal bone cholesteatoma: a new classification and long-term surgical outcomes. *Skull Base* 2008 18(2): 107-115
7. Migirov, L., Bendet, E., & Kronenberg, J.). Cholesteatoma invasion into the internal auditory canal. *European Archives of Oto-Rhino-Laryngology*, 2009 266(5), 657.
8. Presutti, L., Bonali, M., Marchioni, D., Pavesi, G., Feletti, A., Anschuetz, L., & Alicandri-Ciuffelli, M.). Expanded transcanal transpromontorial approach to the internal auditory canal and cerebellopontine angle: a cadaveric study. *Acta otorhinolaryngologica italica*,2017 37(3), 224.

How to cite this article:

Hicham Attifi *et al* (2019) 'Cholesteatoma Invading the Internal Auditory Canal: Rare Case Report', *International Journal of Current Advanced Research*, 08(06), pp.19031-19033. DOI: <http://dx.doi.org/10.24327/ijcar.2019.19033.3654>
