



**DEEP NECK SPACE INFECTIONS – A 3 YEAR STUDY AT TERTIARY CARE  
CENTRE OF WEST BENGAL, INDIA**

**Vedula Padmini Saha, Dr.Animesh Ghosh, Sudipta Pal, Anirban Ghosh and Somnath Saha**

Department of Plastic Surgery, R.G.Kar Medical College, Kolkata, West Bengal, India

**ARTICLE INFO**

**Article History:**

Received 13<sup>th</sup> February, 2019

Received in revised form 11<sup>th</sup>

March, 2019

Accepted 8<sup>th</sup> April, 2019

Published online 28<sup>th</sup> May, 2019

**Key words:**

Deep neck space infection, DNSI, surgical management

**ABSTRACT**

**Aims:** To find out the epidemiological profile of the patients with deep neck space infections (DNSI), to study the rate of life-threatening complications & their predisposing factors in these cases and to find out the mortality rates in DNSI & to compare it with previous studies.

**Material & methods:** A total number of 138 cases of deep neck space infection were admitted in Dept. of ENT, Calcutta National Medical College from May 2015 to April 2018. All patients underwent detailed ENT & systemic examinations and bacteriological investigations. Selected cases were subjected to radiological investigations like plain radiography and CT scan of neck. All the patients were treated with parenteral antibiotics and surgical drainage of the abscess whenever required.

**Results:** In our study, the mean age of presentation was 32.2 +/- 18.7 years (ranging from 3 months to 77 years), with male: female ratio of 1:1. Peritonsillar abscess (26.1 %) was the most common type of DNSI according to our study, followed by para-pharyngeal (18.8 %), retropharyngeal (15.2 %), Ludwig's angina (11.6 %), parotid (8 %), anterior visceral space (7.2 %), submandibular space (6.5 %), sublingual (4.3 %) and prevertebral abscess (2.2 %). Odynophagia (66.7 %) and remittent fever (57.2 %) were the commonest presenting symptom in our cases. Odontogenic infection (52.9 %) was the commonest etiological factor noted in our study, followed by chronic tonsillitis (23.2 %). Diabetes Mellitus was the most common systemic disease found to be associated with DNSIs (27.5 %). Aerobic Streptococci (40.6 %) and E. coli (31.9 %) were the most common pathogen associated with deep neck space infection in our study. The cases with superficial infections only (e.g. peritonsillar space infections and Ludwig's angina) could be diagnosed clinically, but other deeper infections needed plain radiography or CT scan for diagnosis. 26 patients developed life-threatening complications like airway obstruction (16.7 %), pneumonitis (11.6 %), gram-negative septicemia (8 %), descending mediastinitis (1.4 %) & Jugular vein thrombosis (0.7 %). 102 cases were treated by surgical drainage (73.9 %) the remaining 36 cases responded promptly to intravenous antibiotic therapy and surgical drainage was not necessary. 7 patients died.

**Conclusion:** Our study showed that time was the most important factor governing the outcome of the DNSI cases— early & accurate diagnosis and timely referral to the tertiary care center is essential. In all the cases airway, breathing and circulation should be assessed and attended to if required. Antibiotic therapy with or without definitive surgical drainage is the management modality. These simple steps will go a long way in saving the lives of these patients.

Copyright©2019 Vedula Padmini Saha et al. This is an open access article distributed under the Creative Commons Attribution License, which permits unrestricted use, distribution, and reproduction in any medium, provided the original work is properly cited.

**INTRODUCTION**

Since time immemorial, DNSI has been a very important cause of morbidity and mortality and the situation has not changed much in spite of recent advances in medical sciences. The widespread and inappropriate use of antibiotics has changed the clinical presentation and course of these infections, making them more elusive and less predictable.

\*Corresponding author: **Dr.Animesh Ghosh**

Department of Plastic Surgery, R.G.Kar Medical College, Kolkata, West Bengal, India

Upper airway obstruction, mediastinitis, erosion and rupture of the carotid artery, internal jugular vein thrombosis, metastatic abscesses and septic shock are known complications of DNSI cases<sup>1</sup>.

Superficial and deep cervical fascia encloses vital neuromuscular and visceral structures of neck. Superficial fascia en-sheathes platysma and muscles of facial expression; infection of this layer is not included in deep neck space infection.

Deep cervical fascia is divided into superficial (investing layer), middle and deep layers. Investing layer encompasses trapezius, muscles of mastication, submandibular, parotid glands and fuses with fascial covering of anterior and posterior belly of digastric. Middle layer, which is again divided into muscular and visceral layers, surrounds sternohyoid, sternothyroid, thyrohyoid and adventitia of great vessels. Superiorly it forms buccopharyngeal membrane and inferiorly condenses with deep alar layer to form posterior layer of retropharyngeal space. Deep layer is divided into alar and prevertebral layers. The space between these two layers forms the 'Dangerous space'.

Different neck spaces are present between these layers of cervical fascia. Conventionally, they are divided by the level of hyoid bone. Important neck spaces are below the hyoid, carotid space, prevertebral space, prevascular space, visceral space and pretracheal space; above the hyoid, parotid space, masseter space, submaxillary space and submandibular space. Among peri-pharyngeal spaces retropharyngeal, parapharyngeal intrapharyngeal, paratonsillar spaces as well as anterior and posterior cervical spaces are important.

## **MATERIALS AND METHODS**

This longitudinal prospective study was carried out at the Department of ENT of Calcutta National Medical College, within a 3-year period from May 2015 to April 2018. All patients admitted with DNSI in our ward during this period were included- the total number being 138. In all the cases diagnosis was confirmed by the triad of- a) history & clinical examination, b) plain radiography of soft tissue of neck & CT Scan of neck and c) bacteriological investigation of aspirated or drained pus. Clinical charts, imaging and bacteriologic studies were reviewed. The following variables were reviewed: demographic data, pathogenesis, clinical presentation, associated systemic diseases, bacteriology, imaging studies (Plain radiography and CT scan), complications at presentation, medical & surgical treatment, and incidence & cause of death. Infections were categorized according to the involved spaces (peritonsillar, para-pharyngeal, retropharyngeal, prevertebral, parotid, masticatory, visceral vascular, submandibular, sublingual, submental & floor of the mouth and anterior visceral) and to their character (cellulites versus abscess). Patients with involvement of two or more spaces were classified having multiple-space infection. The site and character of the infection were confirmed by imaging studies, needle aspiration or during surgery. Associations between life-threatening complications and other factors were determined by 2 tests, Fisher's exact test and Student's t test as appropriate. The epidemiological data of each case was noted, the abscesses were drained by proper surgical incision under broad-spectrum antibiotic coverage (IV Ceftriaxone+ Gentamycin+ Metronidazole) whenever required. The pus was sent for Gram staining and culture-sensitivity examination in each case. Cases with compromised airway were treated immediately with life-saving procedures like tracheostomy. The mortality data of the series were analyzed and presented here.

## **RESULT**

The analysis of the pattern of age distribution of our 138 patients revealed that all age groups were affected by these infections (3 months to 77 years), the mean age being 32.2 +/-

18.7 years. However, 43 patients (31.2 %) were in the 4<sup>th</sup> decade followed by 31 (22.5 %) in the 3<sup>rd</sup> decade thereby making them the most susceptible age groups according to our study. (Table-1, Figure-1)

According to our study male: female ratio was 1: 1; 71 cases (51.5 %) were male and the rest 67 female (48.5 %). Peritonsillar (61.1 %), prevertebral (100 %) and anterior visceral (80 %) abscesses showed male preponderance. In cases of submandibular abscess (66.7 %) and Ludwig's angina (75 %), a definite female predominance was noted. In all other types of infections noted in our study, there was no significant sex predilection (Table-2, Figure-2).

We encountered infections of almost all the major deep neck spaces in our 2-year long study. We recorded the data for the anatomical site of the infection; as also the nature of the affection, in the form of whether the infection was in the stage of cellulitis at presentation or frank abscess had developed needing surgical evacuation. Few patients had multiple space infections where the disease originated from one deep neck space and gradually involved the adjoining space/s. Most numerous were the cases of peritonsillar space infection (26.1 %). Many delayed cases of peritonsillar abscess had spread into the lateral pharyngeal or para-pharyngeal spaces, which was the second most common site to be affected (18.8 %). Retropharyngeal space involvement was diagnosed in 15.2 % cases. Infections of the floor of mouth (Ludwig's Angina) and submental space were seen in 11.6 % patients. Parotid space (8 %), anterior visceral space (7.2 %), submandibular space (6.5 %), sublingual space (4.3 %) and prevertebral space (2.2 %) involvements were found to be relatively rare (Table-2).

Odynophagia was the commonest presenting symptom in our cases (66.7 %) followed by remittent fever (57.2 %). Pain and tenderness over the swelling or the abscess was found in 33.3 % of the patients and 31.2 % complained of otalgia of the ipsilateral side. Patients also presented to us with dysphagia (22.5 %), trismus (21.7 %) and even dyspnoea (21 %). Only 14.5 % cases had dysphonia as a presenting complaint (Table 3). Deep neck space infections rarely arise de-novo, but more commonly they are the result of spread from some local foci of infection that has been previously present in some anatomically related structure. Dental infection is widely regarded as the commonest etiological factor of deep neck space infection. In our study we found associated dental caries in (52.9 %) of the patients. Chronic tonsillitis (23.2 %), adenoids in children (9.4 %) and persistent granular pharyngitis (5.1 %) were other important causes. Retained foreign bodies (1.4 %) together with active vertebral tuberculosis (0.7 %) were some rare aetiological factor noted in our study (Table-4).

Most of the peritonsillar space infections were mostly abscesses (75 %). Majority of the cases with lateral pharyngeal or para-pharyngeal space infections presented with abscess of the involved space (80.8 %). Regarding retropharyngeal space involvement, only three had cellulitis and the rest had frank abscess (85.7 %). 3 cases of prevertebral space abscess (100 %) were found. Infections of the floor of mouth (Ludwig's Angina) & sub mental space (75 %), submandibular space (66.7 %) and parotid space (81.8 %) were predominantly cellulitis and rarely abscess (only 4 cases) (Table-5). Diabetes Mellitus was the most common systemic disease found to be associated with DNSIs (27.5 %). 13.8 % patients were found to be suffering from systemic hypertension. Active

tuberculosis was found in 7 patients (5.1 %); 6 of them had vertebral tuberculosis and one had pulmonary tuberculosis. 4 patients (2.9 %) of post-radiation carcinoma larynx presented with diffuse peritonsillar and para-pharyngeal space infection and 2 cases (1.5 %) of retropharyngeal abscess were diagnosed cases of bronchogenic carcinoma. The pus was sent in all the cases for gram staining and culture sensitivity. Gram-positive aerobic Streptococci were found in 40.6 % cases, followed by E. coli in 31.9 %, Proteus species in 10.1 %, anaerobic Streptococci in 5.6 %, Staph. aureus in 5 (3.6 %) and other anaerobic bacteriae in 8 % cases. The interesting finding here was the high incidence of E. coli infections, which were second most common bacteria, found in the aspirates (Table-6). 9 out of 44 cases of E. coli (20.5 %) and 8 out of 14 cases of Proteus infection (57.1 %) were found to be multi-drug resistant whereas only 3 instances of multi-drug resistance were found among those with Streptococcal infection (5.4 %).

Plain radiography with or without CT scan was done whenever any deep space infection was diagnosed that could not be assessed properly by clinical examination only. Those cases with superficial infections that could be diagnosed clinically only (e.g. the cases of peritonsillar space infections and Ludwig's angina), were not subjected to any radiological investigation. But all of the retropharyngeal, 60 % of the anterior visceral & 46.2 % of the para-pharyngeal space infections needed plain radiography and all 3 of the prevertebral, 40 % of the anterior visceral, 44.4 % of the submandibular, 33.3 % of the retropharyngeal, 27.3 % of the parotid & 7.7 % of the para-pharyngeal space infections needed CT scan for definitive diagnosis (Table-7).

Delayed medical attention may lead to life threatening complications of DNSI. In our series we had 23 cases (16.7 %) patients presenting with severe airway obstruction and respiratory distress needing immediate surgical intervention in the form of tracheostomy. Patients also reported with other complications like pneumonitis (11.6 %), gram-negative septicemia (8 %), descending mediastinitis (1.4 %) and Jugular vein thrombosis (0.7 %) (Table-8).

Surgical evacuation of the abscess cavity under the cover of sensitive intravenous antibiotics (mostly by Ceftriaxone, Gentamicin & Metronidazole) after securing the airway has been the management protocol in this study. Majority (73.9 %) of the cases were put to surgery in all types of infections except in the cases of Ludwig's angina where a high incidence of cellulitis was noted and were treated with antibiotic therapy only. Out of the 3 cases of prevertebral abscess one case was treated by emergency tracheostomy and CT-guided aspiration; the remaining 2 were drained by external approach-while 1 patient responded promptly, the other one could not be saved (Table-9). 7 patients died in the course of our study (i.e. 5.1 % mortality rate). The cause of death in the present series were Gram-negative septicemia with disseminated intravascular coagulation (DIC) in 3 cases, descending mediastinitis in 2 cases and pneumonia with respiratory failure in 2 cases.

**Table 1** Age distribution of different types of deep neck space infections

Site of infection	AGE GROUPS (YEARS)							
	0-10	11-20	21-30	31-40	41-50	51-60	61-70	>70
Parotid	3	2	5	0	1	0	0	0
Peritonsillar	0	0	5	19	6	1	3	2
Submandibular	1	2	1	3	2	0	0	0
Sublingual	0	2	0	2	0	1	1	0
Ludwig's angina	2	3	3	2	4	2	0	0

Parapharyngeal	2	1	10	11	2	0	0	0
Retropharyngeal	3	6	5	3	0	2	2	0
Prevertebral	0	0	0	2	1	0	0	0
Anterior visceral	0	0	2	1	3	4	0	0
<b>Total</b>	<b>11</b>	<b>16</b>	<b>31</b>	<b>43</b>	<b>19</b>	<b>10</b>	<b>6</b>	<b>2</b>

**Table 2** Sex distribution of different types of deep neck space infections

Site of infection	Male	Female	Total	Percentage (%)
Parotid	5	6	11	8
Peritonsillar	22	14	36	26.1
Submandibular	3	6	9	6.5
Sublingual	3	3	6	4.3
Ludwig's angina	4	12	16	11.6
Parapharyngeal	12	14	26	18.8
Retropharyngeal	11	10	21	15.2
Prevertebral	3	0	3	2.2
Anterior visceral	8	2	10	7.2
<b>Total</b>	<b>71</b>	<b>67</b>	<b>138</b>	<b>100</b>

**Table 3** Clinical presentation of the cases with deep neck space infections

Clinical presentation	No. Of cases	Percentage (%)
Odynophagia	92	66.7
Fever	79	57.2
Painful swelling	46	33.3
Otalgia	43	31.2
Dysphagia	31	22.5
Trismus	30	21.7
Dyspnoea	29	21
Dysphonia	20	14.5

**Table 4** Pathogenesis of DNSIs

Aetiology	No. of cases	Percentage (%)
Dental caries	73	52.9
Chronic tonsillitis	32	23.2
Adenoids in children	13	9.4
Persistent granular pharyngitis	7	5.1
Retained foreign body	2	1.4
Active vertebral tuberculosis	1	0.7

**Table 5** Distribution of the site and character of DNSIs

Site	Abscess	Cellulitis	Total
Peritonsillar space	27	9	36
Parapharyngeal space	21	5	26
Submandibular space	3	6	9
Parotid space	2	9	11
Anterior visceral space	4	6	10
Sublingual space	3	3	6
Retropharyngeal space	18	3	21
Submental space and floor of mouth	4	12	16
Prevertebral space	3	0	3
<b>Total</b>	<b>85</b>	<b>53</b>	<b>138</b>

**Table 6** Bacteriology of the DNSI cases

Organisms	No. of cases	Percentage (%)
Gram positive aerobic streptococci	56	40.6
E. Coli	44	31.9
Proteus	14	10.1
Anaerobic streptococci	8	5.6
Staph. Aureus	5	3.6
Anaerobic bacteriae	11	8

**Table 7** Radiological findings of the DNSI cases

Space involved	No. of cases	Plain radiography	Ct scan
Peritonsillar space	36	0	0
Parapharyngeal space	26	12 (46.2 %)	2 (7.7 %)
Retropharyngeal space	21	21 (100 %)	7 (33.3 %)
Submandibular space	9	0	4 (44.4 %)
Parotid space	11	0	3 (27.3 %)
Submental space and floor of mouth	16	0	0
Prevertebral space	3	0	3 (100 %)

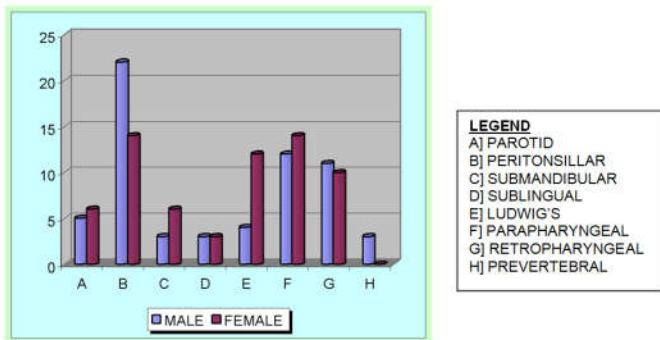
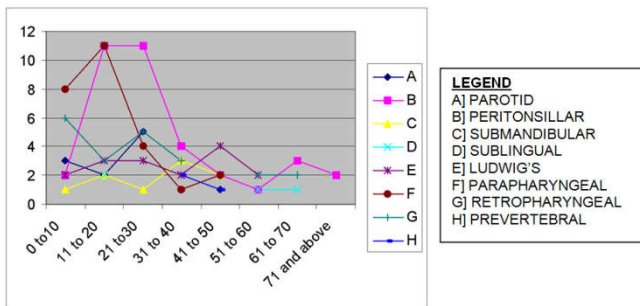
Sublingual space	6	0	0
Anterior visceral space	10	6 (60%)	4 (40%)

**Table 8** Complications at presentation of the DNSI cases

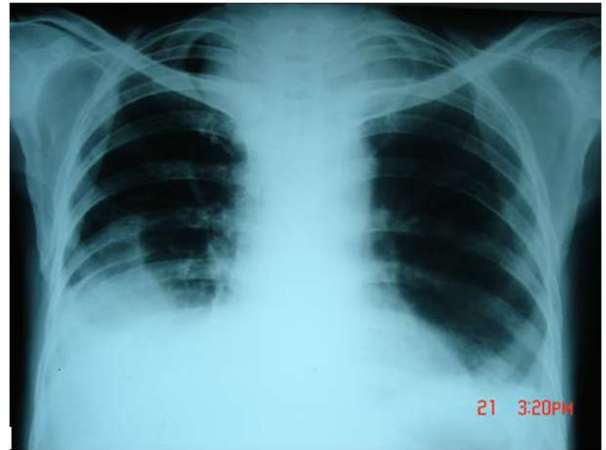
Complications	No. of cases	Percentage (%)
Airway obstruction	23	16.7
Pneumonia	16	11.6
Septicemia	11	8
Descending mediastinitis	2	1.4
Jugular vein thrombosis	1	0.7
<b>Total</b>	<b>53</b>	<b>38.4</b>

**Table 9** Management of the DNSI cases

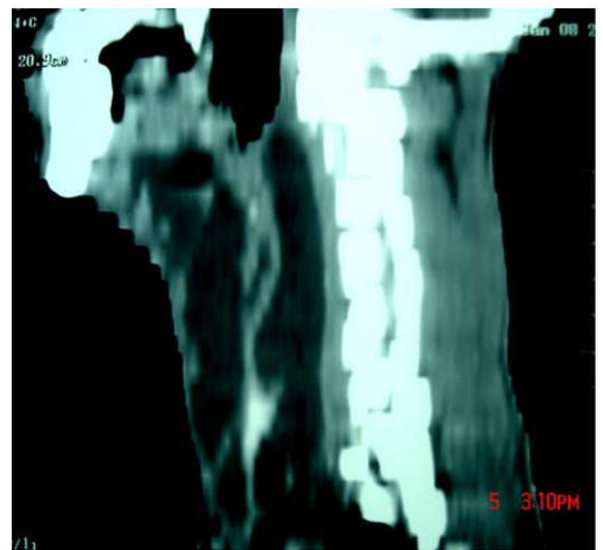
Type of infection	Surgery	Conservative	No. of cases
Parotid	8 (72.7%)	3 (27.3%)	11
Peritonsillar	31 (86.1%)	5 (13.9%)	36
Submandibular	7 (77.8%)	2 (22.2%)	9
Sublingual	4 (66.7%)	2 (33.3%)	6
Ludwig's angina	3 (18.75%)	13 (81.25%)	16
Parapharyngeal	21 (80.8%)	5 (19.2%)	26
Retropharyngeal	18 (85.7%)	3 (14.3%)	21
Prevertebral	3 (100%)	0	3
Anterior visceral	7 (70%)	3 (30%)	10
<b>Total</b>	<b>102 (73.9%)</b>	<b>36 (26.1%)</b>	<b>138</b>



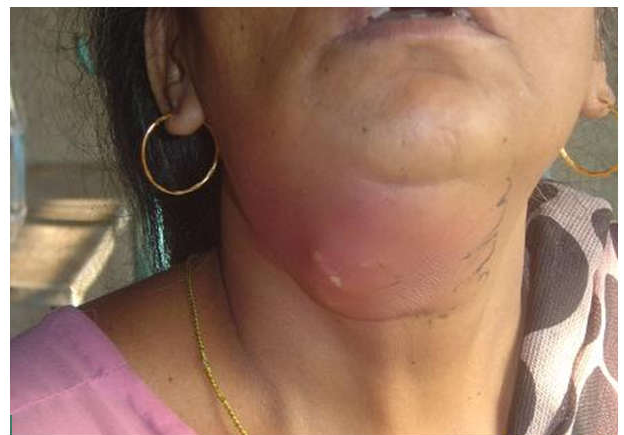**Figure 3** Parapharyngeal abscess (Axial CT scan).



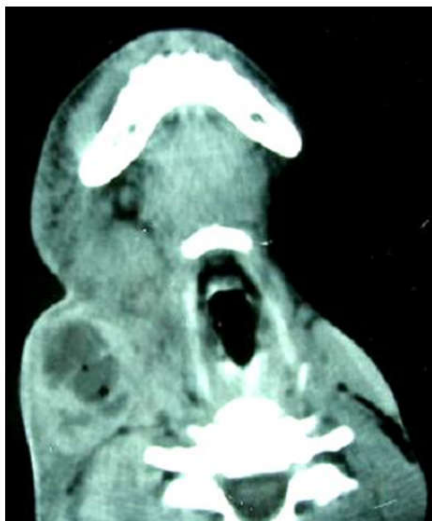**Figure 4** Prevertebral abscess with mediastinal widening



**Figure 5** Prevertebral abscess (3D reconstructed sagittal CT scan)



**Figure 6** Ludwig's angina



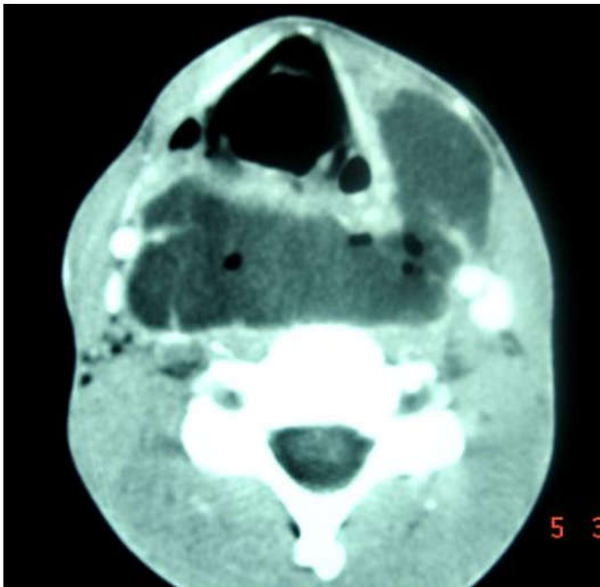


Figure 7 Retropharyngeal and parapharyngeal abscess (Axial CT scan).

## DISCUSSION

Although the advent of antibiotics and improved dental care has decreased the incidence and mortality rate, deep neck infections (DNSIs) are not uncommon and present a challenging problem due to the complex anatomy and potentially lethal complications that may arise.

The superficial and specially the 3 layered deep cervical fascia wraps the neck and its vital structures and divides the neck into a number of potential spaces known as the deep neck spaces. These spaces are prone to infection due to nearby location of infective foci and readily forms abscess cavity with multitude of life-threatening complications like airway obstruction, rupture of great vessels, mediastinitis, visceral spread of the infection into vital organs through the Lincoln's Highway etc. Slight male preponderance was observed in some series of deep neck space infection<sup>1,2</sup> though in our study both sexes were found to be equally affected, however females are more likely to develop complicated deep neck space infection.

The mean age of our patients was 32.2 +/- 18.7 years, the range being from 3 months to 77 years. However majority of the patients were within the age-group of 20 to 40 years. The mean age and the range of age of the patients of DNSI have been found to be different in different studies; Boscolo-Rizzo *et al* (2006) reported in their study a mean age of 49.6 +/- 20.4 years (range: 2-96 years).<sup>2</sup>

Liu *et al* (2004) found both peritonsillar (24.3 %) and parapharyngeal space infections (24.3 %) were the most common, followed by submandibular space infections (18.9 %) in their study of 30 patients.<sup>3</sup> Huang *et al* (2004) reported parapharyngeal space infection to be the most common type of DNSI in their study,<sup>1</sup> whereas Sakaguchi *et al* found 72 (79.1 %) cases of peritonsillar abscess patients in their series of total 91 DNSI cases.<sup>4</sup> In our series too, we found peritonsillar space infection cases to be the most frequent (26.1 %). Next most common were the para-pharyngeal and retropharyngeal abscesses respectively.

The common clinical presentation of the patients are pain, fever, dysphagia, odynophagia, torticollis, tender external swelling of the neck depending upon the compartment

affected, hot potato' voice (in Ludwig's angina & peritonsillar abscess), trismus etc. Very advanced cases presented with respiratory distress and other systemic symptoms.

Dental infections were the most common etiological factor found followed by other causes like foreign body, trauma instrumentation, local infective foci (like chronic tonsillitis, adenoids, lymphadenitis), tuberculosis, intravenous drug abuse, etc. Larawin *et al.* (2006) noted similar observations (60% cases with odontogenic origin).<sup>5</sup> In another series, Villarín *et al* (2006) also found dental infections to be the commonest etiological factor.<sup>6</sup> Parhiscar & Har-El reported intravenous drug abuse to be the second most common cause of DNSI in their study followed by odontogenic infections.<sup>7</sup>

Ludwig's angina occurs when an odontogenic infection spreads bilaterally to the submental, sublingual, and submandibular spaces. It is a rapidly spreading cellulitis caused by streptococci that causes severe swelling, displacement of the tongue, and a hard induration of the submandibular space. Patients may present with difficulty breathing, swallowing, anxiety, and trismus. The rapid progression of this infection can cause upper airway obstruction, which could lead to mortality.

The most common source of infections in para-pharyngeal space is extension from surrounding tissue, although infections after penetrating trauma also occur. The para-pharyngeal space contains the carotid sheath, the cervical sympathetic trunk, and Cranial Nerves (IX-XII). Infections of the anterior part of this space, which contains only fatty tissue, are manifested by pain, dysphagia, and trismus. Infections of the posterior compartment of this space, although typically much less symptomatic, are potentially much more catastrophic because the vital structures are involved. Physicians frequently miss infections in this area because fever can be the only symptom at presentation

Radiology played a pivotal role in the definitive diagnosis particularly the deep space affections. Imaging helps in defining boundaries of abscess, involvement of great vessels, venous thrombosis, tracheal compression and mediastinal spread. Plain radiogram of soft tissue of neck is useful in delineating retropharyngeal abscess. Increased soft tissue shadow in retropharyngeal space, air-fluid level within the abscess and absence of normal cervical lordosis points to the diagnosis. Measurement of retropharyngeal space more than 7 mm in children and adults and retro-tracheal space 14 mm in children and 22 mm in adults are suggestive of pathological process. CT scan is essential for para-pharyngeal abscess, prevertebral and anterior visceral space involvement. Both CT and MRI provide high-resolution images of head and neck compartments. However, CT is more readily available, less expensive, and less time-consuming than MRI, and it is invaluable in the initial evaluation of DNSIs. The presence of an enhancing rim around a non-enhancing central density differentiates cellulites from an abscess. Infections of the parapharyngeal and retropharyngeal spaces that may erode into the carotid sheath will be detected only with computed tomography. If erosion is suspected, angiography is indicated. Bacteriological diagnosis of DNSI varies from series to series and depends upon the previous antibiotic therapy before presenting to tertiary care institution. Reqa *et al* reported the presence of gram-positive bacteria in 63.5 % of the cases; the most common bacteria being viridans streptococci.<sup>8</sup> 34.3 % of

the causative organism in their study were anaerobic in nature. We also found aerobic streptococci to be the predominant bacteria (40.6 %) followed by *E. coli*. However the frequency of anaerobic infection was much less (7.8 %) in our series. Boscolo-Rizzo *et al* reported that Coagulase-negative staphylococcus (36.9 %) was the most common organisms, followed by *Streptococcus viridans* (28.8 %).<sup>2</sup>

Regarding management of these patients, all cases with frank abscess need surgical drainage preferably under general anaesthesia; patients presenting at the initial stages without abscess formation treated with broad-spectrum intravenous antibiotic therapy. In the last few years, some authors have proposed antibiotic therapy alone or needle aspiration as an alternative to surgical incision and drainage in cases of small abscesses.<sup>9</sup> We did surgical drainage in 102 patients (73.9 %), however only 3 (18.75 %) cases of Ludwig's angina needed surgical intervention. The choice between external and intraoral approach mainly depends on the site of the abscess and its relationship with the great vessels of the neck. It is generally accepted that retropharyngeal abscesses can be safely drained intraorally. Some authors consider an intraoral approach as a reasonable initial method of management also for lateral pharyngeal space abscesses, if CT scan shows the abscess to be medial to the great vessels of the neck. The intraoral approach is simpler, less aggressive (no risk of keloids and of injury to the marginal mandibular nerve) and it requires shorter recovery time than external approach. Surgical drainage remains the mainstay of therapy in our set-up where patients present late at advanced stages with fatal complications. In advanced countries too, surgery is the commoner treatment option as reported by Villarin *et al* (2006).<sup>4</sup>

Although deep neck infections are increasingly less frequent than they were in the past, they are still associated with significant morbidity and mortality rates as high as 40–50 %.<sup>10</sup> Infections of the deep fascial spaces of the neck are ominous because of the propensity of bacteria to spread hematogenously and contiguously along the fascial planes to involve the anterior mediastinum, pleuropulmonary spaces, retropharyngeal space, prevertebral spaces, "danger" space, and the heart valves.

Associated systemic diseases ( $p < 0.001$ ), particularly diabetes mellitus, multiple-space involvement ( $p < 0.001$ ) and anterior visceral space involvement ( $p < 0.001$ ), were the most strongly associated factors with regard to the development of complications. As reported by other authors, also in this series diabetes mellitus was the most common associated systemic disease.<sup>9,11</sup> Furthermore, diabetic patients tend to have life-threatening complications more frequently. This may indicate that patients with diabetes mellitus are particularly susceptible to DNSIs. Female patients, patients with neck swelling, and patients with respiratory difficulty were more likely to have complicated deep neck infections.

Emergency life-saving interference, particularly tracheostomy specially is needed in quite a few cases (23 cases, 16.7 %). Larawin *et al* (2006) reported that 8.7 % of their patients required tracheostomy.<sup>5</sup>

Neglected deep neck space infection still constitute a significant cause of death and an earlier report from the same institution showed 20% mortality in DNSI among the non-neoplastic causes of death.<sup>11</sup> 7 patients (5.1 %) of our series died of complications but such high mortality rate in these

cases is not very unusual as has been reported by Larawin *et al* (2006) in their series too (8.7% mortality).<sup>5</sup>

## CONCLUSION

Our study showed us that time was the most important factor governing the outcome of DNSI cases – early and accurate diagnosis and timely referral from the peripheral health set up is essential because it is there where most of the patients present first. In all the cases airway, breathing and circulation should be assessed and attended to if required. Surgical drainage is the management modality and there is no scope of empirical antibiotic therapy in presence of abscess. These simple steps will go a long way in saving the lives of these patients.

## References

1. Huang TT, Liu TC, Chen PR, Tseng FY, Yeh TH, Chen YS. Deep neck infection: analysis of 185 cases Head Neck. 2004 Oct; 26 (10): 854-60.
2. Boscolo-Rizzo P, Marcher C, Montello F, Vigil A, Da Mosto MC. Deep neck infections: a constant challenge. ORL J Otorhinolaryngol Relat Spec. 2006; 68 (5): 259-65.
3. Liu CH, Lin CD, Cheng YK, Lin HC, Tsai MH. Deep neck infection in children. Acta Paediatrica Taiwanica, 2004; 45 (5) 265-8.
4. Sakaguchi M, Sato S, Ishiyama T, Katsuno S, Taguchi K. Characterization and management of deep neck infections. Int J Oral Maxillofac Surg. 1997 Apr; 26 (2): 131-4.
5. Larawin V, Naipao J, Dubey SP. Head and neck space infections. Otolaryngol Head Neck Surg. 2006 Dec; 135 (6): 889-93.
6. Villarin RS, Barro VJC, Gonzalez-Botas HJ - Deep neck infections: etiology, bacteriology and treatment. Acta Otorrinolaringol Esp. 2006 Aug-Sep; 57 (7): 324-8.
7. Parhiscar A, Har-El G. Deep neck abscess: a retrospective review of 210 cases. Ann Otol Rhinol Laryngol. 2001 Nov; 110 (11): 1051-4.
8. Rega AJ, Aziz SR, Ziccardi VB. Microbiology and antibiotic sensitivities of head and neck space infections of odontogenic origin. J Oral Maxillofac Surg. 2006 Sep; 64 (9): 1377-80.
9. Wang LF, Kuo WR, Tsai SM, Huang KJ: Characterizations of life-threatening deep cervical space infections: a review of one hundred ninety-six cases. Am J Otolaryngol 2003; 24: 111–7.
10. Bottin R, Marioni G, Rinaldi R, Boninsegna M, Salvatori L, Staffieri A. Deep neck infection: a present-day complication. A retrospective review of 83 cases (1998–2001). Eur Arch Otorhinolaryngol 2003, 260:576-9.
11. Saha S, Mishra S, Mondal AR, Gupta A, Nandy TK: Mortality audit in otolaryngology- A Kolkata based hospital study. Indian journal of Otolaryngology and Head Neck surgery 2005, 57 (3): 185-8.
12. Beasley DJ, Amedee RG. Deep neck space infections. J La State Med Soc. 1995 May; 147 (5): 181-4.
13. Stalfors J, Adielsson A, Ebenfelt A, Nethander G, Westin T. Deep neck space infections remain a surgical challenge. A study of 72 patients. Acta Otolaryngol. 2004 Dec; 124 (10): 1191-6.
14. Brook I. Microbiology and management of deep facial infections and Lemierre syndrome. ORL J Otorhinolaryngol Relat Spec. 2003 Mar-Apr; 65 (2): 117-20.