



**CRANIOFACIAL MANIFESTATION IN ACHONDROPLASIA-A CASE REPORT
AND LITERATURE REVIEW**

Saraswathi Gopal K¹ and Priyam Kapoor*²

¹Professor and Head, Department of Oral Medicine and Radiology, Faculty of Dentistry,
Meenakshi Ammal Dental College, Chennai

²Postgraduate, Department of Oral Medicine and Radiology, Meenakshi Ammal Dental College, Chennai

ARTICLE INFO

Article History:

Received 13th December, 2018

Received in revised form 11th

January, 2019

Accepted 8th February, 2019

Published online 28th March, 2019

ABSTRACT

Achondroplasia is a common form of chondrodysplasia and autosomal dominant disorder. It has characteristic disproportionate short stature with craniofacial features such as macrocephaly, depressed nasal bridge and mid-facial hypoplasia. Here, we present a case of a 30 year old male with achondroplasia which emphasis on the craniofacial and dental manifestations.

Key words:

Achondroplasia, autosomal dominant,
craniofacial manifestation, dental

Copyright©2019 Saraswathi Gopal K and Priyam Kapoor. This is an open access article distributed under the Creative Commons Attribution License, which permits unrestricted use, distribution, and reproduction in any medium, provided the original work is properly cited.

INTRODUCTION

In 1878, Jules Parrot first used the term “achondroplasia” and later the main features were explained by Pierre Marie in 1900.^[1] Achondroplasia is a congenital genetic disorder and one of the most common form of dwarfism. It is an autosomal dominant disorder and occurs due to a mutation in the gene coding fibroblast growth factor receptor-3 (FGFR-3).^[2,3,4] It results in abnormal cartilage formation and disturbance in cartilage mediated bone formation or endochondral ossification. It is also known as chondrodystopia fetalis and a non-lethal form of chondrodysplasia. The characteristic features are disproportionate short stature, rhizomelic shortening of extremities, thoracolumbar kyphosis, trident configuration of hands, genu varum and lumbar hyperlordosis.^[5,6] Craniofacial manifestations include macrocephaly, depressed nasal bridge, frontal bossing, hypoplasia of maxilla, relatively large mandible.^[7,8,9] Here, we report a case presentation of 30year old male with achondroplasia with review of literature

Case Report

A 30 year old male patient born to non-consanguineous parents reported to the Department of Oral Medicine and Radiology with a chief complaint of a decayed tooth in his upper front teeth region for the past five months. The patient gives a history of sensitivity to cold and hot food and beverages in the decayed tooth. Patient has two elder siblings, a brother and a sister, who are apparently normal.

***Corresponding author: Priyam Kapoor**

Postgraduate, Department of Oral Medicine and Radiology,
Meenakshi Ammal Dental College, Chennai

There was no history of the similar family condition. The mother had a full term pregnancy and the patient was a normal delivery child. The medical history revealed that he was born with hydrocephaly and started walking after 10years of age. This was the first dental visit of the patient. This patient appeared to be well adjusted, healthy, intelligent. The patient had a short stature (111cm tall), spacing between ring and middle finger and bowing of knees. [Figure - 1, 2 and 3 depicts the profile, hands and feet picture respectively] The extra-oral examination revealed short stature, large head, frontal bossing, mid-face hypoplasia and relatively prognathic mandible. [Figure - 4 depicts the lateral view of the patient] Intra-oral examination revealed complete permanent dentition with root stump in relation to 21, 36, 37, 47 and dental caries in relation to 14, 17, 18, 22, 26, 27,46. There were generalized stains and calculus with cervical abrasion in relation to 14,15,24,25,34,35,44 and 45. [Figure – 5 depicts the intra-oral picture]. The patient underwent extraction of root stump in relation to 21, After a week, the patient was subjected to the following radiological investigations: panoramic radiograph, lateral cephalometric, chest x-ray, hand and wrist and spinal radiograph. Panoramic radiograph showed permanent dentition and missing 21 (extracted 21). There was a generalized crestal bone loss in the maxillary and mandibular arch and root stumps in relation to 36, 37 and 47. [Figure – 6 depicts the Orthopantomogram] The lateral cephalometric radiograph revealed a depressed nasal bridge, hypoplastic maxilla with normal mandible and proclined maxillary and mandibular anterior teeth. [Figure – 7 depicts the lateral cephalometric] Chest X-ray examination revealed flared ribs and widening of space between ribs. [Figure – 8 depicts the Chest X-ray] Hand

and wrist radiographs showed trident hand configuration. [Figure – 9 depicts the Hand and wrist X-ray] The radiograph of spine revealed scalloping of lumbar vertebrae compared to thoracic vertebrae (lumbar hyperlordosis). [Figure – 10 depicts the Lateral Spinal X-ray] Based on the history, clinical examination and radiological investigations, the final diagnosis arrived at achondroplasia. The patient was subjected to oral prophylaxis, restoration of decayed teeth, extraction of root stumps followed by replacement of missing teeth



Figure 1 Profile picture of the patient

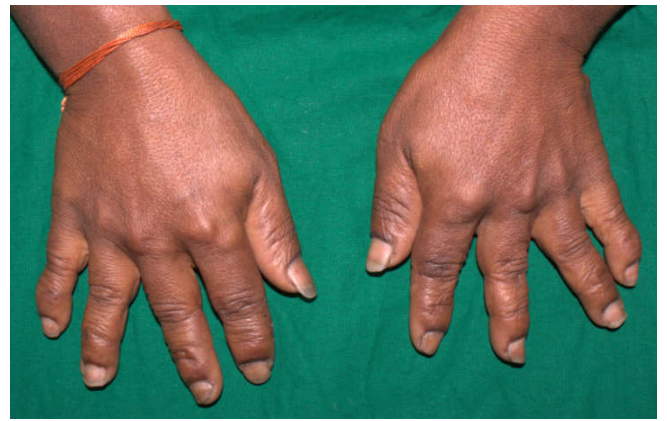

Figure 2 Hands of the patient

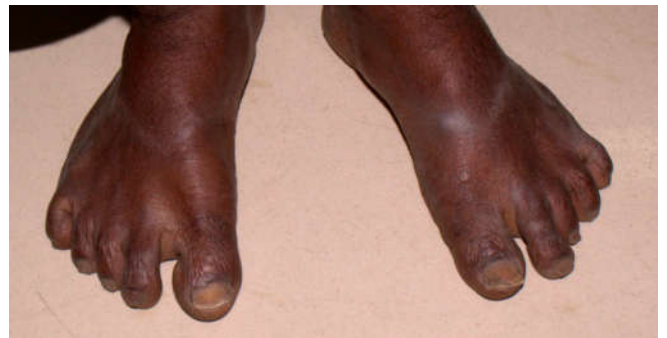

Figure 3 Feet of the patient

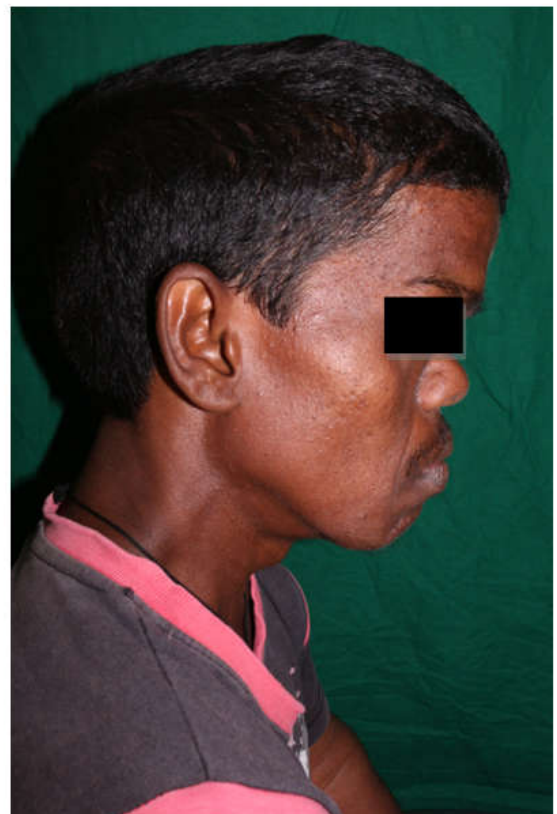

Figure 4 Lateral view of the patient

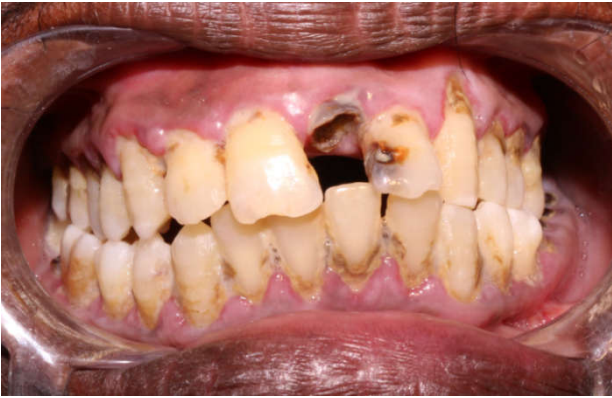

Figure 5 Intra-oral picture

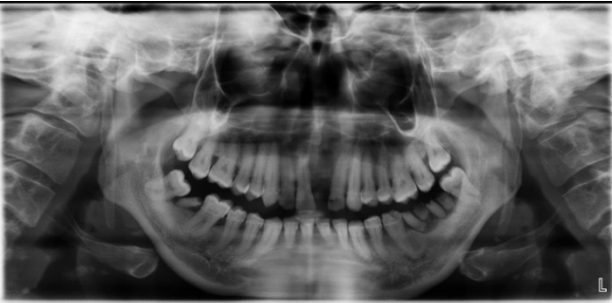

Figure 6 Orthopantomogram (AFTER EXTRACTION)

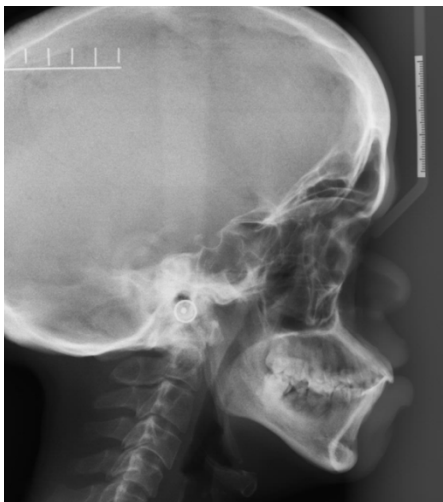


Figure 7 Lateral Cephalometric

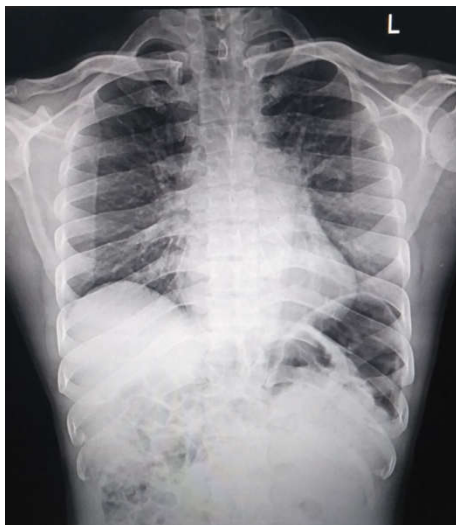

Figure 8 Chest X-ray

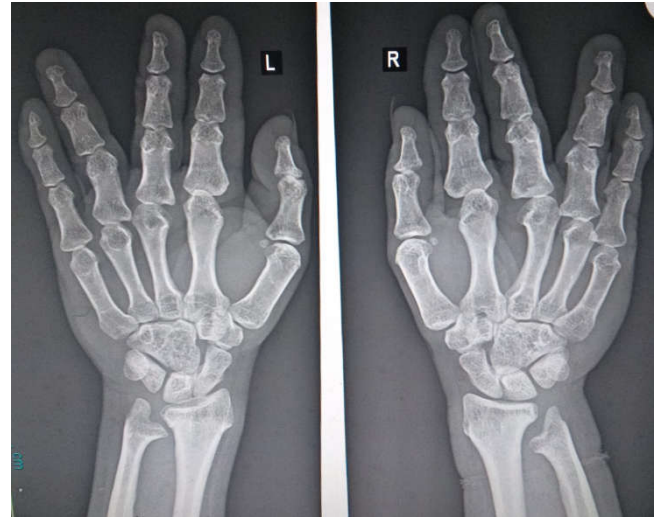

Figure 9 Hand and wrist X-ray

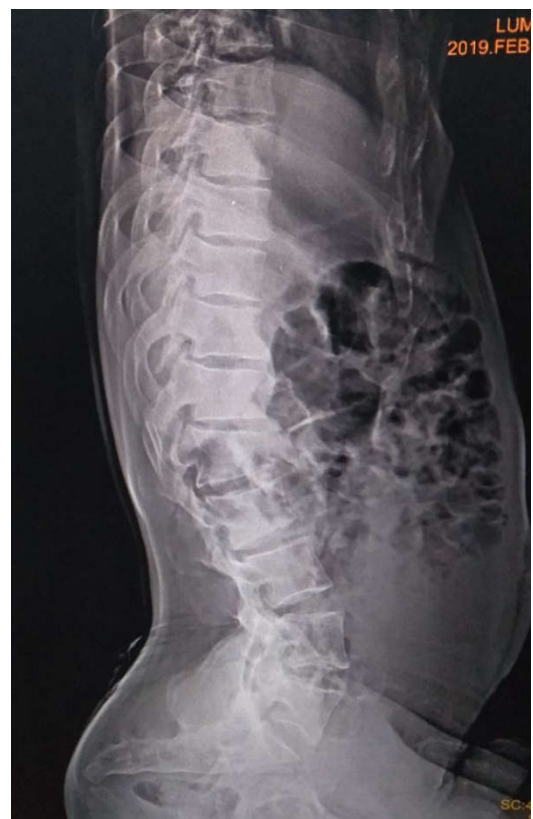

Figure 10 Lateral Spinal X-ray

DISCUSSION

Achondroplasia is the most common non-lethal form of skeletal dysplasia with a prevalence of 1:10,000 to 1:50,000 live births.^[10] The recorded 80% of cases are sporadic which occur due to de-novo mutation of the gene for fibroblast growth factor receptor-3 on chromosome 4. The remaining 20% of cases are familial with autosomal dominant pattern of inheritance. The genetic defect leads to reduced functional growth factor receptor-3. It results in a decrease in endochondral ossification, inhibited proliferation of chondrocytes in growth plate cartilage, decreased cellular hypertrophy and decreased cartilage matrix production. The homozygous form is life-threatening within the first few months of life due to respiratory insufficiency caused by

severe rib cage deformity. But in the heterozygous state, the child has a normal life span and intelligence quotient.^[7,8,11,12]

If an individual affected with achondroplasia has a normal stature partner, then there is a 50% chance of the offspring to be affected. If both the parents are affected then there is 25% chance of homozygous offspring and 50% chance of heterozygous offspring.

There are no clinical diagnostic criteria known, but characteristic clinical and radiographic features have been established. Most of the cases are diagnosed in early infancy by short limbs especially the proximal segment, long trunk and narrow thorax. The affected cases have delayed early motor milestones due to muscular hypotonia and normal psychomotor development.^[1,3] In children and adults, the clinical features noted are short stature, macrocephaly with frontal bossing, midface retrusion, depressed nasal bridge, rhizomelic shortening of arms, limitation of elbow extension, trident configuration of hands, genu varum, thoracolumbar kyphosis and The present case also had the following features, short stature, frontal bossing, hypoplastic midface, depressed nasal bridge, trident configuration of hands, genu varum and lumbar hyperlordosis.^[6] The Chest X-ray findings are anterior flaring of ribs. Spinal radiographs reveal posterior vertebral scalloping, thoracolumbar kyphosis and widening of the intervertebral disc. Pelvis radiograph shows champagne glass type pelvic inlet. Hand and wrist radiograph show trident configuration i.e. separation between middle finger and ring finger. Computed tomography shows large cranial vault and skull base, narrow foramen magnum, prominent forehead and depressed nasal bridge.^[1] The dental manifestations are skeletal or dental Class III malocclusion, cross-bite, anterior open bite, narrow maxilla and macroglossia.^[9,10,13]

CONCLUSION

The clinical report describes the characteristic features of achondroplasia and dental findings such as poor oral hygiene and multiple carious teeth. Thus, a patient with achondroplasia not only requires medical management but also a special emphasis on the definitive dental management of the patient is required.

Declaration of the Patient

The authors certify that they have obtained all appropriate patient consent forms. In the form the patient(s) has/have given his/her/their consent for his/her/their images and other clinical information to be reported in the journal. The patient understand that their names and initials will not be published and due efforts will be made to conceal their identity, but anonymity cannot be guaranteed.

References

1. Baujat G, Legeai-Mallet L, Finidori G, Cormier-Daire V, Le Merrer M. Achondroplasia. *Best Practice & Research Clinical Rheumatology*. 2008 Mar 1;22(1):3-18.
2. Ornitz DM, Legeai-Mallet L. Achondroplasia: development, pathogenesis, and therapy. *Developmental Dynamics*. 2017 Apr; 246 (4):291-309.
3. Pauli RM. Achondroplasia: a comprehensive clinical review. *Orphanet journal of rare diseases*. 2019 Dec; 14 (1):1.
4. Horton WA, Hall JG, Hecht JT. Achondroplasia. *The Lancet*. 2007 Jul 14; 370 (9582):162-72.
5. Langer JR LO, Baumann PA, Gorlin RJ. Achondroplasia: clinical radiologic features with comment on genetic implications. *Clinical pediatrics*. 1968 Aug;7 (8):474-85.
6. Pauli RM, Legare JM. Achondroplasia. In *Gene Reviews®* [Internet] 2018 May 10. University of Washington, Seattle.
7. Bhagde P, Patil P, Agrawal A, Vakharia S. An Unusual Presentation of An Achondroplastic Patient—with Stress on The Pathogenesis of The Craniofacial Manifestations.
8. Frank C, Shariff S, Pavani M, Karthika B, Thathekalva S. Achondroplasia with Polydactyly: A Case Report. *Journal of clinical and diagnostic research: JCDR*. 2017 Mar; 11(3): ZD14.
9. Al-Saleem A, Al-Jobair A. Achondroplasia: Craniofacial manifestations and considerations in dental management. *The Saudi dental journal*. 2010 Oct 1;22(4):195-9.
10. Chawla K, Lamba AK, Faraz F, Tandon S. Achondroplasia and periodontal disease. *Journal of Indian Society of Periodontology*. 2012 Jan;16(1):138.
11. Celenk P, Arici S, Celenk C. Oral findings in a typical case of achondroplasia. *Journal of international medical research*. 2003 Jun;31(3):236-8.
12. Rohilla S, Kaushik A, Vinod VC, Tanwar R, Kumar M. Orofacial manifestations of achondroplasia. *EXCLI journal*. 2012; 11:538.
13. Raviraj J, Suman V, Suresh D, Kartik K. Achondroplasia with multiple supplemental supernumerary teeth and multiple talon cusps: A rare case report. *Dental research journal*. 2017 May; 14(3):219.

How to cite this article:

Saraswathi Gopal K and Priyam Kapoor (2019) 'Craniofacial Manifestation in Achondroplasia – A Case Report and Literature Review', *International Journal of Current Advanced Research*, 08(03), pp. 17913-17916.
DOI: <http://dx.doi.org/10.24327/ijcar.2019.17916.3414>
