



## OUTCOME OF SINGLE STAGE REPAIR FOR DIFFERENT VARIANTS OF HYPOSPADIAS

Rajnish kumar, Pankaj Raj, Prem Prakash and Priyankar Singh

Department of General Surgery, Indira Gandhi institute of medical sciences, seikhpura Patna, Bihar, India

### ARTICLE INFO

**Article History:**

Received 6<sup>th</sup> November, 2018

Received in revised form 15<sup>th</sup> December, 2018

Accepted 12<sup>th</sup> January, 2018

Published online 28<sup>th</sup> February, 2019

**Key words:**

Single-stage repair, Hypospadias, MAGPI, Snodgrass TIP

### ABSTRACT

Hypospadias (hi-poe-SPAY-dee-us) is a birth defect (congenital condition) in which the opening of the urethra is on the underside of the penis instead of at the tip. Hypospadias is a relatively common congenital defect of the male external genitalia. It is present in approximately 1 in 250 male newborns. Hypospadias in boys, include three anomalies of the penis: an abnormal ventral opening of the urethral meatus that may be located anywhere from the ventral aspect of the glans penis to the perineum, an abnormal ventral curvature of the penis known as chordee, and an abnormal distribution of foreskin present dorsally and deficient foreskin ventrally known as hood.

**Methods & Material:** In this study author operated 25 cases of Hypospadias of different types in different age groups. MAGPI for glandular variety, TIP procedure for distal penile hypospadias and Duckett Onlay Flap technique for Proximal penile hypospadias, penoscrotal and perineal Hypospadias. Crippled Hypospadias was repaired by bracka two stage technique.

**Results and Analysis:** After the primary repair of Hypospadias fistula was found in 6.2% of patients. Post-operative hemorrhages was seen in 12.2% of patients. The success rate of Crippled Hypospadias was quite satisfactory. Over All study has shown better cosmetic results, one stage repair is cost effective, satisfactory and less psychologically affecting patient and attendants.

**Conclusions:** MAGPI performed for the repair for Glandular and TIP for distal penile in cases of mild chordee. Proximal Penile Chordee corrected by dorsal plication and Urethroplasty by Duckett's Onlay flap technique. Snodgrass TIP performed for mid penile and distal penile with satisfactory outcome. This protocol appeared very cost effective. Single stage repair is also beneficial for developing countries like India where the follow-up compliance in the rural patients is extremely poor.

Copyright©2019 Rajnish kumar et al. This is an open access article distributed under the Creative Commons Attribution License, which permits unrestricted use, distribution, and reproduction in any medium, provided the original work is properly cited.

### INTRODUCTION

**Hypospadias** (hi-poe-SPAY-dee-us) is a birth defect (congenital condition) in which the opening of the urethra is on the underside of the penis instead of at the tip. Hypospadias is a relatively common congenital defect of the male external genitalia. It is present in approximately 1 in 250 male newborns. Hypospadias in boys, include three anomalies of the penis: an abnormal ventral opening of the urethral meatus that may be located anywhere from the ventral aspect of the glans penis to the perineum, an abnormal ventral curvature of the penis known as chordee, and an abnormal distribution of foreskin present dorsally and deficient foreskin ventrally known as hood. Meatal position remains the most commonly used criterion for classification of the types of Hypospadias. Glandular, coronal, and subcoronal defects constitute the great majority (50% to 70%) of hypospadias. Duckett has reported overall rates of approximately 50%, 30%, and 20% for distal

penoscrotal, middle, and posterior/proximal hypospadias, respectively.

#### Pre-Operative Evaluation

Pre-operative evaluation of the child is required to rule out presence of associated abnormalities and plan of surgery accordingly. Associated abnormalities include cryptorchidism (7% to 9%) and inguinal hernia (9%) and/or hydrocele (16%). It was found that the prevalence of inguinal hernia was similar in anterior, mid, and posterior hypospadias but cryptorchidism was predominant in boys with posterior defects. Approximately 15% of individuals with hypospadias and bilateral cryptorchidism will have an intersex condition. Approximately 50% of individuals with hypospadias and a unilateral cryptorchidism will have an intersex condition.

### METHODS AND MATERIAL

#### Age

Although the best time for surgery for hypospadias is between 6 and 12 months of age, but all patients were evaluated and included in to the study. Surgery was performed on the

\*Corresponding author: **Rajnish kumar**

Department of General Surgery, Indira Gandhi institute of medical sciences, seikhpura Patna, Bihar, India

different age groups of children with number of cases (0-12 years-25 cases). General anesthesia, typically with endotracheal intubation.

### General Principles of Repair

- Penile curvature and its correction (Orthoplasty)
- Neo-urethra formation (Urethroplasty)
- Repair of meatus (Meatoplasty)
- Repair of Glans (Glanuloplasty) and
- Skin coverage

### Surgery

The purpose of single stage hypospadias repair is to achieve cosmetic and functional restoration both.<sup>1</sup>In this research all Hypospadias variants were uniformly repaired by single stage repair. In cases of meatal and Coronal type no Chordee correction was not required. other variants which required chordee correction, It was done by dissection of urethral plate and neourethraformation from penoscrotal skin and dorsal plication of tunica albuginea by using Figure of 8 stitches. For glandular Hypospadias MAGPI (Meatal Advancement and glanuloplasty Incorporated) and for Coronal and Distal penile hypospadias Snodgrass TIP was done<sup>2</sup>. Standard surgical protocol followed in surgical steps.

### RESULTS AND ANALYSIS

Depending on follow up compliance, the patients were followed from a minimum of 2months to a maximum of 3years. The protocol author used included 4 weekly intervals for the first 3 months then 6 weekly for 6 months and then yearly follow-up for development of meatal stenosis, urethrocuteaneous fistula, hemorrhages, tubal blockage and residual chordee.

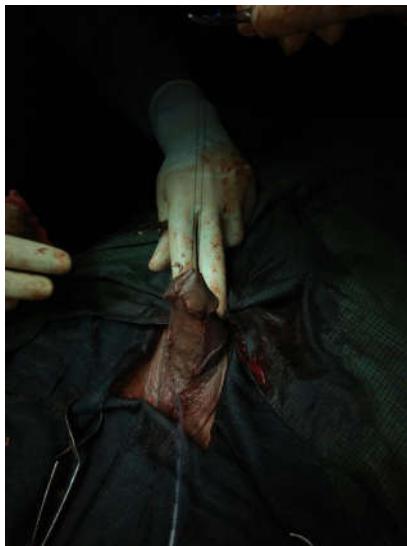


Figure 1

### Findings were

as follow: - During the follow up the following complications were found among treated patients.

- ✓ Metal stenosis 5%
- ✓ Uethrocuteaneous fistula 6.25%
- ✓ Hemorrhages 6.25%
- ✓ Tubal blockage 0%

✓ Residual chordee 8.3%

This research include different surgical techniques as described above based on the different types of Hypospadias and other anatomical variants were performed in single stage repair except in certain cases of failure & complications.

The results of this research were found highly satisfactory with successful outcome in most of the cases. Included photograph Figure1, Duckett Onlay prepucial Flap technique for Proximal penile Hypospadias. Figure2, Distal penile hypospadias. Figure, Snodgrass TIP (Tubularised incised plate procedure). (Figure 4) photograph showing the outcome of post op follow up successful repair by TIP procedure for midpenile Hypospadias (after 6 months) & Figure5, Dartos flap after uethoplasty for penoscrotal hypospadias repair.

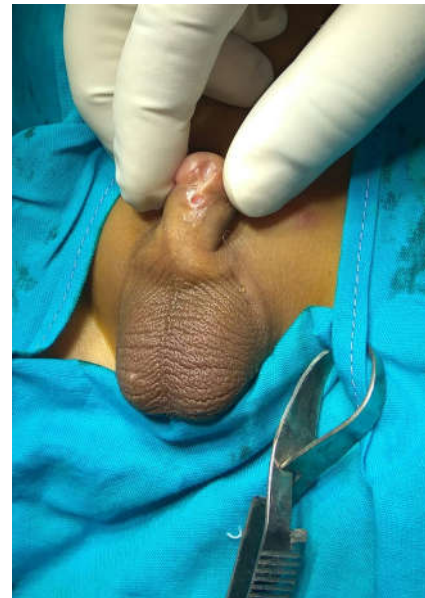

Figure 2

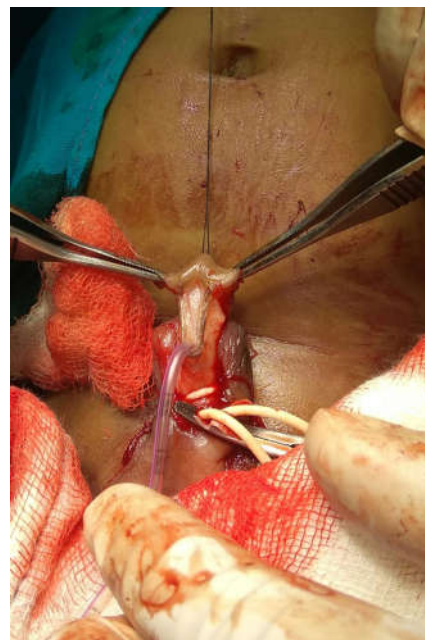


Figure 3



Figure 4

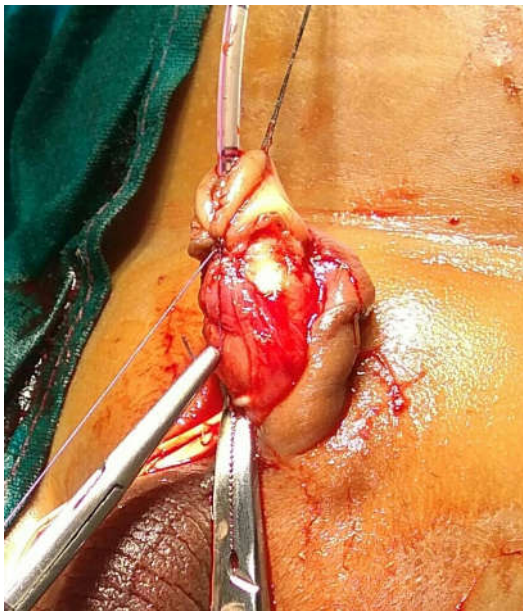


Figure 5

## DISCUSSION

The results calculated in this research found relatively comparable to the previous case series and studies done before. A previous study by Manzoni et al focused on one stage repair based on the quality and the development of the urethral plate and not on the pre-operative location of the meatus.<sup>1</sup> Complications included fistula in 9% cases, meatal stenosis or retraction in 5%, residual chordee in 3%, stricture in 2.5%, tubal abnormality in 2%, and flap necrosis in 2%. The results are comparable to this study performed in Egypt perhaps due to the similarity of the socio-economic conditions of the patients and developing nature of the economy of the countries. Another analysis of 422 cases done by Uygur MC et

al at Turkey had comparable results<sup>4</sup>. Elhalaby EA has recommended that a single staged repair can be safely and effectively performed even in patients with the most severe penoscrotal hypospadias.<sup>5</sup> The early complication rate was 18%, while the final success rate following secondary interventions was 95%. The complications included fistula formation in 12%, flap necrosis in 3%, meatal problems in 3%, residual chordee in 1%, and urethral stricture in <1%.<sup>6</sup> A case series of one stage repair performed on 544 cases by Ghali AM et al found that despite an initial overall complication rate of 19%, the final success rate was 96%.<sup>7</sup> Chandrasekharam has reported the use of LDIF (longitudinal dorsal island flap) for single-stage mid and proximal hypospadias repair with good success and an acceptable complication rate. Complications were more common after tubularized repairs than onlay repairs (24% vs. 9.5%) in cases with poorly formed urethral plate.

The outcomes of single- and multistage repairs of proximal hypospadias are comparable; no technique can be considered better than any other. Thus, it is more judicious for a hypospadiologist to master a few of these procedures to achieve the best results, regardless of the technique used.<sup>8</sup> Badawy H, et al mentioned risk factors as severe chordee, middle and posterior localized hypospadias, and use of a pedicle island flap may increase the postoperative complication rate. There is no gold-standard technique for hypospadias repair; the procedure of choice should depend on the individual anatomy of the penis.<sup>9</sup>

this study using the above-mentioned protocol in Indian states has come to the conclusions that in a developing country like India with rural patients having poor access to good healthcare facilities, single stage repair is beneficial in many ways. The follow-up compliance of poor rural patients is extremely poor because of poverty and they have to come to the urban cities for treatment. The authors have seen multiple cases of lost compliance after a decade with complications. So single stage repair provides a chance of quick recovery from the ailment with satisfactory results. It also has the advantage of lesser psychological stress to the patients and attendants. The overall duration of the Hospital Stay is also decreased, reducing the cost to patient. Hence it becomes cost-effective for the patient.

In this study author has firm believe that single stage repair for different variants of Hypospadias performed by an experienced Surgeon has better cosmetic outcome and a higher success rate.

## Acknowledgements

Authors would like to thank respective departments for contributing patient data for case series and also all the patients for participating in the study.

Ethical approval: The study was approved by the Institutional Ethics Committee

Conflict of interest: None

## References

1. Manzoni G, Bracka A, Palminteri E, Marrocco G. Hypospadias surgery: When, what and by whom? *BJU Int.* 2004; 94:1188-95.
2. Snodgrass W, Nguyen MT. Current technique of tubularized incised plate hypospadias repair. *Urol.* 2002; 60:157-62.
3. Snodgrass W. Tubularised, incised plate urethroplasty for distal hypospadias. *J Urol.* 1994; 151:464-5.

4. Nuininga J, De Gier, Verschuren, Feitz W. Long-Term Outcome of Different Types of 1-Stage Hypospadias Repair. *J Urol.* Oct 2005; 174:1544-8.
5. Uygur MC, Unal D, Tan MO, Germiyanoglu C, Erol D. Factors affecting outcome of one-stage anterior hypospadias repair: analysis of 422 cases. *Pediat Surg Int.* 2002 Mar;18(2-3):142-6.
6. Ghali AM, el-Malik EM, al-Malki T, Ibrahim AH. One-stage hypospadias repair. Experience with 544 cases. *Eur Urol.* 1999; 36(5):436-42.
7. Chandrasekharam VVS. Single-stage repair of hypospadias using longitudinal dorsal island flap: Single-surgeon experience with 102, cases. *Indian J Urol.* 2013;29(1):48-52.
8. Badawy H, Fahmy A. Single- vs. multi-stage repair of proximal hypospadias: The dilemma continues. *Arab J Urol.* 2013;11(2):174-81.
9. Ozturk H, Onen A, Otçu S, Kaya M, Ozturk H, The outcome of one-stage hypospadias repairs. *J Pediat Urol.* 2005;4(1):261-6.

**How to cite this article:**

Rasnika Amra and Shalini Agarwal (2019) 'Identifying The Bullying Behavior Among School Going Children', *International Journal of Current Advanced Research*, 08(02), pp. 17244-17247. DOI: <http://dx.doi.org/10.24327/ijcar.2019.17247.3223>

\*\*\*\*\*