

DARIER-WHITE DISEASE WITH VARIABLE PENETRANCE

Navein R K., Srivenkateswaran K., Sivasubramanian V., Sivakumar.S and KirandeePkaur Chadha

Department of Dermatology, Vinayak Missions Research Foundation (DU), Karaikal

ARTICLE INFO

Article History:

Received 6th October, 2018
Received in revised form 15th November, 2018
Accepted 12th December, 2018
Published online 28th January, 2019

ABSTRACT

Darier disease is an autosomal dominant genodermatosis with incomplete penetrance and variable expressivity. Estimated incidence is 4 per million per 10 years. Men and women are equally affected. Characteristic mucocutaneous findings such as hyperkeratotic papules preferentially in seborrheic distribution areas and longitudinal erythronychia with V shaped notches at distal edge of nail and whitish oral mucosal papules in some people. Histological features includes acantholysis and dyskeratosis (corp ronds and grains)

Key words:

Darier disease, Dyskeratosis follicularis, Acantholytic dyskeratotic disorder

Copyright©2018 Navein R K et al. This is an open access article distributed under the Creative Commons Attribution License, which permits unrestricted use, distribution, and reproduction in any medium, provided the original work is properly cited.

INTRODUCTION

Darier disease is an autosomal dominant genodermatosis with incomplete penetrance⁽¹⁾ and variable expressivity. It is also known as darier disease, dyskeratosis follicularis, keratosis follicularis. Darier disease was reported independently by darier and white in 1889⁽²⁾. It is an uncommon dermatological condition.

Prevalence of this disease is about 1:100000. Men and women are equally affected although males are more severely affected than females⁽²⁻⁴⁾. Cutaneous presentation usually starts in first and second decades of life. It is characterised by hyperkeratotic papules particularly in seborrheic distribution sites⁽⁵⁾.

The objective of this study is to report a case of darier white disease with characteristic presentation of lesions over seborrheic areas such as scalp, face, axillae, chest, retrauricular and groin areas clinically and diagnosis was established by histopathological findings.

CASE REPORT

A 49 years old female patient presented with itchy raised areas present over scalp, behind both ears, chest, axillae, groin for about 30 years reported to the department of dermatology, Vinayaka missions medical college, karaikal.

She initially noticed her lesion when she was 18 years old as pigmented dark areas over right side of forehead.

*Corresponding author: Navein R K
Department of Dermatology, Vinayak Missions Research Foundation (DU), Karaikal

Later similar lesions appeared on face, scalp, behind both ears and chest which was gradual in onset and progressive in nature to develop as multiple warty thick lesions over the scalp, face, behind both ears, chest, axillae and groin. Aggravation of symptoms on exposure to sunlight was present. Family history revealed about similar lesions present among her daughter and son (Fig.1). The patient had no history of tobacco or alcohol consumption.

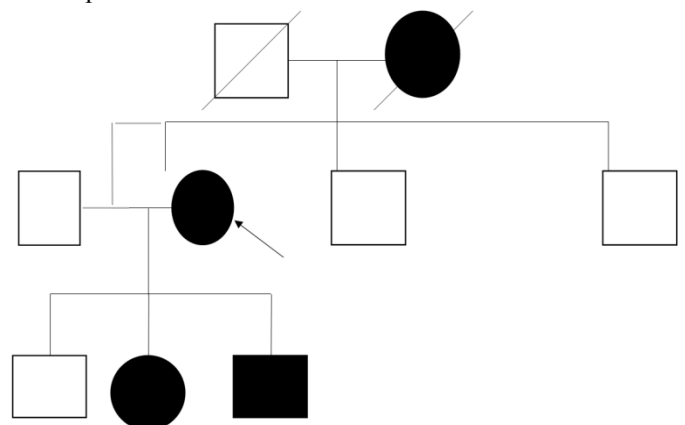


Fig 1 Pedigree chart indicating autosomal dominance among patient family members

Cutaneous examination revealed multiple hyperpigmented hyperkeratotic verrucous papules and plaques with malodour distributed diffusely over scalp, face, chest, bilateral ear and retroauricular region, bilateral axillae, bilateral inframammary fold, bilateral genitofemoral fold and labia majora (Fig 2a,2b,2c,2d). Hyperkeratotic plaques present on bilateral soles.

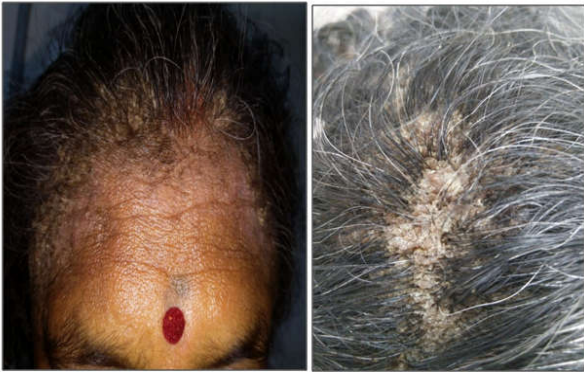

Fig 2a

Fig 2b

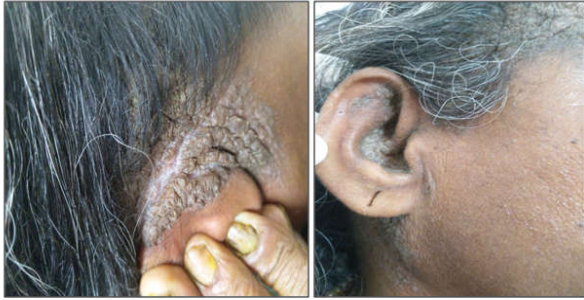

Fig 2c

Fig 2d

Fig.2a,2b,2c,2d Multiple hyperkeratotic crusted papules and plaques over the frontal area of scalp extending to forehead(2a).and over midline of scalp vertex area(2b) and retroauricular region(2c) and auricular region(2d)

Oral cavity showed few pinpoint sized white papules present over hard palate. Nail findings showed v shaped nick at distal edge. (Fig.3a and 3b)

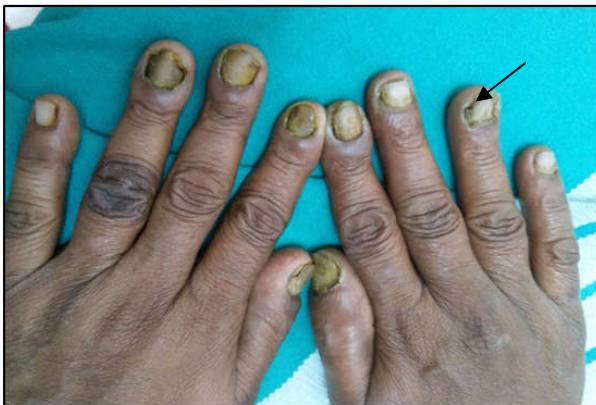

Fig 3a Nails showing V shaped notch At distal edge

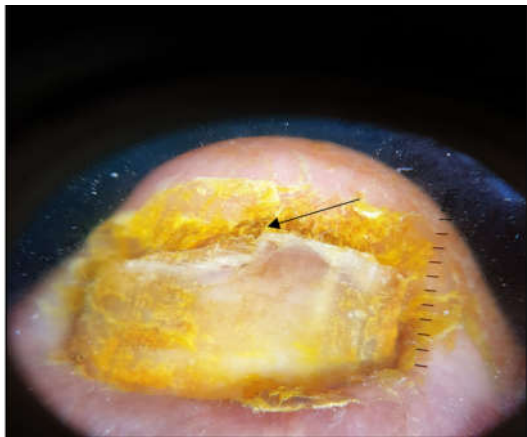


Fig 3b Dermoscopic view of nail showing V shaped notch at distal edge of nail

Complete hemogram, renal function tests, liver function tests, fasting lipid profile and blood glucose levels were within normal limits.

Skin biopsy of lesion was confirmative which was taken from right side of lower abdomen shows marked hyperkeratosis and papillomatosis and suprabasal acantholysis with formation of clefts, lacunae and villi. Many corp ronds and grains in granular epidermis layer with inflammatory infiltrate in dermis (Fig.4). She was explained about prognosis of the condition and informed consent was obtained for further management was taken. Treatment with oral retinoids (Tab. Acitretin 0.25mg/kg/day O.D.) was started and patient didn't come for follow up.

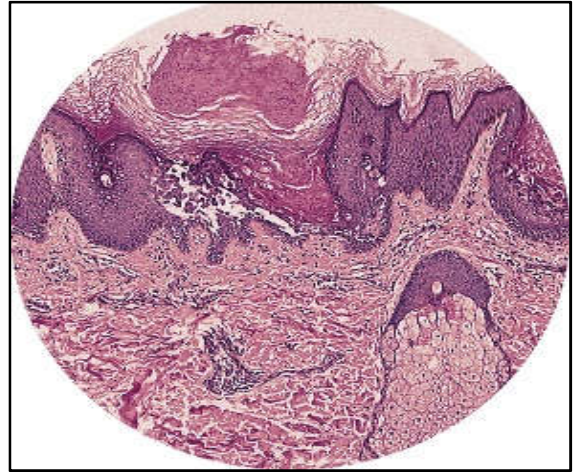


Fig 4 Histopathological picture in low power 10x magnification shows hyperkeratosis, papillomatosis, suprabasal clefts, lacunae, acantholysis and Dyskeratosis (corp ronds and grains) in epidermis; inflammatory infiltrate in dermis

DISCUSSION

Darier disease is an autosomal dominant genodermatosis, characterised by multiple pruritic hyperkeratotic papules and plaques primarily in seborrhoeic areas of head, neck, trunk and may be accompanied by palmar pitting, nail dystrophy and oral lesions⁽⁶⁾. Onset age is 6-20 years with peak incidence between ages 11 and 15 years⁽⁷⁾.

Diagnosis is made by positive family history, diagnostic histopathologic, features and presence of mutations in ATP2A2/SERCA gene⁽⁸⁾.

Mutation of the gene ATP2A2 located on chromosome 12 q 23-24 is found by sakuntabhai *et al*⁽¹⁾ which encodes for sarcoendoplasmic reticulum calcium ATPase pump that regulates cell differentiation and initiating assembly at desmosomes via intracellular signalling of calcium. Breaking down of desmosomes leads to acantholysis due to loss of calcium signalling.

Characteristic mucocutaneous findings such as hyperkeratotic papules preferentially in seborrheic distribution areas and longitudinal erythronychia with V shaped notches at distal edge of nail and whitish oral mucosal papules. Flexural lesions shall become hypertrophic and malodorous⁽⁹⁾.

Two prominent histologic features are acantholysis and dyskeratosis (corp ronds and grains).

CONCLUSION

Prevalence of darier disease in north-east England is 1 in 36000⁽¹⁰⁾ and in Denmark it is 1 in 100000⁽¹¹⁾. As far as our knowledge concerned, only few cases of darier disease are reported worldwide and herein our case illustrates features of darier disease such as classical clinical findings with positive family history and histopathological confirmation.

References

1. Sakuntabhai A, Ruiz-perez V, Carter S, Jacobsen N, Burge S *et al.*: Mutations in ATP2A2, encoding a Ca²⁺ pump, cause Darier disease. *Nat Genet* 1999; 271-277.
2. A.A.Jalil, R.B.Zain, and I.Vanderwaal, "Darier disease: a case report," *British journal of oral and maxillofacial surgery*, vol.43, no.4, pp.336-338, 2005.
3. T.Onozuka, D sawamura, K.Yokota, and H.Shimizu, "Mutational analysis of ATP2A2 gene in two darier disease families with intrafamilial variability," *British journal of dermatology*, vol.150, no.4, pp.652-657, 2004.
4. D.G.Bernabe, L.T.Kawata, I.M.Beneti, M.M. Crivelini, and E.R.Biasoli, ' Multiple white papules in palate: oral manifestation of darier's disease,' *Clinical and experimental dermatology*, vol.34, no.7, pp.e270-e271, 2009.
5. Philips SB, Baden HP. Darier-white disease and miscellaneous hyperkeratotic disorders. In: Fitzpatrick TB, Eisen AZ, Wolff K, *et al*, editors. *Dermatology in general medicine*. New York: McGraw hill, 1993:547-52
6. Cambiaghi S *et al.*, Acantholytic dyskeratotic epidermal nevus as a mosaic form of darier's disease. *J Am Acad Dermatology* 1995; 32:284-6
7. Burge S *et al.*, Darier white disease: a review of clinical features in 163 patients. *J Am Acad Dermatology* 1992; 27:40-50.
8. Wolff k *et al.*, *Fitzpatrick's color atlas and synopsis of clinical dermatology*. New york: Mc Graw-Hill; 2005. pp.88-9
9. Elsbach EM, Nater JP. The hypertrophic forms of Darier's disease. *Dermatologica* 1960; 120:93-4
10. Munro S *et al.*, Penetrance and expressivity in adults and children. *Br. J Dermatology* 1992; 127:126-30
11. Svendsen IB *et al.*, Prevalence of darier's disease in Denmark *Acta Derm Venereol* 1959; 39:256-269.

How to cite this article:

Navein R K. *et al* (2019) 'Darier-White Disease With Variable Penetrance', *International Journal of Current Advanced Research*, 08(01), pp. 16878-16880. DOI: <http://dx.doi.org/10.24327/ijcar.2019.16880.3138>
