

PIGMENTED PATCHES IN A CHILD-A RARE PRESENTATION OF IDIOPATHIC ERUPTIVE MACULAR PIGMENTATION

Bhavani Kirubakaran and Sivasubramanian V

Department of Dermatology, Venereology and leprosy

ARTICLE INFO

Article History:

Received 10th September, 2018

Received in revised form 2nd October, 2018

Accepted 26th November, 2018

Published online 28th December, 2018

Key words:

Idiopathic eruptive macular pigmentation, hyperpigmentation, papillomatosis, acanthosis

ABSTRACT

Idiopathic eruptive macular pigmentation (IEMP) is an uncommon, rather under-reported disease entity of the pediatric age characterized by asymptomatic, brownish hyperpigmented macules involving the neck and trunk with no preceding inflammation or exposure to drug. Here we report this case to increase awareness of this entity among dermatologists, dermatopathologists and pediatricians. A 10-year-old healthy girl presented with brownish-gray to dark, discrete, asymptomatic macules on the face, trunk, neck and limbs of insidious onset. Histopathologic examination showed melanophages, mild perivascular lymphohistiocytic infiltrate in the papillary dermis and papillomatosis. The natural course of the disease is spontaneous remission without treatment, which was so even in our patient. IEMP is a benign entity with an excellent prognosis as it exhibits spontaneous resolution. It falls into the differential diagnoses of asymptomatic hyperpigmentary disorders in pediatric population. Awareness of the entity leads to avoidance of unnecessary aggressive damaging treatment.

Copyright©2018 **Bhavani Kirubakaran and Sivasubramanian V**. This is an open access article distributed under the Creative Commons Attribution License, which permits unrestricted use, distribution, and reproduction in any medium, provided the original work is properly cited.

INTRODUCTION

Idiopathic eruptive macular pigmentation (IEMP) is a pigmentary disorder of unknown etiology. It was first reported by Degos *et al*¹ in French in 1978. Knowledge and familiarity of this entity is minimal. Less than 60 cases of IEMP have been reported in the literature so far, reflecting unfamiliarity with the entity. The first description English was by Sanz de Galdeano *et al*. in 1996.² That paper summarized the criteria for diagnosis of this condition, namely, (1) Eruption of brownish-black, discrete, nonconfluent, asymptomatic macules involving the neck, trunk and proximal extremities in children and adolescents, (2) Absence of any preceding inflammatory lesions, (3) No previous drug exposure, (4) Basal layer hyperpigmentation of the epidermis with dermal melanophages without any basal cell damage or lichenoid infiltrate, (5) Normal mast cell counts. The largest series of ten cases has been described by Jang *et al*. from Korea.³ We report one such case to highlight its existence and self-resolving course.

Case Report

This is a case report of a 10-year-old healthy girl who presented with asymptomatic brown to dark lesions over the face, neck, trunk and proximal extremities of 5 months' duration. They appeared spontaneously without any preceding lesions or topical therapy. The lesions started insidiously and gradually progressed over a duration of 1 month.

*Corresponding author: **Bhavani Kirubakaran**
Department of Dermatology, Venereology and leprosy

There was no history of prior drug intake. The general physical and systemic examination was unremarkable. Cutaneous examination revealed multiple brownish gray to dark, discrete, round to oval macules (Figure 1) and (Figure 2).

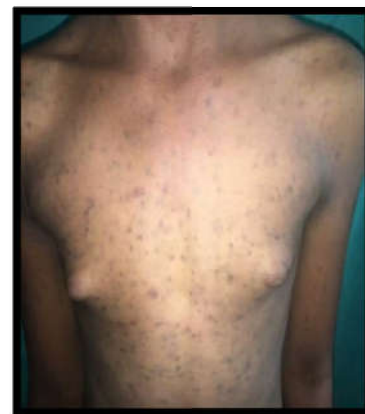

Figure 1 Generalized hyperpigmented discrete oval macules present on the trunk, neck and upper extremities

The lesions on the lower abdomen had a velvety texture (Figure 3) and (Figure 4). Palms and soles were spared. The size varied from 0.5 cm to 3 cm. Darier's sign was negative. The mucosae, hair and nails were normal. Hematological investigations were normal. Biopsy showed moderate irregular acanthosis, slight papillomatosis (Figure5) and (Figure6) and basal layer hyperpigmentation (Figure7) and (Figure8). The upper dermis showed sparse superficial lymphohistiocytic infiltrate. Few melanophages

were seen in the papillary dermis. The mast cell number was normal. The final diagnosis was IEMP. No specific treatment was given.

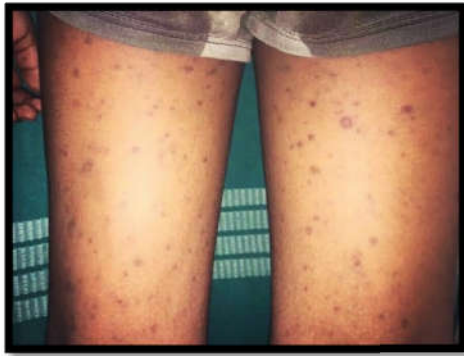

Figure 2 Generalized hyperpigmented discrete macules present on the lower extremities

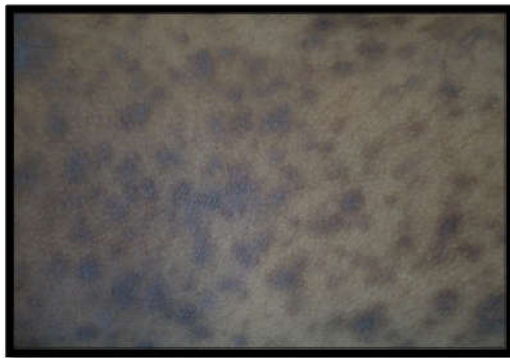

Figure 3 Close up of lesions shows velvety texture of the lesions

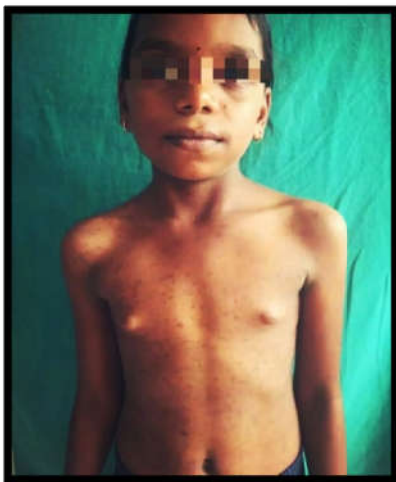

Figure 4 Few hyperpigmented macules on the cheeks

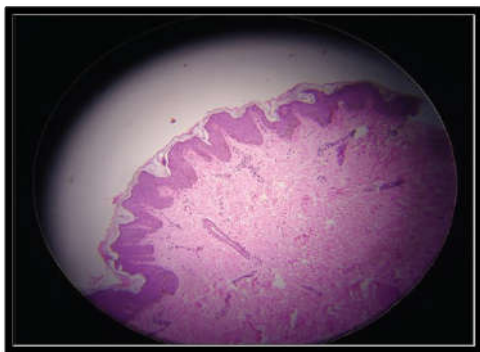


Figure 5 Histopathology with H and E staining under x4 shows moderate acanthosis, papillomatosis and sparse lymphohistiocytic unfiltrae in the upper dermis

This case is reported for its rarity with an objective to increase its awareness among dermatologists, pathologists and pediatricians. A misdiagnosis can lead to unnecessary, sometimes dangerous management of a clinical entity which otherwise regresses spontaneously.

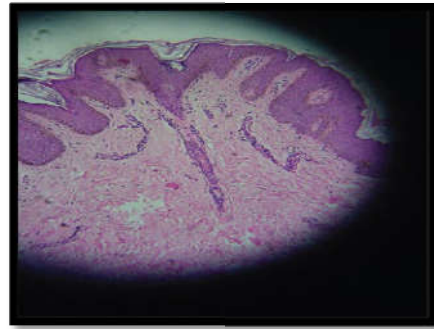

Figure 6 H and E x40 view showing acanthosis, papillomatosis and sparse lymphohistiocytic infiltrate in the upper dermis with increased basal cell pigmentation

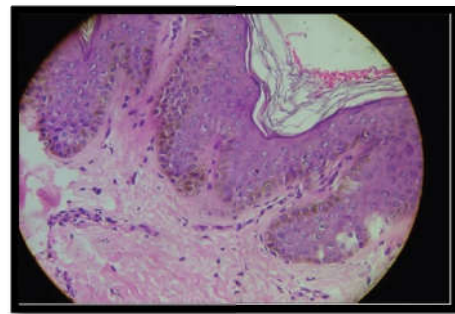


Figure 7 H AND E x40 view showing basal layer hyperpigmentation. The upper dermis showed sparse superficial lymphohistiocytic infiltrate

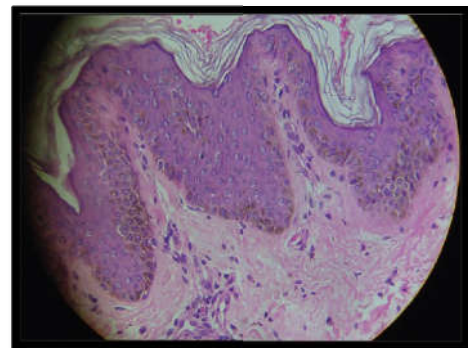


Figure 8 H and E showing under x40 shows acanthosis , papillomatosis and basal layer hyperpigmentation with sparse superficial lymphohistiocytic infiltrate in the upper dermis

DISCUSSION

IEMP is an under diagnosed condition. Although it clinically resembles lichen planus pigmentosus, erythema dyschromicum perstans, fixed drug eruption and mastocytosis. Therefore the only way to differentiate is by histopathological examination. The youngest and oldest case reported in the literature is that of a 1-year-old and a 50-year-old.^{3,5} Though most cases have been reported in the young; it has also been reported in a 31-year-old female.⁶ A study by Sanz de Galdeano *et al.*² gave the criteria for diagnosis in 1996, namely: (a) Eruption of brownish, non-confluent, asymptomatic macules involving the trunk, neck and proximal extremities in children and

adolescents (b) absence of preceding inflammatory lesions (c) no previous drug exposure (d) basal layer hyperpigmentation of the epidermis and prominent dermal melanophages without visible basal layer damage or lichenoid inflammatory infiltrate (e) normal mast cell count. The present case fulfilled all the above mentioned criteria and very few cases of similar nature have been reported^{2,7} among Indians. An unusual case of a 24-year-old woman lasting 21 years was characterized by several periods of spontaneous resolution followed by recurrences.³

Histopathologically, IEMP is an epidermal hypermelanosis with increased melanin in the basal layer of the epidermis and variable dermal inflammation and melanophages in the dermis. However, as these findings in IEMP are not specific, biopsy is important in the diagnosis of idiopathic eruptive macular pigmentation to exclude the other conditions, which clinically resemble it.

The apparent rarity of this condition is probably due to physicians not being familiar with this entity. Reluctance to biopsy children may be another factor that leads to underreporting of this condition.

CONCLUSION

This case is reported for its rarity with an objective to increase its awareness among dermatologists, pathologists and pediatricians. A misdiagnosis can lead to unnecessary management of a clinical entity which otherwise regresses spontaneously. Awareness of this entity leads to precise diagnosis and better advice.

References

1. Degos R, Civatte J, Belaïch S. Idiopathic eruptive macular pigmentation (author's transl). *Ann Dermatol Venereol* 1978;105:177-82
2. Sanz de Galdeano C, Llauti-Labrøze C, Bioulac-Sage P, Nikolic M, Taoeb A. Idiopathic eruptive macular pigmentation: Report of five patients. *Pediatr Dermatol* 1996;13:274-7
3. Jang KA, Choi JH, Sung KS, Moon KC, Koh JK. Idiopathic eruptive macular pigmentation: Report of 10 cases. *J Am Acad Dermatol* 2001;44:351-3
4. Mehta S, Aasi S, Cole R, Chu P, Weinberg JM. Idiopathic eruptive macular pigmentation: A case of 21 years' duration. *J Am Acad Dermatol* 2003;49:S280-2
5. Mantovani L, Minghetti S, Ricci M, Zauli S, Marzola A, Corazza M. Idiopathic eruptive macular pigmentation in a 50-year-old man. *Eur J Dermatol* 2010;20:633-4
6. Milobratovic D, Djordjevic S, Vukicevic J, Bogdanovic Z. Idiopathic eruptive macular pigmentation associated with pregnancy and Hashimoto thyroiditis. *J Am Acad Dermatol* 2005;52:919-21.
7. Verma S, Thakur BK. Idiopathic eruptive macular pigmentation with papillomatosis. *Indian Dermatol Online J* 2011;2:101-3.
8. Joshi R. Idiopathic eruptive macular pigmentation with papillomatosis: Report of nine cases. *Indian J Dermatol Venereol Leprol* 2007;73:402-5

How to cite this article:

Bhavani Kirubakaran and Sivasubramanian V (2018) 'Pigmented Patches In A Child-A Rare Presentation of Idiopathic Eruptive Macular Pigmentation', *International Journal of Current Advanced Research*, 07(12), pp. 16427-16429. DOI: <http://dx.doi.org/10.24327/ijcar.2018.16429.3037>
