



Research Article

MANAGEMENT OF STUCK LONG-TERM PORT-A-CATH

Osama Bawazir

Department Of Surgery Faculty of Medicine In Umm Al-Qura University At Makkah, Saudi Arabia

ARTICLE INFO

Article History:

Received 4th June, 2018

Received in revised form 25th July, 2018

Accepted 18th August, 2018

Published online 28th September, 2018

Key words:

Central venous catheters, Port-A-Cath, Complications, Stuck catheters

ABSTRACT

Background: Totally implanted venous access device (Port-A- Caths) is the stander access for chemotherapy treatment in children. Their removal after finishing the treatment is usually straight forward, but this however is not the case always and their removal can sometimes be challenging.

Methods: A retrospective review of 685 children's who had Port-A- Cath's insertion and removals from October 2005 to 2014 were reviewed.

Result: 674(98%) of the Port-A- Cath's lines were removed without difficulty. 76(11%) were removed because of sepsis or catheter malfunction, and 598 (89%) were removed after completion of chemotherapy. Removal of 11(1.6%) of these catheters was difficult. All required second neck incision and exploration of the internal jugular vein with proximal and distal control. In five out of eleven the catheter was removed safely after proper venotomy. One catheter broke during removal and the distal end with the calcification migrated and developed pulmonary embolus which was retrieve by interventional radiologist. Three other catheters require combined approach with the interventional radiologist to remove them. The remaining two Catheters could not remove completely and the remnant part was left inside.

Conclusions: Long-term silicon indwelling catheters which are used solely for chemotherapy administration can have pericatheter calcification. This makes their removal difficult and associated with complications. Removal of these catheters should not be taken lightly and should be done in center with supportive services including Interventional Radiology and Cardiac Surgery.

Copyright©2018 Osama Bawazir. This is an open access article distributed under the Creative Commons Attribution License, which permits unrestricted use, distribution, and reproduction in any medium, provided the original work is properly cited.

INTRODUCTION

Long-term central venous access has become an integral part of the management of children with various cancers and gastrointestinal malfunction disorders and in those children that require long-term access for medications and frequent blood products transfusion. A variety of access devices currently are now available but Port-A-Cath continues to be the most commonly used.

There are several complications associated with the use of Port-A-Cath but most of these complications happen during insertion and some happen while the catheter in situ, which may require removal, but very rarely these complications occur during their removal after completion of treatment (1, 2, 3, 4, 5, 6, 7). Removal of long term Port-A-Cath vascular access is usually very easy and without complications but some time removal can be challenging when the catheter is stuck (8, 9, 10, 11, 12). This is a report of our experience with 674 Port-A-Cath's stressing the difficulties that may be encountered during removal of these catheters.

**Corresponding author: Osama Bawazir*

Department Of Surgery Faculty of Medicine In Umm Al-Qura University At Makkah, Saudi Arabia

MATERIAL AND METHODS

The medical records of 685 children's who underwent Port-A-Caths removal from October 2005 to 2014 were retrospectively reviewed for age, sex, size of the Port-A-Cath used, indication for insertion, indication for removal and complications encountered at the time of removal.

RESULTS

685 children had Port-A-Cath insertion as part of their management. There were 361 (53.6%) males and 313 (46.4%) were females. Their mean age was 5.9 years. Different sizes of Port-A-Cath's were used including 4.5, 6 and 6.6 French). The indications for insertion of Port-A-Cath's were variable but chemotherapy administration for various types of malignancy was the commonest indication. Other indications included long term administration of various medications and frequent blood and blood products transfusion.

The Port-A-Cath's were removed after finishing chemotherapy in 674 patients (89%) and in 76 (11%) cases, Port-A-Cath's were removed because of malfunction or sepsis. The duration of catheter stay was also variable. The mean time of the port stay in the patients was 12.3 months and the longest port stay was 42 months.

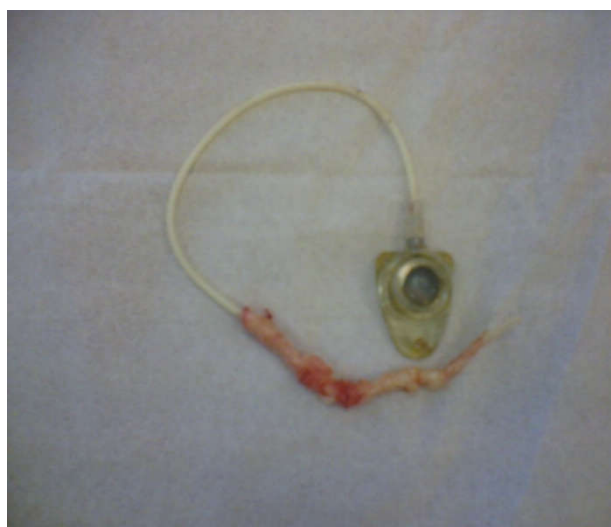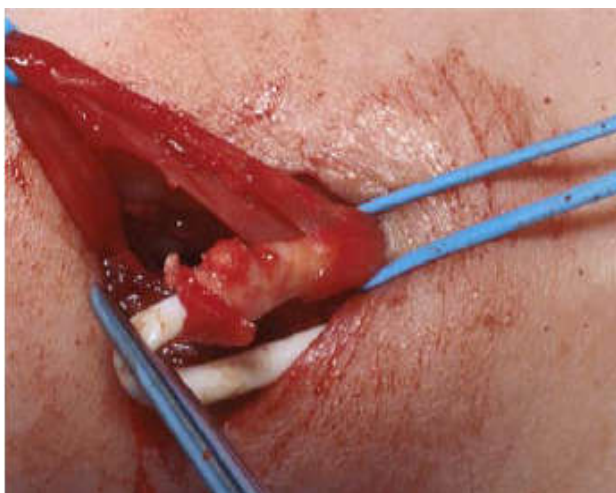


Figure 1a and 1b Clinical intraoperative photographs showing removal of a Port-A-Cath. Not the calcified sheath which was removed with the catheter

In 674 (98%) patients, the ports were removed easily. This was done via a single incision at the port site and excision of the fibrous capsule over. The Port-A-Cath's and the catheter were removed easily without any complication. The average operating time for removal of Port-A-Cath's was 19 minutes. In the remaining 11 (1.6%) patients (7 males and 4 females), there were difficulties during removal with tethering of the catheter at site of entry (Table 1).

Port-A-Cath's were removed after being in place for a mean of 36.9 months (29-45 months). All of 11 ports needed a second incision at the site of entry to remove them (Figures 1a and 1b). Five of them required extensive dissection and control venotomy to remove them (Figures 2a and 2b).

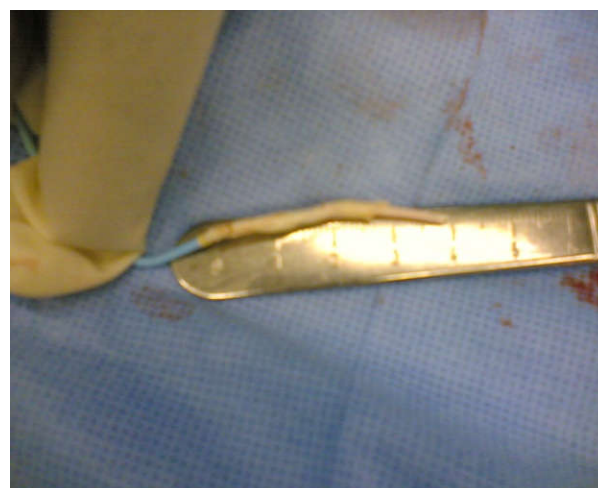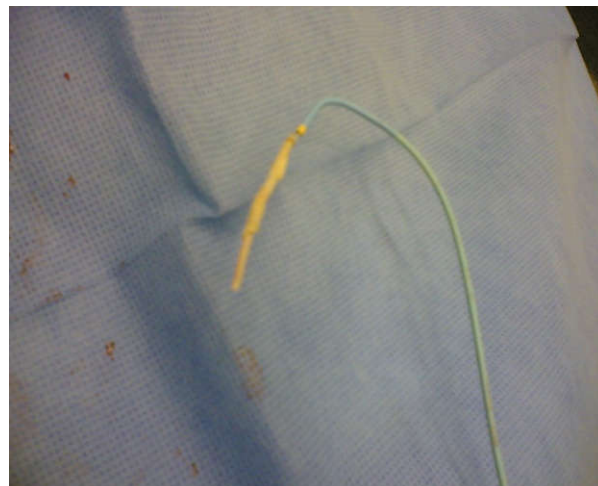


Figure 2a and 2b Clinical photographs showing the distal segment of the catheter together with the calcified sheath that migrated and was removed by the interventional radiologist

Table 1 Clinical features of patients with stuck catheters

Patient no	Duration of the line (Months)	Location (Vein Site)	Diagnosis	Duration of F/U (Years)	Action
Patient 1	36	Ext jugular	ALL	8	Migration of distal part causing pulmonary embolism, retrieved by interventional radiologist
Patient 2	31	Subclavian	ALL	8	Removed together with interventional radiologist help
Patient 3	32	Ext. jugular	NHL	6.5	Removed completely
Patient 4	29	Subclavian	ALL	6	Removed completely
Patient 5	45	subclavian	NHL	6	Removed together with interventional radiologist help
Patient 6	32	subclavian	ALL	2 days	The fixed part left in place
Patient 7	40	Subclavian	ALL	5	Removed completely
Patient 8	44	ext. jugular	ALL	4	Removed completely
Patient 9	38	Subclavian	Medulloblastoma	3	Removed together with interventional radiologist help
Patient 10	38	subclavian	ALL	2	Removed completely
Patient 11	42	subclavian	Medulloblastoma	0.3	The fixed part left in place and the proximal part removed by interventional radiologist

Six of them were inserted in the external jugular vein and 5 were inserted in left subclavian vein. All 11 Port-A-Cath's with difficulties were used for chemotherapy and 9 out of 11

patient had migration of the distal part of the catheter with its calcification during its dissection leading to pulmonary embolism (Figure 3).

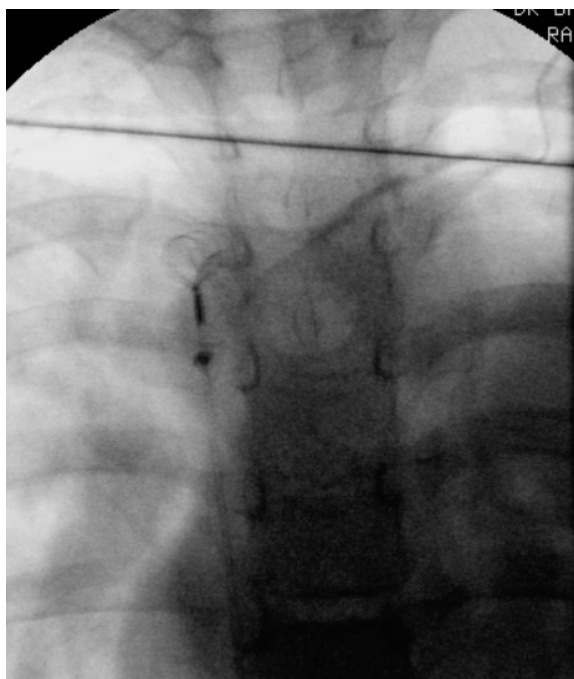


Figure 3 A chest radiograph showing the migrated segment of the catheter

Retrieval and removal of this migrated distal part was achieved by the interventional radiologist using a snare through the femoral vein. In three cases, the catheter could not be pulled out due to adhesions. Their approach necessitated a team approach. The free floating part of the catheter was removed by the interventional radiologist using a snare, then extensive manipulation and dissection of the catheter was done until the catheter was freed and cut at the level of entry. The remaining free part of the catheter was removed by the interventional radiologist using a snare through the femoral vein. Two Catheters could not be removed completely and the calcified adherent part was left inside the vein.

All patients did well postoperatively and were discharged home in a good general condition.

DISCUSSION

Insertion of Port-A-Cath's is currently a common procedure performed for children with various malignancies. The majority of these catheters are used to administer chemotherapy and so their use is usually long term. Their insertion and maintenance is important to minimize iatrogenic injury and reduce catheter related complications. Many complications have been described because of central venous lines. Most of these complications have been related to their insertion and very little is written about complications related to their removal. The recognition and management of complications related to central venous catheters removal should be emphasized.

The removal of Port-A-Cath's is a common procedure. Reasons for their removal include end of treatment, proven and unresolved catheter sepsis, catheter fracture, occlusion unresponsive to unblocking techniques and drugs, and thrombosis (5, 8). Once the need for the catheter is done, careful attention to removal of the Port-A-Cath is important to prevent complications related to their removal such as bleeding, infection, air embolism, and catheter embolism (1, 2, 11). Port-A-Cath's that are retained after attempted removal is a complication encountered predominantly in catheters that

have been in use for a prolonged duration (13). Long-term central venous catheters are known to have pericatheter adhesions and calcification. These two factors are important leading to stuck catheters that are difficult to be removed. The incidence of stuck catheters is not exactly known and variable results were reported. Wall and Kierstead reported 8 stuck catheters of 829 (0.965%) peripherally inserted catheters (5). Wilson et al on the other hand reported 16% complications during removal of 200 consecutive totally implantable venous access devices (8). Vellankiet al reported 19 (0.92%) retained catheters, 3 of them could not be removed (12). Patel et al reported 58 (4%) stuck catheters in a series of 1,306 patients (14). Removal of Port-A-Cath is usually simple and through a single incision (3, 8). This was the case in our series but sometimes it can become complicated when the catheter is found to be stuck because of its adherence within a central vein. The cause of this is not known but there is an association of difficult removal with early age at insertion, acute lymphoblastic leukemia diagnosis, and long port dwell time (14). Removal of central venous catheter requires utmost care, and should never be done by forceful traction, as it may lead to bleeding, rupture of vessels or fracture of the catheter leading to migration of the floating segment causing pulmonary embolism (4, 12). This was the case in one of our patients.

All retained catheters should be removed if possible because of the potential serious complication. Removal of Port-A-Cath's should not be taken lightly and should be done in centers with supportive services such as interventional Radiology and Cardiac Surgery. Completely embedded catheters may require sternotomy and venotomy to remove them. In our series of 685 patients, 11 (1.6%) of them were found to be stuck and difficult to be removed. Five of them required extensive dissection to remove them, 6 necessitated the help of interventional radiologist but two catheters could not be removed completely and the calcified adherent part was left inside the vein without adverse effects. There are several techniques described to remove stuck catheters. Currently the most commonly used technique also considered the safest is "endoluminal dilation" also known as Hong's Technique (15). This was modified by Quaretti and Galli (16). Lodi et al described a modified technique using a Vollmar ring to remove a stuck catheter as an alternative to Hong's technique, or after a failed attempt at using Hong's technique (17). Huang et al described a technique to remove a "stuck" catheter. They called it "push-in" force technique to detach the adherence of the catheter from the central vein (10).

In conclusion, long-term central catheters can have pericatheter adhesions and calcification which makes their removal a challenge. These catheters should be removed when possible because of potential complications. Their removal should not be taken lightly and should be done in center with supportive services including interventional radiology and cardiac surgery. An informed detailed consent should be taken in this regard.

References

1. Makhija N, Choudhury M, Kiran U, Chowdhury U. The stuck central venous catheter: a word of caution. *Heart Lung Circ.* 2008 Oct; 17(5):432-4.
2. Mahadeva S, Cohen A, Bellamy M. The stuck central venous catheter: beware of potential hazards. *Br J Anaesth.* 2002 Oct; 89(4):650-2.

3. Idowu O, Brown J, Kim S, Kim S. Mechanics of a stuck central venous catheter removal. *J Pediatr Surg* 2016, 51 (5): 872-875.
4. Nakabayashi K, Nomura H, Isomura D, Sugiura R, Oka T. Successful Retrieval of a Dismembered Central Venous Catheter Stuck to the Right Pulmonary Artery Using a Stepwise Approach. *Case Rep Cardiol*. 2016; 2016:6294263.
5. Wall JL, Kierstead VL. Peripherally inserted central catheters: resistance to removal: a rare complication. *J Intraven Nurs*. 1995 Sep-Oct; 18(5):251-4.
6. Ng PK, Ault MJ, Fishbein MC. The stuck catheter: a case report. *Mt Sinai J Med*. 1997 Sep-Oct; 64(4-5):350-2.
7. Frey AM, Schears GJ. Why are we stuck on tape and suture? A review of catheter securement devices. *J Infus Nurs*. 2006 Jan-Feb; 29(1):34-8.
8. Wilson GJ, van Noesel MM, Hop WC, van de Ven C. The catheter is stuck: complications experienced during removal of a totally implantable venous access device. A single-center study in 200 children. *J Pediatr Surg*. 2006 Oct; 41(10):1694-8.
9. Huang SC, Tsai MS, Lai HS. A new technique to remove a "stuck" totally implantable venous access catheter. *J Pediatr Surg*. 2009 Jul; 44(7):1465-7.
10. Mortensen A, Afshari A, Henneberg SW, Hansen MA. Stuck long-term indwelling central venous catheters in adolescents: three cases and a short topical review. *Acta Anaesthesiol Scand*. 2010 Jul; 54(6):777-80.
11. Vellanki VS, Watson D, Rajan DK, Bhola CB, Lok CE. The stuck catheter: a hazardous twist to the meaning of permanent catheters. *J Vasc Access*. 2015 Jul-Aug; 16(4):289-93.
12. Aworanti OM, Linnane N, Tareen F, Mortell A. Incidence and outcome of retained Port-A-Cath fragments during removal. *Pediatr Surg Int*. 2017 Jun 5
13. Patel PA, Parra DA, Bath R, Amaral JG, Temple MJ, John PR, Connolly BL. IR Approaches to Difficult Removals of Totally Implanted Venous Access Port Catheters in Children: A Single-Center Experience. *J Vasc Interv Radiol*. 2016 Jun; 27(6):876-81.
14. Hong J.H. A breakthrough technique for the removal of a hemodialysis catheter stuck in the central vein: endoluminal balloon dilatation of the stuck catheter. *J Vasc Access*. 2011; 12(4):381-384.
15. Quaretti P, Galli F, Fiorina I, Moramarco LP, Spina M, Forneris G, Torresi M, Bellazzi R. A refinement of Hong's technique for the removal of stuck dialysis catheters: an easy solution to a complex problem. *J Vasc Access*. 2014 May-Jun; 15(3):183-8.
16. Lodi M, Ebrahimi RF, Pezzotti P, Carbonari L. The removal of a stuck catheter: an alternative to Hong's technique. *J Vasc Access*. 2016 Nov 2; 17(6):548-551.

How to cite this article:

Osama Bawazir (2018) 'Management of Stuck Long-Term Port-A-Cath', *International Journal of Current Advanced Research*, 07(9), pp. 15675-15678. DOI: <http://dx.doi.org/10.24327/ijcar.2018.15678.2870>
