



UTILITY OF MULTIDETECTOR COMPUTED TOMOGRAPHY IN EVALUATION OF MANDIBULAR FRACTURES

Noha Abdelfattah Ahmed Madkour*

Department of Radiodiagnosis, Kasr Alainy hospital, Cairo University, Cairo, Egypt

ARTICLE INFO

Article History:

Received 10th November, 2018

Received in revised form 2nd

December, 2018

Accepted 26th January, 2019

Published online 28th February, 2019

Key words:

Mandibular fractures, multidetector computed tomography, displacements, comminution.

ABSTRACT

Background: Mandibular fractures are considered to be one of the commonest maxillofacial injuries. Multidetector computed tomography, multiplanar reformatted and 3-Dimensional volume rendered images provide high capability in accurate evaluation of mandibular fractures, displacements and comminution.

Aim: To identify the role of multi-detector computed tomography, multiplanar reformatted and 3-Dimensional volume rendered images in evaluation of mandibular trauma and to define the frequency and locations of mandibular fractures.

Subjects and Methods: In this study, 32 patients with mandibular fractures were referred to the Emergency Unit of Kasr Alainy University Hospital. All patients were subjected to multidetector computed tomography in axial sections, multiplanar reformatted and 3-Dimensional volume rendering images.

Statistics: A prospective descriptive study. Results: Motor vehicle accidents were the commonest mode of trauma in mandibular fractures (59%). Over 90 % of cases were men. Patients with single mandibular fractures (62.5%) exceed cases with multiple fractures (37.5%). Mandibular body was the commonest site to be fractured in mandibular trauma 27.7%. 57.6% of mandibular fractures were comminuted fractures.

Conclusion: Multi-detector computed tomography with multiplanar reformatted and 3-Dimensional volume rendered images are mandatory for comprehensive perceptual assessment of unifocal and multifocal mandibular fractures.

Copyright©2019 Noha Abdelfattah Ahmed Madkour1. This is an open access article distributed under the Creative Commons Attribution License, which permits unrestricted use, distribution, and reproduction in any medium, provided the original work is properly cited.

INTRODUCTION

Mandibular fractures are, by far considered to be one of the commonest maxillofacial injuries [1,2]. Mandibular injuries are either isolated or associated with other maxillofacial fractures with consequent deformities and functional complications [3,4]. Serious mandibular injuries could lead to dramatic clinical sequelae and may interfere against secure air way maintenance procedures [5,6,7].

Due to special anatomical morphology of the mandible, multiple patterns and various classifications of mandibular fractures are considered including single or unifocal and multifocal or multiple mandibular fractures [8,9,10,11,12,13]. Meanwhile, advanced imaging modalities mainly, multidetector computed tomography (MDCT) with multiplanar reformatted (MPR) and 3 dimensional (3D) volume rendering (VR) images are essential requisite for precise estimation and definitive characterization of mandibular fractures, in different planar orientation involving vertical and horizontal mandibular buttresses [1,14,15,16,17,18].

*Corresponding author: Noha Abdelfattah Ahmed Madkour
Department of Radiodiagnosis, Kasr Alainy hospital, Cairo University, Cairo, Egypt

The objective of this study is to identify the role of multi-detector computed tomography, multiplanar reformatted and 3-D volume rendered images in evaluation of mandibular trauma and to define the frequency and locations of mandibular fractures.

MATERIALS AND METHODS

Patients

This study is a prospective descriptive study. 32 patients (29 males and 3 females) were enrolled in this study, with the mean age of 33 years ranging from 18 to 74 years, presenting with mandibular trauma due to motor vehicle accidents (MVA), fall from a height (FFH), and direct assault. The population group was referred to the Emergency Unit of Kasr Alainy University Hospital during the period from March 2016 to December 2017.

Data Acquisition

All patients were scanned by a 16-channel multi-slice computed tomography (Somatom Emotion 16; Siemens Healthcare, Erlangen, Germany) and (BrightSpeed; GE Healthcare, Milwaukee, Wisconsin, USA). MDCT of the face was obtained for all cases with the following acquisition data: 16×0.6 mm collimation, matrix 512 x 512,

pitch 0.6, table feed 7.7 mm/s, rotation time 1.00s/HE, tube current 300 mA, voltage 120 kV, field of view 230-290 mm and a total exposure time of 11 s. All patients were scanned by helical MDCT from head vertex to chin in axial sections of 1.25 mm thickness. MPR in coronal and sagittal planes and 3D volume rendering images were obtained from thin-sectioned axial source images.

Mandibular fractures were classified into unifocal and multifocal fractures. Further anatomical classification of mandibular fractures included: Body, angle, symphyseal, parasymphiseal, ramus, condyle, subcondyle, coronoid and dentoalveolar. Associated maxillofacial and head fractures were estimated.

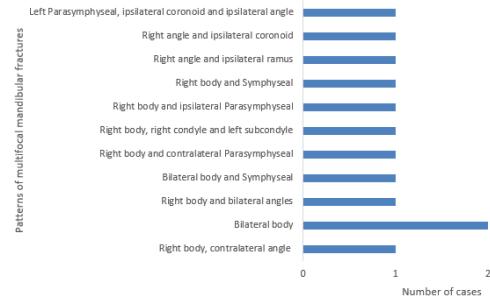
RESULTS

A total of 32 cases (29 males and 3 females) with 65 mandibular fractures were enrolled in the current study. Over 90 % of cases were males with male: female ratio 9:1. Mean age was 33 years ranging from 18-74 years. In this study, mandibular fractures were mainly due to motor vehicle accidents (59.3%) followed by fall from a height (34.3%) then interpersonal violence (6.2%). The commonest mandibular fracture was mandibular body followed by dentoalveolar fractures then angle as noted in table 1. Dentoalveolar fractures are usually extensions of fracture body, angle, parasymphiseal and symphyseal regions into the mandibular alveolar margin. The current results revealed that cases with unifocal mandibular fractures comprise 20 cases (62.5%) with 28 fractures (43%) and multifocal mandibular fractures comprise 12 cases (37.5%) with 37 fractures (57%) (Table 1) with even ratios for both unilateral and bilateral multifocal mandibular fractures (Graph 1).

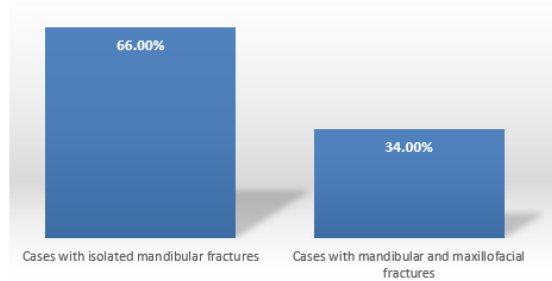
In this study, displaced fractures were 61% of cases while non-displaced were 39%. Simple mandibular fractures constitute 43.4% of cases while comminuted fractures were 57.6%. Associated maxillofacial injuries were noted in 11 cases (34.3%) (Graph 2). temporal bone fractures and one case with frontal bone fracture. Axial and MPR images especially coronal images are essential for accurate assessment of different patterns, exact number, locations, extensions of different fractures and detailed description of fracture lines, displacements and comminution. 3-D VR confer precise localization and assorted classification of different mandibular fractures in multiple planes. bone fractures and one case with frontal bone fracture. MDCT with MPR and 3-D VR are standard imaging technique in evaluation of mandibular fractures and are virtually useful in perceptive evaluation of horizontal and vertical segments

Table 1 Frequency and locations of total, unifocal and multifocal mandibular fractures

Location	Total mandibular fractures	Unifocal mandibular fractures	Multifocal mandibular fractures
Body	18 (27.7%)	6 (21.4%)	12 (32.43%)
angle	10(15.38%)	4(14.28 %)	6(16.2 %)
Symphyseal	3(4.6%)	1(3.57%)	2(5.4%)
Parasymphiseal	6(9.2 %)	3(10.7 %)	3(8.1%)
Ramus	3(4.6 %)	2(7.1%)	1(2.7%)
Condyle	2(3%)	1(3.57%)	1(2.7%)
Subcondyle	3(4.6 %)	2(7.1%)	1(2.7%)
Coronoid	3(4.6 %)	1(3.57%)	2(5.4%)
Dentoalveolar	17(26.15 %)	8 (28.57 %)	9(24.3%)



Graph 1 Patterns and number of cases with multifocal mandibular fractures (n=12).



Graph 2 Percentage of cases with isolated mandibular fractures and cases with mandibular and maxillofacial fractures.

DISCUSSION

Severe maxillofacial fractures usually result from high kinetic energy and high velocity impact forces [19,20,21]. Many studies concluded that MVA were the commonest preceding mode of trauma in mandibular and maxillofacial fractures in the developing countries which was demonstrated in the current study [22,23,24,25,26]. Also men were the commonest to be injured in mandibular trauma compared to females as noted in most trauma studies [23,24].

Obimakinde *et al*, and Raju *et al*, found that the mandible was the commonest fracture in maxillofacial trauma and the commonest location to be fractured in mandibular trauma was mandibular body. The current results were consistent with the former studies [22,23]. The previous studies were incongruent with other studies that found that condylar fracture was the commonest mandibular fracture in FFH [14].

On the other hand, although mandibular fractures were not the predominant bone to be fractured in maxillofacial injuries in a study conducted by Patil and Melkundi but, mandibular body was still the commonest mandibular fracture in the latest study and other retrospective studies [18,25]. Invariably, mandibular body is a frequent target in mandibular trauma due to mobility and bony prominence [27,28,29].

In contrast to studies done by Srinivas *et al* who concluded the predominance of multifocal mandibular fractures, the current study concluded that cases with single mandibular fractures exceed multifocal ones which was in accordance to a study conducted by Natu *et al* who reported a high incidence of unifocal fractures [30,31,32].

Furthermore, many retrospective studies deduced that bilateral mandibular fractures overpassed unilateral multiple fractures being in disagreement to the current results where both subtypes of multiple mandibular fractures attained the same percentage [33,34].

In this study, the commonest combinations for multiple mandibular fractures were body and angle and bilateral body which coincides with a retrospective analysis performed by Ogundare *et al* and Srinivas *et al* [30,35].

In the present study, displaced and comminuted mandibular fractures were more common than simple and non-displaced fractures which was in agreement with a study obtained by tent *et al* and other relevant studies [36,37]. In this study, patients who sustain maxillofacial together with mandibular fractures were much less those presenting with only mandibular fractures which concurred to an epidemiological study held by Natu *et al* [32]. Also, the infrequent association between head trauma and mandibular fractures was described in the present study and other earlier studies [38].

CONCLUSION

MDCT, MPR and 3d VR imaging are mandatory for evaluation of mandibular fractures required for appropriate surgical planning. Percentage of cases with unifocal mandibular fractures was higher than multifocal ones. Mandibular body was most frequently injured in mandibular trauma. MDCT with high spatial resolution provide high capability in authentic assessment with accurate interpretation of various types of mandibular fractures.

Financial support and sponsorship

Nil

Conflicts of interest

None declared

Acknowledgements

None

References

1. Naeem A, Gemal H, Reed D. Imaging in traumatic mandibular fractures. Quantitative imaging in medicine and surgery. 2017 Aug; 7(4):469-479. doi: 10.21037/qims.2017.08.06
2. Scarfe WC. Imaging of maxillofacial trauma: evolutions and emerging revolutions. Oral Surgery, Oral Medicine, Oral Pathology, Oral Radiology, and Endodontology. 2005 Aug 1;100(2):S75-96. PMID: 16037795 DOI: 10.1016/j.tripleo.2005.05.057
3. Lee K. Global trends in maxillofacial fractures. Craniomaxillofac Trauma Reconstr. 2012;5:213–22. PMID: 24294404. DOI: 10.1055/s-0032-1322535
4. Motamedi MH, Dadgar E, Ebrahimi A, Shirani G, Haghghat A, Jamalpour MR. Pattern of maxillofacial fractures: a 5-year analysis of 8,818 patients. *Journal of trauma and acute care surgery*. 2014 Oct 1;77(4):630-4. PMID: 12524610 DOI: 10.1053/joms.2003.50049

5. Tuckett JW. Maxillofacial trauma in the emergency department: a review. *Surgeon*. 2014 Apr;12(2):106-14. PMID: 23954483. doi: 10.1016/j.surge.2013.07.001.
6. Dreizin D, Nam AJ, Tirada N, Levin MD, Stein DM, Bodanapally UK, Mirvis SE, Munera F. Multidetector CT of mandibular fractures, reductions, and complications: a clinically relevant primer for the radiologist. *RadioGraphics*. 2016 Sep 12;36(5):1539-64. PMID: 27618328 DOI: 10.1148/rg.2016150218
7. Teichgraeber JF, Rappaport NH, Harris JH Jr. The radiology of upper airway obstruction in maxillofacial trauma. *Ann Plast Surg* 1991;27(2):103–109. PMID:1952731
8. Yadav RR, Yadav AR, Dhond PV. Fracture mandible. 1st ed. Jaypee Brothers Medical Publishers, New Delhi, India; 2012.
9. Trelease RB. Netter's Surgical Anatomy Review PRN E-Book. 2nd ed. Elsevier Health Sciences, Philadelphia, PA; 2016.
10. Morrow BT, Samson TD, Schubert W, Mackay DR. Evidence-based medicine: Mandible fractures. *Plastic and reconstructive surgery*. 2014 Dec 1;134(6):1381-90. PMID: 25415101 DOI: 10.1097/PRS.0000000000000717.
11. The Comprehensive AOCMF Classification System: Mandible Fractures- Level 2 Tutorial. Carl-Peter Cornelius, Craniomaxillofac Trauma Reconstruction 2014;7 (Suppl 1):S15–S30. PMID: 25489388. DOI: 10.1055/s-0034-1389557.
12. Mehta N, Butala P, Bernstein MP. The imaging of maxillofacial trauma and its pertinence to surgical intervention. *Radiologic Clinics*. 2012 Jan1;50(1):43-57. PMID: 22099486 DOI: 10.1016/j.rcl.2011.08.005
13. Mihailova H. CLASSIFICATIONS OF MANDIBULAR FRACTURES-REVIEW. *Journal of IMAB*. 2006; 12(2): p. 3-5.
14. Honda I, Ogura I. Characteristic multidetector CT findings of mandibular fractures: comparison with falls and violence. *International Journal of Oral-Medical Sciences*. 2015;13(2):53-8. doi.org/10.5466/ijoms.13.53
15. Furlow B. Computed tomography of facial fractures. *Radiologic technology*. 2014 May 1;85(5):523CT-39CT.
16. Winegar BA, Murillo H, Tantiwongkosi B. Spectrum of critical imaging findings in complex facial skeletal trauma. *Radiographics*. 2013 Jan 1;33(1):3-19. PMID: 23322824 DOI: 10.1148/rg.331125080
17. Ogura I, Kaneda T, Mori S, Sekiya K, Ogawa H, Tsukioka T. Characterization of mandibular fractures using 64-slice multidetector CT. *Dentomaxillofacial Radiology*. 2012 Jul;41(5):392-5. PMID: 22282503 doi:10.1259/dmfr/67127210
18. Tomich G, Baigorria P, Orlando N, Méjico M, Costamagna C, Villavicencio R. Frequency and types of fractures in maxillofacial traumas. Assessment using multi-slice computed tomography with multiplanar and three-

- dimensional reconstructions. *Rev Argent Radiol.* 2011;75:305-17.
19. Nahum AM. The biomechanics of maxillofacial trauma. *Clinics in Plastic Surgery*,1975;2(1):59–64. PMID:1116327.
 20. Rudderman RH, Mullen RL. Biomechanics of the facial skeleton. *Clin Plast Surg.* 1992 Jan;19(1):11-29. PMID: 1537212
 21. Brookes CN. Maxillofacial and ocular injuries in motor vehicle crashes. *Annals of the Royal College of Surgeons of England.* 2004 May;86(3):149. PMID: 15140296. doi:10.1308/003588404323043247
 22. Obimakinde OS, Ogundipe KO, Rabi TB, Okoje VN. Maxillofacial fractures in a budding teaching hospital: a study of pattern of presentation and care. *The Pan African Medical Journal.* 2017;26. DOI:10.11604/pamj.2017.26.218.11621
 23. Raju NS, Ishwar P, Banerjee R. Role of multislice computed tomography and three-dimensional rendering in the evaluation of maxillofacial injuries. *Journal of Oral and Maxillofacial Radiology.* 2017 Sep 1;5(3):67. DOI:10.4103/jomr.jomr_25_17
 24. Adi M, Ogden GR, Chisholm DM. An analysis of mandibular fractures in Dundee, Scotland (1977 to 1985). *British journal of oral and maxillofacial surgery.* 1990 Jun 1;28 (3):194-9. PMID: 2135661. doi.org/10.1016/0266-4356(90)90088-3
 25. Patil S, Melkundi SS. Maxillofacial and orbital injuries evaluation by three dimensional MDCT. *Journal of Evolution of Medical and Dental Sciences.* 2015 Sep 7;4(72):12470-8. DOI: 10.14260/jemds/2015/1796
 26. Hoseini S, Mohammad Zandi & Seyed Rohallah. The relationship between head injury and facial trauma: a case-control study. *Oral Maxillofac Surg.* 2013;17:201-7. PMID: 23100036. DOI 10.1007/s10006-012-0368-z.
 27. Verma S, Chambers I. Update on patterns of mandibular fracture in Tasmania, Australia. *Br J Oral Maxillofac Surg.* 2015; 53:74–7. PMID: 25453253 DOI: 10.1016/j.bjoms.2014.10.003
 28. Morris C, Bebeau NP, Brockhoff H, Tandon R, Tiwana P. Mandibular fractures: an analysis of the epidemiology and patterns of injury in 4,143 fractures. *J Oral Maxillofac Surg.* 2015; 73(5):951.e1–951.e12. doi.org/10.1016/j.joms.2015.01.001
 29. Halazonetis JA. The 'weak' regions of the mandible. *British Journal of Oral Surgery.* 1968 Jan 1;6(1):37-48. PMID: 5244106. doi.org/10.1016/S0007-117X(68)80025-3
 30. Srinivas MR, Vijay Kumar KR, Vedaraju KS. Spectrum of mandibular fractures in motor vehicle accidents: MDCT evaluation. *Journal of medical scienceandclinicalresearch.*2016;4(8):1200314.doi .org/10.18535/jmscr/v4i8.
 31. Escott EJ, Branstetter BF. Incidence and characterization of unifocal mandible fractures on CT. *AJNR Am J Neuroradiol* 2008; 29: 890–4. PMID: 18272555 DOI: 10.3174/ajnr.A0973
 32. Natu SS, Pradhan H, Gupta H, Alam S, Gupta S, Pradhan R, et al. An epidemiological study on pattern and incidence of mandibular fractures. *Plast Surg Int* 2012;834364. PMID: 23227327. DOI: 10.1155/2012/834364.
 33. Buch K, Mottalib A, Nadgir RN, Fujita A, Sekiya K, Ozonoff A, et al. Unifocal versus multifocal mandibular fractures and injury location. *Emergency radiology.* 2016 Apr 1; 23(2):161-7. PMID: 26797024 DOI: 10.1007/s10140-015-1375-9
 34. Moura LB, dos Santos Trento G, de Azambuja Carvalho PH, Granucci M, de Oliveira JC, Pereira-Filho VA. Double unilateral, bilateral, and multiple mandibular fractures: an observational study. *Oral and maxillofacial surgery.* 2018 Sep;22(3):315-321. PMID: 30109520 DOI: 10.1007/s10006-018-0713-y
 35. Ogundare BO, Bonnick A, Bayley N. Pattern of mandibular fractures in an urban major trauma center. *J Oral Maxillofac Surg.* 2003;61:713–8. PMID: 12796884 DOI: 10.1053/joms.2003.50118
 36. Teñ PA, Popa D, Juncar R, Lung T, Juncar M. Evaluation of clinical features of mandibular fractures and associated injuries. A 10-year retrospective study. *HVM Bioflux* 2016;8(4):182-186.
 37. Kraft A, Abermann E, Stigler R, Zsifkovits C, Pedross F, Kloss F et al. Craniomaxillofacial Trauma: Synopsis of 14,654 Cases with 35,129 Injuries in 15 Years. *Craniomaxillofac Trauma Reconstr* 2012;5(1):41–50. PMID: 27688419. doi: 10.15644/asc49/4/10
 38. Haug RH, Prather J, Indresano A. An epidemiologic survey of facial fractures and concomitant injuries. *J Oral Maxillofac Surg.* 1990;48:926–32. PMID: 2395044

How to cite this article:

Noha Abdelfattah Ahmed Madkour (2019) 'Utility of Multidetector Computed Tomography in Evaluation of Mandibular Fractures', *International Journal of Current Advanced Research*, 08(02), pp.17466-17469. DOI: <http://dx.doi.org/10.24327/ijcar.2019.17469.3315>
