



Research Article

**HEMANGIOAMELOBLASTOMA IN MANDIBLE: A RARE CASE REPORT
AND REVIEW OF LITERATURE**

Kanchan Shah., Prashant Raktade., Prashant Pandilwar., Abhishek Akare and Suday Rajurkar

Department of Oral and Maxillofacial Surgery, Government Dental College & Hospital, GHATI Campus, Aurangabad, Maharashtra

ARTICLE INFO

Article History:

Received 11th March, 2018
Received in revised form 6th April, 2018
Accepted 26th May, 2018
Published online 28th June, 2018

Key words:

Hemangioameloblastoma; Mandible; Jaws;
Treatment Outcome

ABSTRACT

Purpose: To analyze reported cases of hemangioameloblastoma with emphasis on treatment modalities.

Material and Methods: We report a case of a 45 year-old man with swelling over anterior region of mandible. This review also includes all published cases of hemangioameloblastoma and analyzed data of the patients, lesion site, treatment approach and events of recurrence.

Results: Only 11 patients of hemangioameloblastoma of jaws has been reported till date including this case. The primary treatment in all patients was radical surgery consisting of resection with clear margins.

Conclusions: Hemangioameloblastoma is aggressive tumor because of its vascularity and it is a variant of solid/ multicysticameloblastoma and not a collision tumor of ameloblastoma and vascular tumor. Treatment is same as we decided in solid or multicysticameloblastoma.

Copyright©2018 **Kanchan Shah et al.** This is an open access article distributed under the Creative Commons Attribution License, which permits unrestricted use, distribution, and reproduction in any medium, provided the original work is properly cited.

INTRODUCTION

Case Report

A 45-year-old male patient reported with a complaint of an asymptomatic swelling in the anterior region of the mandible. The patient noticed the swelling about 6 months ago which grew inconsequently to the present size over a period of 1 year. The past medical history was not contributory. The swelling was hard in consistency, non-tender and was not fixed to the overlying mucosa. No evidence of paraesthesia seen. The borders of the swelling were ill defined. Based on the patient's chief complaint, clinical examination and radiological finding, a provisional diagnosis of ameloblastoma was made and differential diagnosis of odontogenic keratocyst was proposed.

An orthopantomogram revealed a mixed radiopaque-radiolucent lesion with diffuse borders extending from the left second molar up to the contralateral premolar and from inferior border of mandible extending superiorly to involve the teeth. Computed tomography showed a mixed lesion with expansion of both cortical plates. There was also an evidence of break in the buccal and lingual cortex along the postero-inferior border of the mandible.

Incisional biopsy performed under local anesthesia gave a histopathological report of plexiform ameloblastoma. The patient underwent surgery under general anesthesia and using a lip split incision, the neoplastic growth was widely resected by segmental mandibulectomy with safe margins. Hemangioameloblastoma was final diagnosis.

DISCUSSION

Ameloblastoma is a benign epithelial odontogenic tumor that usually exhibits aggressive behavior. It expands severely to the cortical bones and may have a high recurrence rate. It is also known to cause mobility and displacement of the teeth, as well as root resorption. It is categorized based on clinico-radiological features into three types: solid or multicystic, unicystic, and peripheral.^{5,6} Odontogenesis is a complex process and any deviation from normal process results in odontogenic cysts and tumours. In ameloblastoma there is faulty differentiation of enamel organ to point of actual enamel formation.^{6,7}

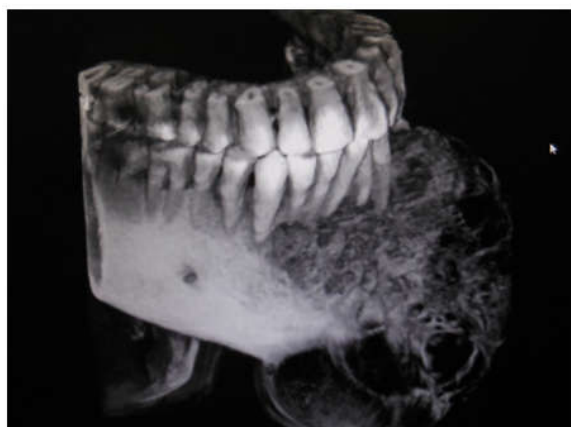
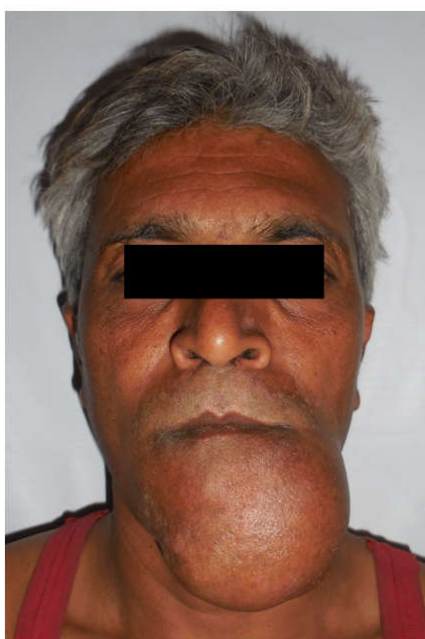Various histological variants of ameloblastoma have been described in the literature like follicular (most common), plexiform, acanthomatous, granular (most aggressive), basal cell and desmoplastic.⁸

*Corresponding author: **Kanchan Shah**

Department of Oral and Maxillofacial Surgery, Government Dental College & Hospital, GHATI Campus, Aurangabad, Maharashtra

Table 1 Comparison of various cases of hemangioameloblastoma

Case	author	Age/gender	Race	Location	Treatment	Follow-up
1	Aisenberg	48/F	White	Right posterior mandible	Enucleation	uneventful
2	Lucas RB	43/f	White	Right mandible	Resection of affected portion	Uneventful and no complaint after follow up
3	Van Rensburg LJ	26/f	White	Left mandible, 3rd molar region	Partial hemimandibulectomy Planned but patient refused	No follow up could be done
4	Ide F [2]	56/m	White	Anterior maxilla	Enucleation and curettage	Good healing after 6 months follow-up
5	Tamgadge AP	31/m	Asian	Left mandible premolar molar area	Enucleation and curettage	Good healing after 4 months follow-up
6	Sharma VK	15/	Asian	Maxillary right molar area	Enucleated	Followed for 6 months
7	Harshvardhan SJ	42/m	Asian	Right posterior mandible	Hemimandibulectomy	Uneventful and no complaint after followup for 2 years
8	Sarode GS	18/m	Asian	Right posterior mandible	curettage	Patient lost to follow-up
9	Rajmohan M		Asian	Right posterior mandible	Hemimandibulectomy	Patient lost to follow-up
10	Kasangiri	35/f	Asian	Left posterior mandible	Enucleation	Lost to follow up
11	Our case	30/m	Asian	Left posterior mandible	hemimandibulectomy	Uneventful and no complaint after followup of 6 month

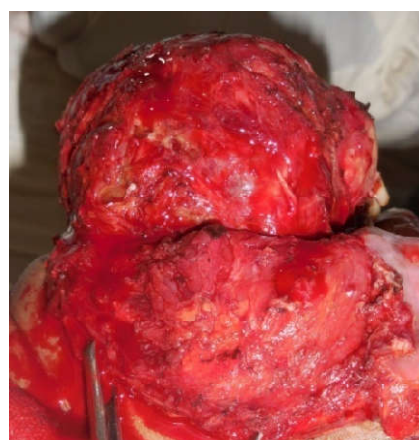

Ameloblastoma has many histological variants with follicular ameloblastoma the most common one. Reports of variants like clear cell, papiliferous, keratoameloblastoma and a very rare pattern hemangiomas ameloblastoma have also been described in the literature.⁹

Of the 11 reported cases including the present case, data of 11 cases has been obtained. Analysis of 11 cases has been done, gender distribution showed a male predilection, this differs from that ameloblastoma which reportedly has no gender predilection.

The age distribution of patients ranges widely from 15 to 54 years, with peak occurrence in the fourth and fifth decade of life. Hemangioameloblastomas appears to be more prevalent in Asians than in other racial groups. Of the 11 cases of hemangioameloblastoma reported to date, 9 were in the mandible and 2 in maxilla. All predilection were similar from classical ameloblastoma except gender it may be due the small cases reported.

The most common clinical presentation is asymptomatic swelling and aware only of painless swelling with no sign of local paresthesia. It may cause expansion of the mandible or maxilla. Radiographically, hemangioameloblastoma has been described as mixed radiolucent–radiopaque lesions with well demarcated borders and in some case with ill-defined borders. Root resorption of the teeth associated with the lesion was reported. CT scan clearly demonstrates cystic features in this tumor, such as its expansile nature and soft tissue contents. So Diagnosis of hemangioameloblastoma was not possible based solely on radiographic findings and usually relied on the histological results.



The hemangiomas ameloblastoma was originally described as an ameloblastoma in which part of the tumor contained spaces filled with blood or large endothelial-lined capillaries. The HA observed here differs histologically and radiologically from a conventional ameloblastoma. Histologically, it consists

of an ameloblastoma with a prominent vascular component while its conventional radiologic features are nonspecific.

As very few cases of hemangiomas ameloblastoma are reported, the origin of its vascular component is still debatable and not clearly understood. Few authors consider the vascularity as hamartomatous growth, few others as part of neoplastic process and others consider it as a separate neoplasm. Whereas Smith did not consider hemangiomas ameloblastoma as a separate variant of ameloblastoma as according to him the extensive vascularity might be owed to other causes.¹⁰

Various theories have been put forth to explain the pathogenesis of the vascular component in ameloblastoma. During amelogenesis, many capillaries are associated with the outer enamel epithelium. They furnish the profuse blood supply necessary for enamel completion. It is probable that in the HA these blood vessels are abnormally induced to become part of the tumor.² It is also said that excessive stimulation of angiogenesis during tumor development, by inductive influences such as those that occur during odontogenesis or by other factors, may result in the overgrowth of the vascular elements in the odontogenic ectomesenchyme or in the adjacent connective tissue.¹¹

Alternatively, a traumatic incident such as a tooth extraction may provide a stimulus required for proliferation of epithelial cell rests in the periodontal ligament and subsequent tumor development.² Tissue damage is usually followed by repair and this involves the formation of the granulation tissue in which proliferating endothelial cells and new capillaries are prominent. A disturbance in the repair of neoplastic odontogenic tissue may result in excessive granulation tissue formation or the development of an abnormal vascular component.¹¹

It has been suggested that the HA represents a collision tumor. In this type, two separate tumors grow in the same area and collide, and the tumor elements intermingle. Smith¹⁰, regarded the HA as histologically similar to one of the other recognized types of ameloblastoma and not as a distinct histologic entity. He thought the blood supply to these tumors was variable and that circumstances other than the number and size of the vessels influenced the blood supply. Whether the vascular component of the HA is part of the neoplastic process, represents a separate neoplasm, or is a hamartomatous malformation has not been satisfactorily resolved.

An adequate vascular system is critical for transporting oxygen, nutrients and eliminating metabolic waste products, and thus for maintaining tissue viability and growth. Under physiological conditions, a balance of pro- and anti-angiogenic factors prevails in tissue microenvironments. Nevertheless, in pathological conditions, such as tumor growth, an excessive angiogenesis is usually present.¹² Indeed, it has been hypothesized that tumor growth rates depend on capillary density and metabolic level.¹³ Hemangiomas ameloblastoma are thought to be less aggressive formally but now it considered an aggressive tumor and confirmed in our caseshows aggressive behavior of tumor.

There are three recognized clinical intraosseous ameloblastoma variants: unicystic (UA), solid/multicystic (SMA) and desmoplastic (DA). They are able to cause different degrees of esthetic and functional alterations, each

with different outcomes of treatment. Angiogenesis could also be involved in the particular conduct of SMA, as shown by a recent study reporting that this tumor exhibited a greater microvessel density than other odontogenic lesions analyzed. The hemangiomas ameloblastoma (HA) was originally described as an ameloblastoma in which part of the tumor contained spaces filled with blood or large endothelial-lined capillaries. On out of 11 cases reported in 7 cases microscopic examination revealed as plexiform ameloblastoma with a prominent vascular component and in one case revealed as follicular ameloblastoma with prominent vascular component. So 8 out of 11 (72,70.%) HA tumors resemble a feature of solid/multicystic ameloblastoma.

Lucas¹⁴ believed that the unusual vascularity is due to the entire absence of vasoformative activity. According to him, in the process of formation of stromal cysts in the ordinary type of plexiform ameloblastoma, the blood vessels often persist and dilate instead of disappearing. Thus, it's likely to represent a purely secondary change. It has also been suggested that the excessive stimulation of angiogenesis during tumor development, by inductive influences such as those that occur during odontogenesis or by other factors, may result in the overgrowth of vascular elements in the odontogenic ectomesenchyme or in adjacent connective tissue. It may be true because due to its extreme vascular component carry surgical complications.² But in our case no intraoperative bleeding occur as a complication and no one discussed in reported article till date the complication of intraoperative bleeding unlike the vascular tumor. So it confirmed it may be a just variant of ameloblastoma rather collision tumor.

As we considered from above discussion, hemangiomas ameloblastoma is variant of solid/ multicystic ameloblastoma. The recommended treatment for this lesion is wide surgical excision without embolization or block the feeder arteries. As no malignant transformation seen till date adjuvant radiotherapy and chemotherapy may not require. In spite of no recurrence was seen in previous cases after enucleation but most of the cases operated by enucleation either they lost follow up or on minimum follow up.

CONCLUSION

Hemangiomas ameloblastoma is rare variant of odontogenic tumour. The origin of its vascular component is still debatable and not clearly understood but now we conclude that hemangiomas ameloblastoma is aggressive tumor because of its vascularity and it is a variant of solid/ multicystic ameloblastoma and not a collision tumor of ameloblastoma and vascular tumor. Treatment for Hemangioameloblastoma is the same as solid or multicystic ameloblastoma viz Aggressive resection with adequate safe margins and long term follow up.

References

1. Hemangioameloblastoma: A rare presentation. Karagir A, Ranpise SG. Jr of Indian Academy of oral medicine and radiology. 2011, 23(4), 641-643.
2. Aisenberg MS. Adamantiohemangioma. *Oral Surg Oral Med Oral Pathol* 1950; 3: 798-801.
3. Thoma KH. Oral pathology. St Louis: Mosby; 1944
4. Hemangiomas Ameloblastoma- A Case Report of a Very Rare Variant of Ameloblastoma. Kasangari MD1, GundamarajuK, JyothsnaM, SubashAV, Aravind K

- Journal of Clinical and Diagnostic Research*. 2015, 9(5): ZD08-ZD10.
5. Tamgadge AP, Sirur DG, Bhalerao SS, Pariera T, Tamgadge SA. Hemangiomas of Ameloblastoma: A case report of a rare variant of ameloblastoma. *Int J Contemp Dent*. 2010; 2:16-19.
 6. Ide F, Horie N, Shimoyama T, Sakashita H. So-called hybrid odontogenic [2] tumours: Do they really exist. *Oral Med Patol*. 2001; 6:13-21.
 7. Shafer WG, Hine MK, Levy BM. Cysts and tumours of odontogenic origin. [3] Shafer's Textbook of Oral Pathology (5th ed). New Delhi: Elsevier 2005; 395-98.
 8. Krammer IR, Pindborg JJ, Shear M. Histological typing of odontogenic Tumours. Berlin: Springer-Verlag; 1992. pp. 11-14.
 9. Neville BW, Damm DD, Allen CM, Bouquot JE. Oral and maxillofacial Pathology. *Oral Surg Oral Med Oral Pathol*. 1995; 3:798-801.
 10. Smith JF. The controversial Ameloblastoma. *Oral Surg Oral Med Oral Pathol*. 1968; 26:45-75.
 11. Reichart PA, Phillipsen HP. Odontogenic tumors and allied lesions. London: Quintessence publishing co ltd 2004; 52-53.
 12. T. Schmidt, P. Carmeliet, Angiogenesis: a target in solid tumors, also in leukemia? *Hematology Am. Soc. Hematol. Educ. Program* 2011 (2011) 1-8.
 13. S.E. Giusca, F.E. Zugun, E. Tarcoveanu, E. Carasevici, C. Amalinei, I.D. Caruntu, Immunohistochemical study of colorectal cancer liver metastases: the immune/inflammatory infiltrate, *Rom. J. Morphol. Embryol*. 51 (2010) 73-79.
 14. Lucas RB. A vascular ameloblastoma. *Oral Surg Oral Med Oral Pathol* 1957;10:863-8.

How to cite this article:

Kanchan Shah *et al* (2018) 'Hemangioameloblastoma in Mandible: A Rare Case Report and Review of Literature', *International Journal of Current Advanced Research*, 07(6), pp. 13430-13433.
DOI: <http://dx.doi.org/10.24327/ijcar.2018.13433.2397>
