

**SKELETAL AND DENTAL CLASS II CORRECTION AT ADOLESCENT AGE: FUNCTIONAL V/S FIXED FUNCTIONAL APPLIANCE- CASE REPORTS**

**Poonam Patel\*, Kratika Mishra., Amit Bhardwaj and Rakesh Thukral**

Department of Orthodontics and Dentofacial Orthopaedics, Modern Dental College and Research Centre, Indore

**ARTICLE INFO**

**Article History:**

Received 24<sup>th</sup> February, 2018

Received in revised form 19<sup>th</sup>

March, 2018 Accepted 16<sup>th</sup> April, 2018

Published online 28<sup>th</sup> May, 2018

**ABSTRACT**

Various treatment approaches are available for management of class II malocclusion. Functional jaw orthopaedics in growing individuals can result in a broad beautiful smile, an excellent functional occlusion and noticeably improvement in profile. Following are case series of patients with twin block appliance and fixed functional appliance (power scope) in young age. Significant results can be obtained with proper case selection and patient compliance.

**Key words:**

Class II malocclusion, Functional appliance, Twin block appliance, fixed functional appliance, power scope

*Copyright©2018 Poonam Patel et al. This is an open access article distributed under the Creative Commons Attribution License, which permits unrestricted use, distribution, and reproduction in any medium, provided the original work is properly cited.*

**INTRODUCTION**

Class II malocclusion presents a major and common challenge to present day orthodontics. Mandibular retrusion is one of the most common characteristics.<sup>1</sup> Functional appliance therapy plays an important role in treating such cases. Various Removable and fixed functional appliances have been reported in literature for advancement of mandible.<sup>2,3</sup>

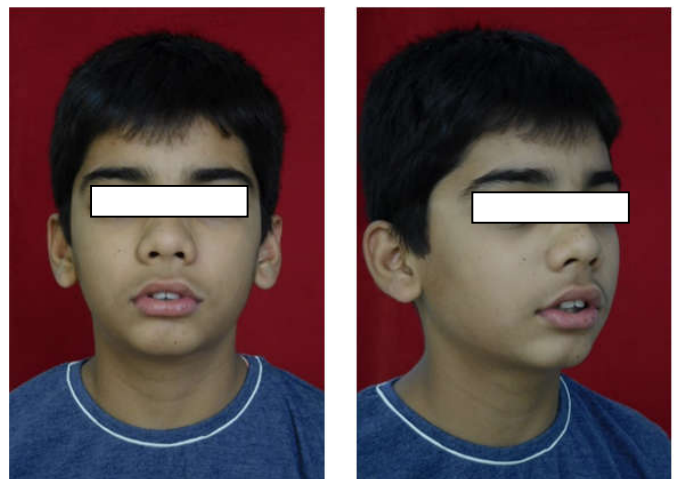
Myofunctional appliances works on the principle of force elimination and force application. In 1977, functional appliance therapy evolved with the development of twin block appliance by Dr. William Clark, representing significant transition from one piece appliance to twin appliance that promotes normal function<sup>4</sup>.

A variety of Fixed Functional appliances, that doesn't require patient compliance have been designed by different clinicians.<sup>4</sup> PowerScope is a recently developed noncompliant hybrid fixed functional appliance that holds the mandible anteriorly and corrects the Class II anteroposterior discrepancy

During the past few years treatment with Twin-block and Forsus (FRD) functional appliances have been widely used. So, this case report compares the skeletal, dental and soft tissue changes obtained by Twin-block and fixed functional appliance (power scope) appliances in the correction of Angle's Class II division malocclusions.

**Case Report: 1**

A 12-year-old male patient came to the department with a complaint of forwardly placed upper front teeth. On extra-oral examination, the patient had mesoprosopic facial form with convex facial profile. The nasolabial angle was acute with incompetent lips with an interlabial gap of 5 mm, and horizontal growth pattern (Fig. 1). The clinical FMA was low. He had positive VTO on advancement of the mandible to edge to edge bite (Fig 2 & 3). On intra-oral examination (Fig 4), patient had permanent dentition, it showed Angle's class II molar relation, class II canine relation bilaterally, overjet of 7 mm,



**Figure 1** Pre-treatment photograph

\*Corresponding author: **Poonam Patel**

Department of Orthodontics and Dentofacial Orthopaedics, Modern Dental College and Research Centre, Indore

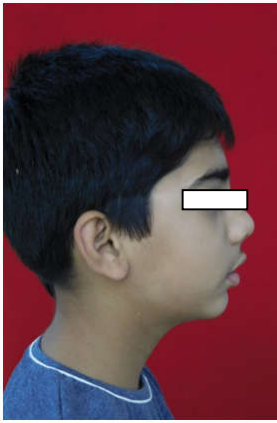


Figure 2 Pre-treatment

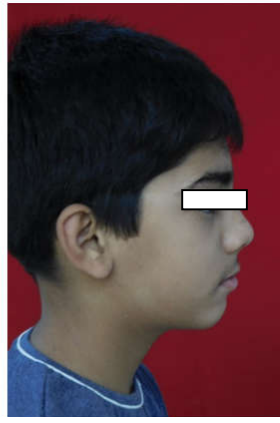


Figure 3 Positive VTO profile

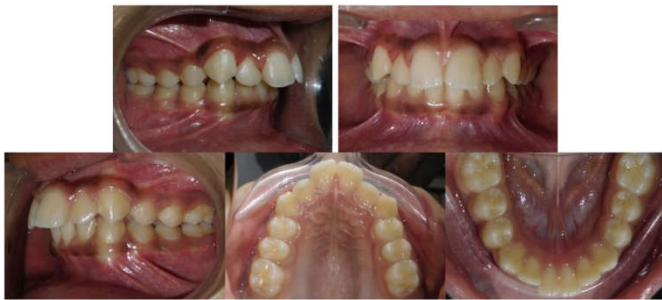

Figure 4 Pre-treatment intra-oral photographs

The overbite was increased to 3 mm. The case was diagnosed as Class II skeletal malocclusion with mandibular deficiency and maxillary dental proclination. The lateral cephalometric findings (Figure 5) were an increased ANB ( $5^\circ$ ) with normal SNA angle and SNB was reduced indicating a normal maxilla and retrognathic mandible. The Wits appraisal (+4 mm) confirmed that the patient had a Class II skeletal pattern. Lower incisors were normally angulated while the upper incisors were proclined. According to Tanner and White, skeletal maturation Index (Figure 5) was G stage which indicated peak pubertal growth spurt.

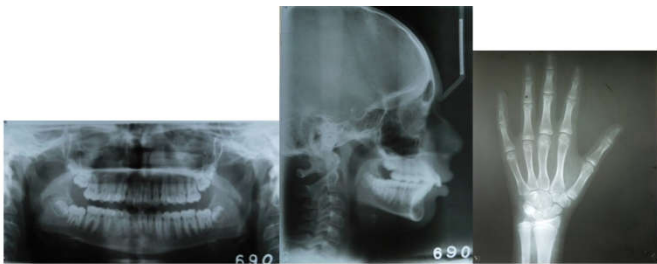


Figure 5 Pretreatment Orthopantomogram and lateral cephalogram and hand-wrist radiograph

**Treatment objective**

1. Reduction of profile convexity and lip incompetence.
2. Achieve skeletal class I by growth modification with functional appliance.
3. Achieve Angle's class I molar, class I Canine and Incisor relation.

**Treatment plan**

Growth modification was planned using functional appliance followed by fixed orthodontic appliance for final detailing of occlusion.

**Treatment progress**

Twin block (Myofunctional appliance) was fabricated for the patient (Figure 6). To prevent further proclination of lower incisors, acrylic capping was done. After a 10 months period of wear, there was significant improvement in profile and lip competency (Figure 7). Significant correction in molar and the canine relation was obtained along with reduction in overjet and overbite (Figure 8).

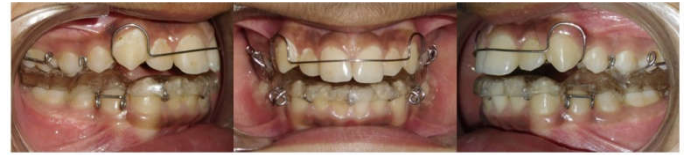

Figure 6 Intra-oral images with twin block

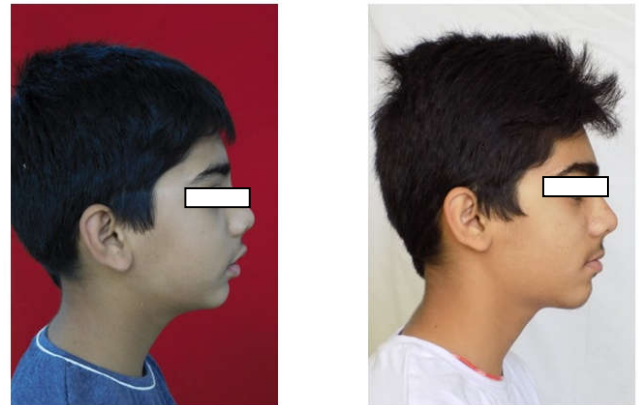


Figure 7 Comparison of the pre and post-treatment profile

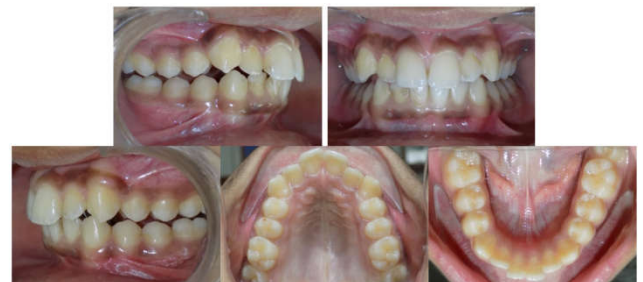

Figure 8 Post twin block intra-oral images

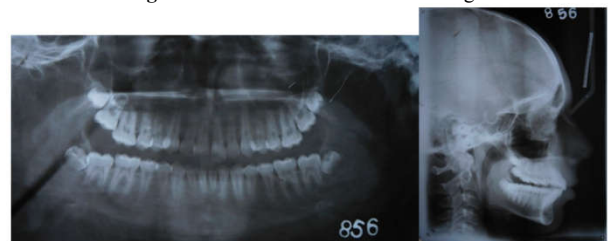


Figure 9 Post treatment lateral cephalogram

Table 1 Comparison of pre and post treatment parameters

Parameter	Pre treatment	Post treatment
SNA	80	80
SNB	75	78
ANB	5	2
SN-GOGN	28	28
MX length	85	85
Md length	105	110
Nasolabial angle	102	105
IMPA	100	105
U1-NA (angle)	36	35
U1-NA (mm)	10	9
U1-SN (angle)	111	110
L1-NB(angle)	27	30
L1-NB(mm)	5	7
Interincisal angle	105	110

**Treatment Results**

Twin block to produce significant skeletal and dentoalveolar changes which in combination correct Class II malocclusion. Here, comparison of pre-treatment and post-treatment lateral cephalogram (Figure 5 and 9) showed SNA remains unchanged, SNB increased by 3° and there is decrease in ANB angle by 3°. Mandibular incisors were proclined by 5°. Length of the mandible is increased by 3 mm (Table 1).

**CONCLUSION**

In the pursuit of ideals in orthodontics, facial balance and harmony are equally important in aesthetic and occlusal perfection. The functional jaw orthopaedics is important in achieving these goals by growth guidance during the formative years of facial and dental development. But it should not be expected that all patients who undergo functional appliance therapy will show an increased mandibular growth compared to norms for their age.

**Case Report: 2**

A 13 year old female presented with a chief complaint of forwardly placed upper front teeth. Clinical examination revealed convex profile with posterior divergence, recessive chin and protrusion of the upper lip [Figure 10]. The patient presented with Class II, Division 1 malocclusion with an overjet of 6 mm and an overbite of 3 mm.

Cephalometric analysis revealed a convex skeletal profile with ANB angle of 6°, a retruded mandible, and a well-positioned maxilla [Figure 10]. Dentoalveolar readings suggested proclined upper anterior teeth. The mandibular plane angle was normal, suggesting an average growth pattern. Handwrist X-rays indicated that the patient’s growth was not completed. [Figure 12]

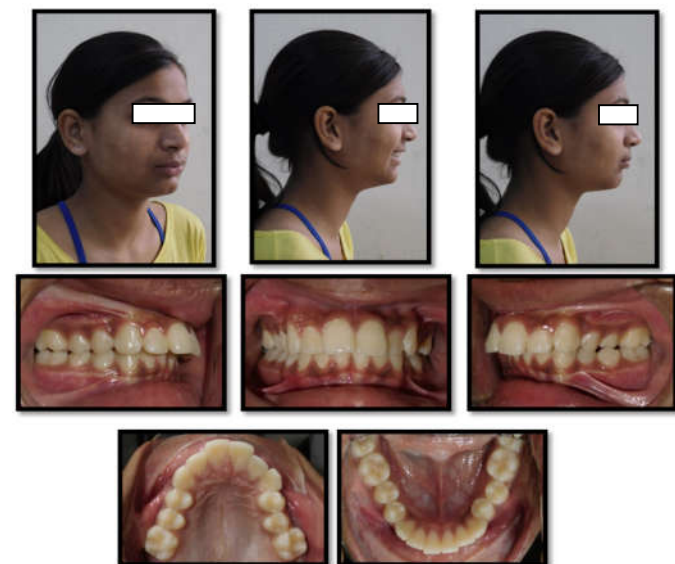

Figure 10 Pretreatment Photographs

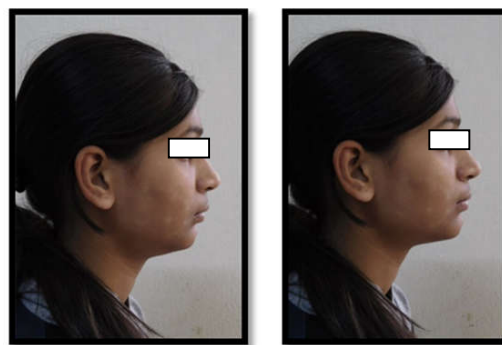

Figure 11 Positive VTO

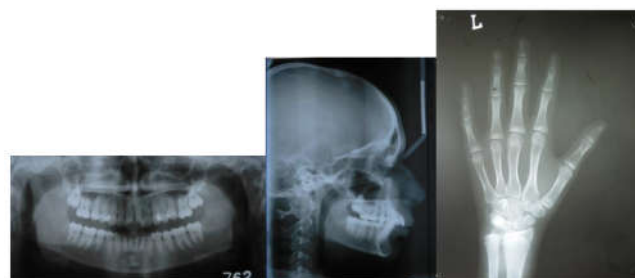


Figure 12 Pretreatment X- rays

**Treatment objectives**

1. Obtain asymmetrical Class I occlusion ruling out extractions
2. Improve facial profile by accentuating mandibular growth
3. Restrict maxillary growth in sagittal and vertical plane
4. Avoid any undue backward rotation of the mandible.

**Treatment plan**

A nonextraction approach was planned using MBT 0.022” slot preadjusted appliance. After levelling and aligning, Powerscope (fixed functional appliance) was chosen to advance the mandible into a Class I relationship followed by finishing and detailing.

**Treatment Progress**

Orthodontic treatment was started with 0.022” X 0.028” Preadjusted Edgewise System. An initial 0.014-inch round nickel titanium archwire was used for levelling and alignment of both arches. Upper and lower 0.019” x0.025” stainless steel wires were placed in both arches. The mandible was positioned to a Class I molar relationship with Powerscope inserted bilaterally for a period of 8 months. [Figure 13]

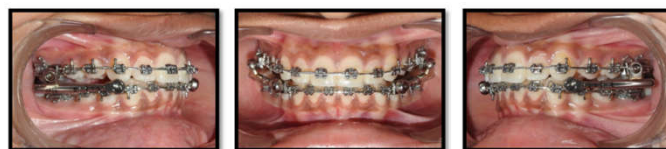

Figure 13 Powerscope Appliance

**TREATMENT RESULTS**

The facial profile of the patient post treatment demonstrated improvement with improved facial esthetics and straight facial profile. The intraoral occlusion revealed satisfactory result with bilateral Class I canine and molar relationship with good buccal interdigitation. Overjet and overbite were reduced to 2 mm and 2mm, respectively.[Figure 14]

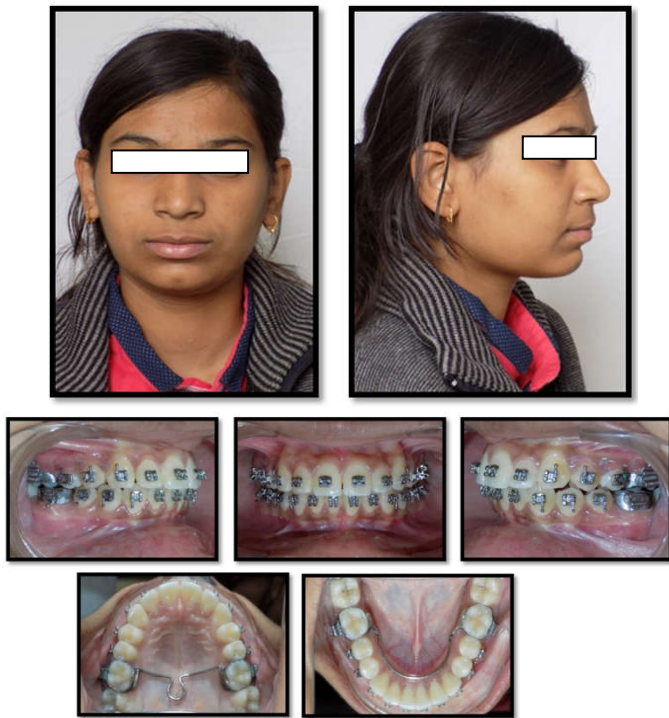

Figure 14 Post treatment photographs

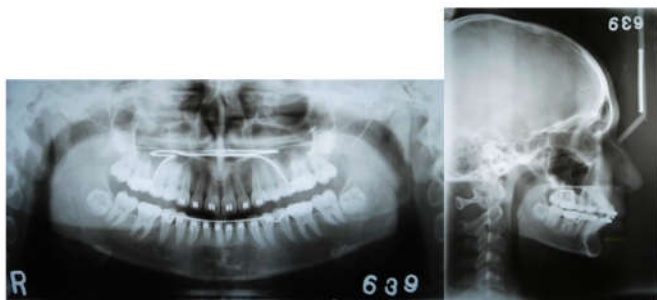


Figure 15 Post-treatment x ray

Table 2 Comparison of pre and posttreatment parameters

Parameter	Pretreatment	Posttreatment
SNA	81	81
SNB	76	77
ANB	5	4
SN-GOGN	21	21
MX length	83	87
Md length	110	110
Nasolabial angle	103	108
IMPA	100	105
U1-NA (angle)	35	32
U1-NA (mm)	12	10
U1-SN (angle)	118	114
L1-NB(angle)	27	30
L1-NB(mm)	5	7
Interincisal angle	114	105

## DISCUSSION

### Cephalometric Findings

Angle's Class I molar relationship was achieved; overjet and overbite were decreased in both the functional appliances. The SNB angle increased significantly in the Twin-block therapy (3°) compared with the Power scope therapy patient. (1°) The ANB angle demonstrated a significant decrease. (SNA unchanged and SNB and Go-Me increased).

In Twin-block therapy, the ANB angle reduced by 3°, mandibular length increased by 5mm, maxillary length unchanged, whereas with power scope case ANB angle reduced by 1°, maxillary and mandibular length was unchanged. The skeletal vertical parameters showed an increase in the lower anterior facial height in both Twin-block and power scope therapy.

### Dentoalveolar Changes

Dental parameters revealed similar alterations in both the treatment. Maxillary incisors were retroclined, extruded, and distally tipped, whereas the mandibular incisors were proclined, intruded, and labially tipped. In myofunctional appliance therapy maxillary molar teeth were distalized and extruded whereas in Power scope they were distalized and intruded. Contrary, lower molars were moved mesially and extruded in both treatment therapies.

### Soft-tissue Changes

Changes were significantly observed in both the patients, Improvement in the profile was attained with use of both the appliances because of the significant increase in the soft-tissue convexity and nasolabial angle.

## CONCLUSIONS

- Both the Twin Block and power scope induced mandibular growth, but Twin-block induced more mandibular growth than the power scope. Both functional appliances showed no significant effect on restricting the forward growth of the maxilla.
- Significant decrease in overjet and overbite were observed at the end of treatment in the Twin-block and power scope patient.
- The Twin block appliance produced both skeletal and dentoalveolar changes.
- Power scope produced more dentoalveolar effects.
- Soft-tissue profiles improved significantly, reflecting the changes that took place in the Skeletal and dentoalveolar structures. These soft-tissue changes helped improve convex facial profile.

## References

1. McNamara JA Jr. Components of class II malocclusion in children 8-10 years of age. *Angle Orthod* 1981; 51:177-202.
2. Graber TM, Rakosi T, Petrovic A. *Dentofacial Orthopedics with Functional Appliances*. St Louis, Mo: Mosby; 1997:346-352.
3. Proffit WR. *Malocclusion and dentofacial deformity in contemporary society*. Contemporary Orthodontics. 4th ed. St. Louis: Mosby Elsevier; 2007. p. 3-23.
4. Trenouth MJ. A comparison of Twin Block, Andresen and removable appliances in the treatment of Class II Division I malocclusion. *Funct Orthod* 1992; 9 (4): 26-31.

\*\*\*\*\*