



Research Article

ADENOMATOID ODONTOGENIC TUMOR AT AN UNUSUAL SITE MIMICKING PERIAPICAL CYST

Sanjeev Laller*¹, Mamta Malik², Kanwalpreet Kaur³ and Sunny Kala⁴

^{1,2}Oral Medicine and Radiology Department, PDM Dental College & Research Institute, Bahadurgarh, Haryana, India

³BJS Dental College Ludhiana, Punjab, India

⁴Oral Pathology, Microbiology and Histology Department, PDM Dental College & Research Institute, Bahadurgarh, Haryana, India

ARTICLE INFO

ABSTRACT

Article History:

Received 24th February, 2018

Received in revised form 19th

March, 2018 Accepted 16th April, 2018

Published online 28th May, 2018

Key words:

Adenomatoid Odontogenic tumor, AOT, Hamartomatous, Periapical cyst

Adenomatoid odontogenic tumor (AOT) since years has been a subject for diligent research by Oral Medicine and Radiologists and Oral Pathologists in the past. Adenomatoid odontogenic tumor is a benign hamartomatous slow growing neoplasm of epithelial origin composed of odontogenic epithelium in a variety of histoarchitectural patterns, embedded in a mature connective tissue stroma and characterized by slow but progressive growth. We present a case report on Adenomatoid odontogenic tumor mimicking periapical cyst and at unusual site of posterior mandible with erupted teeth. This case of AOT introduces us to the unique variation in its presentation and the difficulty in differentiation from periapical disease of inflammatory origin.

Copyright©2018 **Sanjeev Laller**. This is an open access article distributed under the Creative Commons Attribution License, which permits unrestricted use, distribution, and reproduction in any medium, provided the original work is properly cited.

INTRODUCTION

Adenomatoid odontogenic tumours (AOT) are uncommon odontogenic lesions characterized histologically by duct-like structures derived from the epithelial component of the lesion and can be distinctly classified into follicular, extrafollicular and extraosseous variants. Most of these tumours develop in the second or third decade of life and have a distinct predilection for women. The follicular variant accounts for 75% of reported cases and is associated with the crown of an impacted tooth, commonly the maxillary canine.^{1,2}

Adenomatoid odontogenic tumor (AOT) is benign epithelial lesion of odontogenic origin, representing approximately 0.1 percent of tumours and cysts of the jaw and 3% of all odontogenic tumors. The tumor occurs more frequently in females with a ratio of 2:1, and appears most often in the second decade of life. The maxilla is involved nearly twice as frequently as the mandible. Unerupted permanent teeth were associated with this lesion in one-third of the cases. In a few cases, more than one unerupted tooth was associated with the tumour. Described for the first time by Dreibrat in 1907 as an adenoameloblastoma, and among others has also been named ameloblastic adenomatoid tumor.

In 1969 Philipsen and Birn proposed the term AOT, indicating that it did not constitute a variety of ameloblastoma, and was accepted as such in the first WHO classification of odontogenic tumors established in 1971.

The term AOT is without doubt the most appropriate, in that these tumors are clearly benign and, in contrast to the ameloblastoma, present a very low recurrence making it unnecessary to carry out extensive and aggressive surgery; a simple curettage in conjunction with the extirpation of the associated tooth being the indicated treatment.^{3,4,5,6,7,8}

Here we present a case report on Adenomatoid odontogenic tumor mimicking periapical cyst and at unusual site of posterior mandible with erupted teeth.

Case report

A 25 year old Female patient, Mrs. Asha Devi presented to department of oral medicine and radiology, KD Dental College and Hospital, Mathura; with chief complaint of swelling in lower left back region of mouth since 1-1/2 years. History dates back to 1-1/2 years back when patient noticed the swelling on lower left back region of mouth. Swelling slowly and gradually increased to its present size and was not associated with pain, with no difficulty in swallowing and no secondary changes like ulceration and softening were noticed. Patient also revealed that twice she underwent aspiration of the lesion 6 and 4 months back respectively, from a local Dentist, but the swelling was relieved temporarily for some time and

*Corresponding author: **Sanjeev Laller**

Oral Medicine and Radiology Department, PDM Dental College & Research Institute, Bahadurgarh, Haryana, India

then again attain the present size. General physical examination revealed that patient was moderately built and nourished, mentally sound and all her vital signs were within normal limits. On extra oral examination of the swelling the inspeactory finding revealed that a solitary diffuse swelling is present on left lower 1/3 of face extending superiorly from left lower lip and corner of mouth to inferiorly 0.5cm above inferior border of mandible; anteriorly the swelling extends 1.5cm away from midline to middle of the body of mandible; measuring about 1.5X1.5 cm with smooth surface, ill-defined edges, and skin over swelling is smooth with no rise in local temperature (Figure-1).

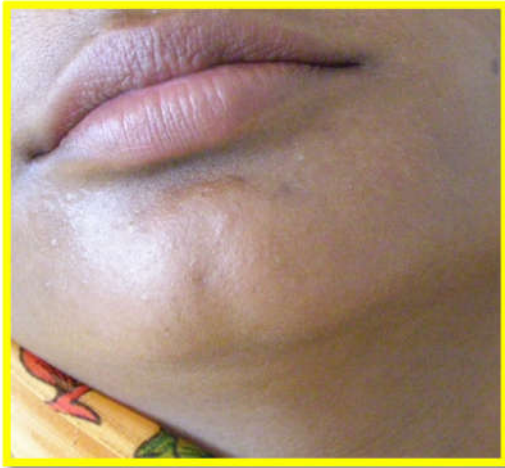

Figure 1 Extra-oral view of swelling

Whereas on palpation, swelling is hard in consistency, non tender, with no change in the surrounding area. Cervical lymph nodes were not palpable. On intra-oral examination (Figure-2), swelling was noticed on buccal vestibule of lower left canine, premolar, 1st molar region.

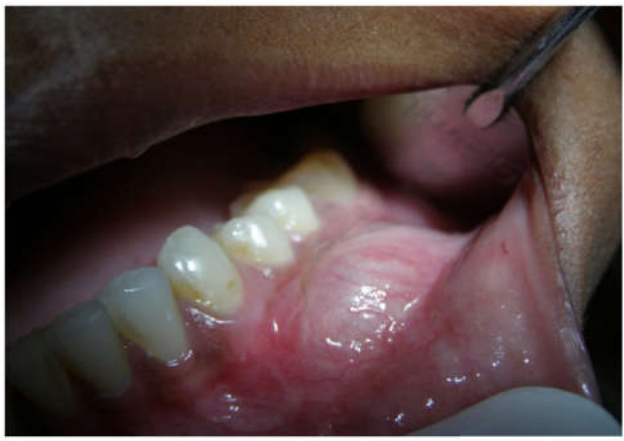

Figure 2 Intra-oral view of swelling

Swelling extends from distal aspect of 33 to mesial aspect of 36. Swelling was solitary, ovoid with clearly defined edges, and was same in color as that of oral mucosa was not ulcerated. On palpation Swelling was hard, non tender, with raised surface and egg shell crackling was appreciated. There was expansion of buccal cortical plates w.r.t. 33,34,35. Pulp vitality testing was done and 34 and 35 were found non-vital. Thus on the basis of history taking and clinical examination A Provisional Diagnosis of *Radicular Cyst in relation to 33 and 34* was put forth.

Under investigatory procedures blood investigations were carried out and were found within normal limits. Radiographic

features (Figure-3 & 4) suggests a unicystic/unilocular lesion which showed a well defined round to ovoid radiolucency surrounded by a radiopaque border, seen with respect to distal cervical margin of 33, involving radicular area of 34,35 and extending till mesial cervical margin of 36. The cystic lesion was seen displacing the roots of 34 and 35 and also seen extending buccally by expanding the buccal cortical plates. Fine needle aspiration was carried out and yellow colored fluid was obtained and the microscopic examination revealed histiocytes, mast cells; polymorph macrophages and few foam cells were present. 33,34 and 35 teeth were extracted & Excisional biopsy was carried out.

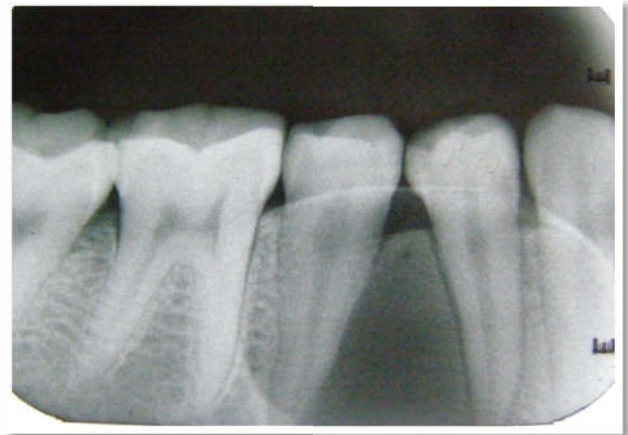

Figure 3 IOPA shows well defined radiolucency with corticated margins

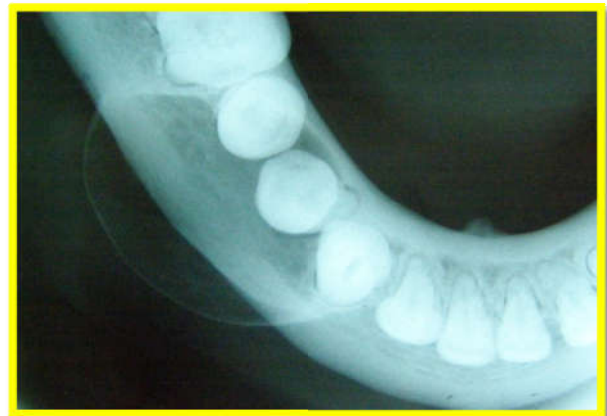

Figure 4 lateral occlusal view shows expansion of buccal cortical plate

Specimen was collected and send for histopathological examination. The section shows cystic lumen lined by thin stratified squamous epithelium supported by connective tissue capsule. The lining epithelium shows proliferation of spindle shaped cells in the form of whorled pattern and few areas also show the cells arranged in ductal pattern with the islands of cells in areas contain eosinophilic material. Also seen are foci of calcifications in some areas (Figure-5).

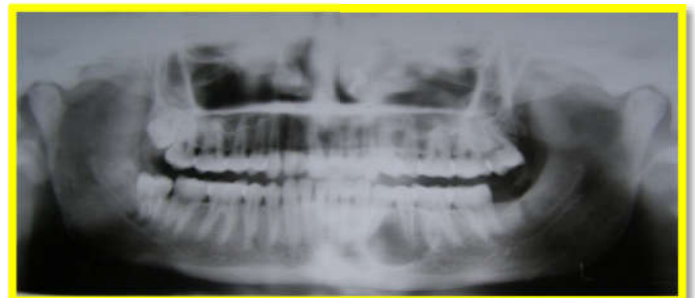


Figure 5 OPG shows well defined Unilocular radiolucency with corticated margins

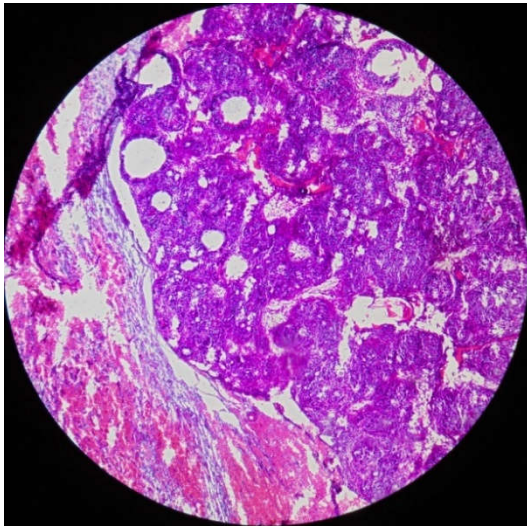


Figure 6 (A) Histological features

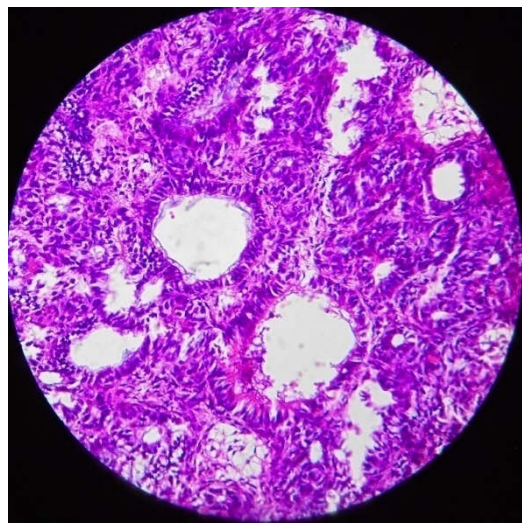


Figure 6(B) Histological features

Based on history, clinical examination, & investigations final diagnosis of “Adenomatoid odontogenic tumor of left side of mandible involving 33,34,35”. After excisional biopsy the tumor cavity was filled with Gelfoam and mucoperosteal flap was placed. Healing was uneventful with no history of recurrence after surgery. 6 months post surgery prosthetic rehabilitation was done by fixed prosthesis in 33,34 and 35 region.

DISCUSSION

Adenomatoid Odontogenic Tumor (AOT) is an epithelial tumor with an inductive effect on odontogenic ectomesenchyme. It is a relatively uncommon well circumscribed Odontogenic neoplasm characterized by formation of multiple duct like structure by the epithelial component of the lesion. It is also known by other names like Adenoameloblastoma and Ameloblastic Adenomatoid tumor. Adenomatoid odontogenic tumour accounts for about 3-7% of all odontogenic tumours.^{1,9,10}

The name Adenomatoid means adenoma like i.e. a benign epithelial structure in which the cells are derived from glandular epithelium or have a resemblance to the glandular epithelium. In AOT the name is given because histologically numerous duct like structure are often interspersed throughout the lesion which gives a glandular i.e. Adenomatoid appearance. AOT is derived from the remnants of dental

lamina. They arise from the remnants of dental lamina during tooth formation. After completion of odontogenesis the epithelial residues will either disintegrate or proliferate into tumor elements. AOT has odontogenic epithelium with odontogenic ectomesenchyme with or without hard tissue formation. It occurs at 10- 19 years of age and is more common in second decade. Female are affected twice more commonly than males and occur on anterior portion of jaws twice more common in maxilla than mandible whereas as in our case it was in posterior part of mandible involving 34, 35 and 36. The size may vary from 1.5- 2 cm mainly. Although larger lesions are present i.e. 7 cm.^{1,9,10}

They are painless and asymptomatic and the larger lesion causes painless expansion of bone. It may appear clinically as a well defined swelling. Clinical Types includes Central type (within the bone) with further *Follicular subtype* - Associated with the follicular space of unerupted tooth and *Extra follicular subtype* - Associated with the roots of erupted teeth as was seen in the case reported. Other type is Peripheral type (the Extra osseous form). It mostly appear on gingiva as a small sessile masses on the facial gingiva of the maxilla.^{1,9,10}

Radiographically they usually appear as unilocular lesion, may contain fine calcifications with or without root resorption. This appearance must be differentiated from various types of disease, such as calcifying odontogenic tumor or cysts. The differential diagnosis can also be made with ameloblastoma, ameloblastic fibroma and ameloblastic fibro-odontoma. The tumor is well-encapsulated and shows an identical benign behavior. Therefore, conservative surgical enucleation produces excellent outcome without recurrence.^{11,12}

CONCLUSION

Adenomatoid odontogenic tumor (AOT) is an uncommon benign odontogenic lesion that affects young patients, with female predominance, mainly in second decade, showing a radiolucent unilocular image associated with an unerupted tooth, usually a canine. The case presented by us was mimicking periapical lesion and was at unusual site. It is important for both the surgeon and the endodontist to be aware of this variation, so as to be in a position to identify future cases of this entity and to resolve issues concerning its association with preexisting periapical disease of inflammatory origin, if any.

References

1. Neville BW, Damm DD, Allen CM, et al. *Adenomatoid Odontogenic Tumor. A Text Book for Oral and Maxillofacial Pathology*, 2nd edition, 621-3.
2. Curran AE, Miller EJ, Murrah VA. Adenomatoid odontogenic tumor presenting as periapical disease. *Oral Surg Oral Med Oral Pathol Oral Radiol Endod* 1997; 84:557-60.
3. Cossío I, Rodríguez-Armijo Sánchez L, García Calderon M, Gutiérrez Pérez JL, González Cámpora R. Tumor odontogénico adenomatoide de maxilar superior. *Med Oral* 1997; 2(3):168-71.
4. Toida M, Hytado I, Okuda T. Adenomatoid odontogenic tumor: report of two cases and survey of 126 cases in Japan. *J Oral Maxillofac Surg* 1990; 48 (4):404-8.
5. Philipsen HP, Birn H. The adenomatoid odontogenic tumour. *Ameloblastic adenomatoid tumour* or

- adenoameloblastoma. *ActaPatholMicrobiolScand* 1969; 75 (3):375-98.
6. Philipsen HP, Reichart PA, Zhang KH, Nijai AH, Yu QX. Adenomatoid odontogenic tumor: biologic profile based on 499 cases. *J Oral Pathol Med* 1991; 20(4):149-58.
 7. MuraliS, Sekar B, Dominic Augustine. Adenomatoid Odontogenic Tumor mimicking an Odontogenic cyst - A case report. *JIADS VOL -1 Issue 4 October - December, 2010*.
 8. Kannan A1, Sumathy C2, Bojan A 3, Sathasivasubramanian S4. Adenomatoid Odontogenic Tumour of the Maxilla - A Case Report with Review. *J Oral Health Comm Dent* 2014;8(1)55-57.
 9. Shafer, Hine and Levy. Textbook of Oral Pathology edited by B Sivapathasundharam; 8th edition, Elsevier publication.
 10. Larsson A, Swartz K, Heikinheimo K. A case of multiple AOT-like jawbone lesions in a young patient - a new odontogenic entity? *J Oral Pathol Med* 2003; 32(1):55-62.
 11. Motamedi MH, Shafeie HA, Azizi T. Salvage of an impacted canine associated with an adenomatoid odontogenic tumour: a case report. *Br Dent J* 2005; 199(2):89-90.
 12. S Loganathan, H Srinivasan, R Veerakumar, M Arul Pari. Follicular Adenomatoid Odontogenic Tumor. *Indian Journal of Clinical Practice*, Vol. 23, No. 9 February 2013.

How to cite this article:

Sanjeev Laller *et al* (2018) 'Adenomatoid Odontogenic Tumor at an Unusual Site Mimicking Periapical Cyst', *International Journal of Current Advanced Research*, 07(5), pp. 13011-13014. DOI: <http://dx.doi.org/10.24327/ijcar.2018.13014.2309>
