



OCCULAR MANIFESTATIONS OF A COLLODION BABY – A CASE REPORT

Rahul Mistry and Daniel Varte

Gauhati Medical College, Bhangagarh, Gauhati

ARTICLE INFO

Article History:

Received 20th February, 2018

Received in revised form 20th

March, 2018 Accepted 8th April, 2018

Published online 28th May, 2018

Key words:

Lamellar ichthyosis, bilateral ectropion

ABSTRACT

Aim: Ichthyosis is an infrequent clinical entity worldwide (1:3,00,000 births). When diagnosed in a newborn, two forms can be identified: Collodion baby and its most severe form, Harlequin fetus or maligna keratoma. Both cases shows manifestations of thick and hard skin with deep splits. The splits are more prominent in the flexion areas. **Case:** A 3-day-old baby who was in Neonatal ICU was examined by us. He was having severe bilateral ectropion of the upper and lower lids and chemosis of conjunctiva, without corneal involvement. There was distortion of the pinna and peeling of the skin, more over the chest around the neck region and over the flexor aspect of limbs. **Conclusion:** Management of collodion baby requires a multi-disciplinary approach

Copyright©2018 Rahul Mistry and Daniel Varte. This is an open access article distributed under the Creative Commons Attribution License, which permits unrestricted use, distribution, and reproduction in any medium, provided the original work is properly cited.

INTRODUCTION

In Collodion membrane, baby's skin is replaced by a cornified substance of uniform texture, which gives the body a varnished appearance. The most important clinical data concerning collodion baby is the presence of disseminated or generalized ichthyosiform genodermatosis characterized by dry skin, scaling, generalized erythroderma and hyperkeratosis, reminiscent of fish scales. It is also known by Ichthyosis. Ichthyosis can be classified into three groups: 1) true ichthyosis, 2) ichthyosiform states and 3) epidemolytic hyperkeratosis. There several subtypes of each group. Among the true ichthyosis are three groups as follows: autosomal dominant ichthyosis (ichthyosis vulgaris, ichthyosis simple, fish skin disease), X-linked recessive ichthyosis (ichthyosis nigricans, ichthyosis of the male, saurodermia) and autosomal recessive ichthyosis (laminar ichthyosis, nonbullous congenital ichthyosiform erythroderma). Neonatal ichthyosis, in its most severe form, is known as harlequin ichthyosis, harlequin fetus or maligna keratoma. Harlequin ichthyosis is also a keratinization disorder with extremely rare autosomal recessive hereditary traits. The skin of the affected baby is markedly thick and hard (resembles cardboard) with deep grooves running both transversely and vertically. Hands and feet are hard and ischemic and there is poor development of the distal digital area. Most babies are premature at between 32 and 36 weeks of gestation. Complications include sepsis, distal gangrene and difficulty feeding and breathing.

Aspiration pneumonia of squamous cells in amniotic fluid is a potential complication. ABCA 12 gene (adenosine triphosphate binding cassette A 12), located at chromosome 2q33-q35, is recognized as the cause of lamellar ichthyosis and mutation of this gene as being responsible for harlequin ichthyosis. The frequency of collodion baby is very low. It is estimated that there are 1:300,000 cases of newborns in the worldwide.

CASE REPORT

A case of 3-day old boy was admitted in NICU, whose ocular examination was done by us. His parents complained of peeling of skin and some abnormality in both eyes. The child was born at a gestation age of 36 weeks after a normal vaginal delivery in GMCH. According to parents the child had a whitish covering over his body and he was admitted in NICU. On examination, there was white scale present all over body with peeling of skin more over the chest just below neck. Scales were present more on flexor aspect of arms. On ocular examination, severe ectropion of both upper lid was present with chemosis of palpebral conjunctiva as well as abundant hyaline type ocular secretion. Cornea was not involved and pupil was of normal size and normally reacting to light. Lens was clear and red glow was present. Fundus examination of both eyes was within normal limits. The child was advised a lubricating eye drop along with antibiotic eye drop. The child was kept in NICU under close observation. The child was discharged after 15 days when his condition was stable. We wanted to evaluate the child for ectropion but the patient lost to follow up.

*Corresponding author: **Rahul Mistry**
Gauhati Medical College, Bhangagarh, Gauhati

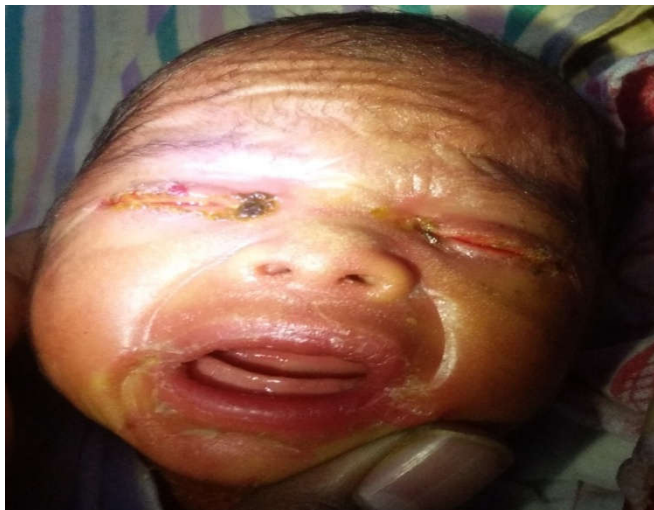


Fig Showing Picture of the Collodion Baby

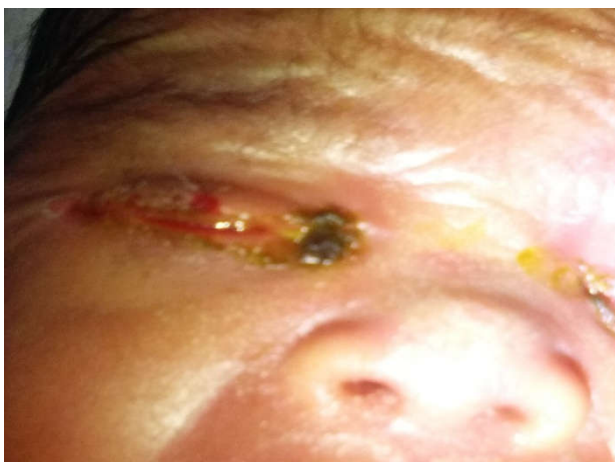

Fig Showing Ectropion of Right Eye Lid

DISCUSSION

Collodion baby is the name given to a baby who is born encased in a skin that resembles a yellow, tight and shiny film or dried collodion (sausage skin). These babies are often premature. The collodion membrane undergoes desquamation or peeling, and mostly develops into lamellar ichthyosis. Ichthyosis is a skin disorder characterized by excessive dryness of skin and increased formation of epidermal scales. The four main types of ichthyosis are ichthyosis vulgaris, sex linked recessive, lamellar ichthyosis and epidermolytic hyperkeratosis. Lamellar ichthyosis is the rarest form with an incidence of less than 1 in 3 lacs. It has autosomal recessive inheritance and there is a defect on chromosome 14q11 causing transglutaminase-1 (TG) defect. TG mutations might adversely affect the formation of cross links essential to formation of cornified cell envelopes and normal stratum corneum layer of the skin. Ocular manifestations of ichthyosis vary according to the type of ichthyosis. Scales on eyelashes and eyelids may be seen in all varieties. However, the tight collodion membrane covering the newborn and producing ectropion of lids is characteristically found in lamellar ichthyosis. Ocular manifestations include include bilateral ectropion of lower lids, chronic blepharitis and rarely cataract.

The membrane causes ectropion of all four lids, distortion of the pinna, effacement of the nose, and eversion of the lips. The child is often premature. Death may occur in as many as 25% from dehydration or hypothermia. These infants have marked temperature instability, defective barrier position, cutaneous infections, hypernatremic dehydration, and septicemia. Following desquamation, the skin occasionally appears normal, but usually there are fine, white, branny scales, and in later infancy or childhood, the patient develops lamellar ichthyosis. The ectropion that occurs at birth may lead to lagophthalmos because of cicatricial shortening of upper lid. Another concern is that the membrane acts like a thick film causing physical constraints of underlying tissues. This can create problems with:

- Suckling and nutrition
- Breathing
- Ectropion (lower eyelids turned outwards away from the eyeball)
- Constriction bands resulting in reduced blood supply and swelling of the limbs.

Management

The baby was admitted in neonatal intensive care unit (NICU). An incubator provides a humidified, neutral temperature environment. Other supportive treatments such as intravenous fluid and tube feeding are often necessary.

The aim is to keep the skin soft and attempt to reduce scaling. The collodion membrane should not be debrided (pulled off). Treatment may include:

- Regular emollients such as petrolatum to keep the skin moist.
- Pain relief such as paracetamol.
- Mild topical steroids to reduce secondary inflammation.
- Artificial tears if there is severe ectropion (outward turning eyelid).

Management requires the expertise of a dermatologist and the pediatric team. Other specialists that may need to be involved include ophthalmologist, geneticist and physiotherapist.

References

- A rare case of collodion baby with ophthalmic involvement
Bhardwaj U et al Collodion baby Nepal J Ophthalmol 2012; 4 (7):184-186
- Akiyama M (2006). Pathomechanisms of harlequin ichthyosis and ABCA transporters in human diseases. *Arch Dermatol;142:914-918*
- Arenas R (1996). Dermatología. Atlas, Diagnóstico y Tratamiento. México: *McGraw-Hill Interamericana*; p. 225-230.
- DiGiovanna JJ, Robinson-Boston L (2003). Ichthyosis: etiology, diagnosis and management. *AmJ Clin Dermatol; 4(2): 81-95.*
