



**Research Article**

**PREGNANCY AS A CAUSE OF PURE RED CELL APLASIA**

**Saumyaleen Roy and Anup Singh\***

Department of Medicine, IMS, BHU, Varanasi, U.P

**ARTICLE INFO**

**Article History:**

Received 12<sup>th</sup> January, 2018

Received in revised form 24<sup>th</sup>

February, 2018 Accepted 10<sup>th</sup> March, 2018

Published online 28<sup>th</sup> April, 2018

**ABSTRACT**

Pure red cell aplasia is a syndrome characterized by severe normocytic anemia, reticulocytopenia and absence of erythroblast from bone marrow aspiration study. Pregnancy associated PRCA is rare and gets corrected on its own. We present a case of a female with intrauterine death of foetus developing pure red cell aplasia on account of its rare presentation.

**Key words:**

Pure Red cell aplasia (PRCA), Pregnancy, Intrauterine death

*Copyright©2018 Saumyaleen Roy and Anup Singh. This is an open access article distributed under the Creative Commons Attribution License, which permits unrestricted use, distribution, and reproduction in any medium, provided the original work is properly cited.*

**INTRODUCTION**

Pure red cell aplasia (PRCA) is a haematological disorder where the precursor of red blood cells are arrested and number is scanty in bone marrow. It can be immunologically mediated, has association with pregnancy, viral infection, lymphoma, collagen vascular disease. Pregnancy associated PRCA gets corrected on its own and for others different immunosuppressants can be used like steroids, cyclosporine.[1,2]

In pregnancy it is a very rare cause of anemia. Our case is a primigravidae developing nonviable product of conception with pure red cell aplasia. It should be detected early in pregnancy for the survival of foetus. It should be distinguished from aplastic anemia as it does not require any therapy and gets corrected on its own.

**Case Report**

A 26 year old primigravidae at 5 months of gestation had complained of generalized weakness and easy fatigability along with bilateral pedal edema for 2 months. She complained of absent foetal movement for 1 day. She was admitted outside in a periphery hospital. On evaluation there was absent foetal cardiac activity in ultrasound. Immediately the product of conception was delivered but turned out to be Intrauterine death (IUD). She was transfused with 3 units of packed red blood cells (PRBC) and referred to our side for further evaluation of cause of anemia.

She had no history of any recent fever with sorethroat, dysphagia, any jaundice previously, weight loss, joint pain, photosensitive rash, oral ulceration, any history of similar admission in past for low hemoglobin. She takes mixed diet and drug history is nothing suggestive.

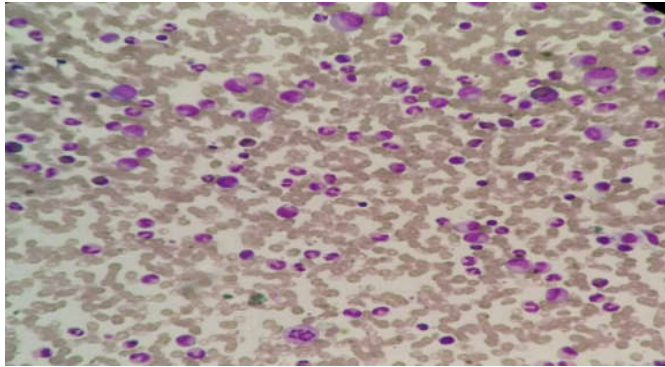
She had severe pallor with pedal edema. No lymphadenopathy or organomegaly detected. CNS and CVS, Chest examinations were within normal limits.

Her routine investigation showed hemoglobin (hb)-4.8g/dl, Total Red blood cells(TRBC)-1.6 million/microlitre, Total leucocyte count (TLC)-5370/mm<sup>3</sup>, Differential count-Neutrophil 48% Lymphocyte 42%, Platelet-adequate, Liver function test (LFT) and Renal function test (RFT) are within normal limits. General blood picture showed normocytes, along with microcytes, other cell lines intact, Corrected reticulocyte count (CRC) were 4%. In view of IUD her thyroid profile sent, TSH level was 2.4. Her Iron /Total iron binding capacity level 233/249. Vitamin B12 and Folic Acid stores were normal. Coombs test negative. Bone marrow aspiration cytology showed markedly depressed normoblastic erythroid series, with Myeloid: Erythroid ratio -40:1, other cell lines within normal limits. Bone marrow iron stores are increased. A picture of pure red cell aplasia was made from bone marrow aspiration cytology studies. Routine viral markers were negative. Anti nuclear antibody (ANA) was negative, test for Parvovirus PCR from blood was negative and so was viral titre for Cytomegalovirus and Ebstein bar virus. Ultrasound Abdomen and Chest radiograph normal. Computed tomography Chest showed no evidence of thymoma. Patient was transfused 3 units of PRBC and is then discharged with Hb-7g/dl, TLC-5600/mm<sup>3</sup> and Platelet- adequate. Patient was evaluated after 1 months when her Hb was 12 g/dl, TRBC 3.5

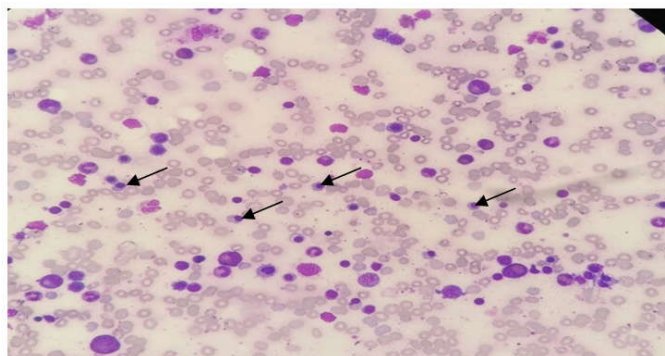
\*Corresponding author: **Anup Singh**

Department of Medicine, IMS, BHU, Varanasi, U.P

millions/microlitre, reticulocyte count 1.5%. Bone marrow aspiration cytology repeated after 3 months showed normoblastic erythropoiesis with erythrocytes in different stages of maturation.



Above fig showing bone marrow aspiration study showing absence of erythroid precursors



Above Fig Showing Bone Marrow Aspiration Study Showing Plenty of Erythroid Precursors(Arrow) After 3 Months

## DISCUSSION

Many disorders causes failure of erythropoiesis (3). It is a haematological disorder where the precursor of red blood cells are arrested at premature stage with nearly absent precursors in bone marrow of erythroid series with other cell lines intact. It is mainly idiopathic can be associated with drugs, viral infection (parvo, hepatitis a,b,cytomegalovirus, ebstein bar virus), collagen vascular disease, haematological malignancy, thymoma and with pregnancy.(4)

Pregnancy associated PRCA is very rare. It is said that igG immunoglobulin is formed against the blast forming unit (erythroid) during pregnancy with pure red cell aplasia (4). The characteristics of pregnancy induced PRCA are early anemia which gets corrected after delievery. Pregnancy associated pure red cell aplasia has got good prognostic factor with spontaneous recovery post delivery as described by Miyoshi *et al.*[5]

In another study by Muneeb *et al*, few of the cases were given a course of steroid for recovery. [6] There is high chances of recurrence of PRCA in next pregnancy as described by Majer RV *et.al.*[1] In this case a lady with 5 month of IUD presented to us with severe anemia, without any organomegaly or lymphadenopathy. Her general blood picture showed normocytes and microcytes, Corrected reticulated count.4% and BMA showed absent erythroid precursors.A diagnosis of pure red cell aplasia made on the ground of bone marrow aspiration study and pregnancy has been attributed to be the cause of PRCA as no other cause of PRCA detected and anemia got corrected spontaneously post delivery with normal erythroid precursors in bone marrow aspiration studies after 3 months.

## CONCLUSION

Pregnancy-induced PRCA is a rare cause of PRCA. It is usually self-limiting. However, subsequent pregnancies carries a high risk for relapse. Blood transfusion is sufficient to treat this self limiting syndrome.

## References

1. Majer RV, Green PJ. Recurrent reversible pure red cell aplasia in pregnancy. *Clin Lab Hematol.* 1988; 10:101-103.
2. Oie BK, Hertel J, Seip M, *et al.* Hydrops fetalis in three infants mother of a mother with acquired chronic pure red cell aplasia: transitory red cell aplasia in one of the infants. *Scand J Hematol.* 1984; 33:466-470.
3. Desypris EN. The biology of pure red cell aplasia. *Semin Haematol.* 1991;28:275-284
4. Baker RI, Manoharan A, De Luca E, *et al.* Pure red cell aplasia of pregnancy: a distinct clinical entity. *Br J Haematol.* 1983; 85(3):619-622.
5. Miyoshi I, Hikita T, Koi P, *et al.* Reversible pure red cell aplasia of pregnancy. *N Engl J Med.* 1978;299:777
6. Choudry, M.A., Moffett, B.K. & Laber, D.A. *Ann Hematol.* 2007; 86: 233.

### How to cite this article:

Saumyaleen Roy and Anup Singh (2018) 'Pregnancy As A Cause of Pure Red Cell Aplasia', *International Journal of Current Advanced Research*, 07(4), pp. 12133-12134. DOI: <http://dx.doi.org/10.24327/ijcar.2018.12134.2128>

\*\*\*\*\*