



Research Article

## ROLE OF DYNAMIC CONTRAST-ENHANCED PERFUSION MR IMAGING IN DIFFERENTIATION OF SUBTYPES OF RENAL CELL CARCINOMA- A PROSPECTIVE STUDY

Govindarajan Ramanujam\*, Leelakrishna.P and Thambidurai Govindan

Department of Urology, Kilpauk Medical College & Hospital, Chennai

### ARTICLE INFO

#### Article History:

Received 18<sup>th</sup> January, 2018

Received in revised form 13<sup>th</sup>

February, 2018 Accepted 15<sup>th</sup> March, 2018

Published online 28<sup>th</sup> April, 2018

#### Key words:

RCC – renal cell carcinoma, DCE MRI- dynamic contrast enhanced MRI, ER- enhancement ratio ,WR- washout ratio

### ABSTRACT

**Objective:** To evaluate the value of dynamic contrast enhanced MR imaging in prediction of preoperative histological subtypes of renal cell carcinoma.

**Methods:** Twenty patients with renal masses diagnosed on ultrasound or CT were included. All patients subjected to DCE MRI perfusion study after taking informed consent. Patient with low GFR and history of contrast allergy were excluded. The time signal intensity curve (TIC) of the lesion was created with calculation of enhancement ratio (ER), and washout ratio (WR).

**Results:** The subtypes of RCC were as follows: clear cell carcinomas (n=10), papillary carcinomas (n=6) and chromophobe carcinomas (n=4). The mean ER of clear cell, papillary and chromophobe RCC were 177±18.6, 44±5.05 and 119±7.14 respectively. The mean WR of clear cell, papillary and chromophobe RCCs were 30±3.4, 47±8.9 and 43±2.3, respectively. There was a significant difference in ER ( $P=0.001$ ) and WR ( $P=0.001$ ) between clear cell RCC and other subtypes of RCC.

**Conclusion:** Dynamic contrast enhancement MR Imaging analysis is feasible and can potentially be used to differentiate ccRCC from pRCC with high accuracy.

Copyright©2018 Govindarajan Ramanujam et al. This is an open access article distributed under the Creative Commons Attribution License, which permits unrestricted use, distribution, and reproduction in any medium, provided the original work is properly cited.

### INTRODUCTION

Magnetic resonance (MR) imaging is a useful tool for the characterization and presurgical staging of renal masses. Accurate characterization of renal masses is essential to ensure appropriate case management and to assist in staging and prognosis. Ultrasonography and computed tomography (CT) are commonly used for a variety of renal indications. MR imaging can be particularly helpful when renal lesions are detected but are not well characterized (1). A protocol for effective MR imaging of the kidney should maximize soft-tissue contrast, exploit the sensitivity of MR imaging to contrast material enhancement, and make full use of the multiplanar capability of this modality. The routine presurgical assessment of renal masses should include evaluation of the renal arterial supply and venous drainage. Correlating the anatomic findings and MR imaging signal intensity characteristics with the clinical features allows optimal diagnosis and staging. Renal cell carcinoma (RCC) accounts for 3% of all adult malignancies and is the most lethal urogenital tumor (2). Clear cell (frequency, 65%–70%), papillary (frequency, 10%–15%), and chromophobe (frequency, 6%–11%) RCCs are the most common RCC subtypes and differ in their histologic appearance and response to anticancer therapy (3).

Approximately 40% of patients with RCC eventually die from progression of this disease, making it the most lethal urologic malignancy. As already known, with the recent developments in immunohistochemistry, imaging-guided percutaneous biopsy became a minimally invasive method with relatively high accuracy (70-90%) in the preoperative histopathological characterization of renal tumors.

Determining subtypes of RCC has significant prognostic and therapeutic implications for patients who are poor surgical candidates, for patients who have a metastatic disease, for surgical planning in patients who are surgical candidates, and for immunotherapy and use of the tyrosine kinase inhibitors “sunitinib” and “sorafenib” for clear cell RCC and “temsirolimus” for papillary RCC (4,5)

Nephron-preserving surgical methods, cryoablation, radiofrequency ablation, targeted molecular therapy or follow-up, and MRI are believed to surpass other modalities both in the diagnosis of RCC and determination of its subtypes.

#### Aim and Objective

Purpose of this study is prospectively based on DCE MRI findings used for preoperatively determining the main histologic subtypes of RCC, including clear cell carcinoma, papillary, chromophobe.

### MATERIAL AND METHOD

Study period – jan2016 -jan2018

\*Corresponding author: Govindarajan Ramanujam  
Department of Urology, Kilpauk Medical College & Hospital, Chennai

Twenty patients with renal masses diagnosed on ultrasound or CT were included. All patients subjected to DCE MRI perfusion study (GE 1.5 TESLA) after taking informed consent. Patient with low GFR and history of contrast allergy were excluded. The time signal intensity curve (TIC) of the lesion was created with calculation of enhancement ratio (ER), and washout ratio (WR).

Indication for the MR-examination was characterization of the primary tumor, depiction of local infiltration and blood supply. All patients previously underwent routine CT examination of the thorax and the abdomen as primary staging modality.

**MRI Imaging Protocol**

In DCE pMRI, signal intensity on postcontrast MRI images is changed after the intravenous injection of gadolinium-based contrast agent (GBCA). Based on postprocessing models, the change in signal intensity can be used to measure perfusion parameters. Particularly for DCE pMRI, a T1-weighted gradient echo sequence is used after administration of GBCA contrast agent at a medium rate of 1–3 mL/s. When the tumor had a heterogeneous pattern, ROI was placed around the solid enhanced part of the tumor with avoidance of the cystic part. From ROI, the time-signal intensity curve (TIC) was automatically constructed.

The semiquantitative parameters derived from TICs were the enhancement ratio (ER) and washout ratio (WR). The enhancement ratio (ER) was defined as  $(SI_{max}-SI_{pre})/SI_{pre}$ , while the washout ratio (WR) was defined as  $[(SI_{max}-SI_{end})/(SI_{max}-SI_{pre})] \times 100$

$SI_{pre}$  was precontrast signal intensity

$SI_{max}$  was signal intensity at maximal contrast enhancement  
 $SI_{end}$  was SI at end of the study after 5 minutes of contrast material administration.

The statistical analysis of data was done by using Statistical Package for Social Science version (SPSS). First, the data were presented in the form of mean  $\pm$ SD. The second part was to test the statistically significant difference. One-way ANOVA test was used to compare more than 2 groups and Student’s t-test to compare between two groups. A *P* value was significant if  $<0.05$  at confidence interval of 95%. The receiver operating characteristic (ROC) curve was drawn to determine the cut-off value of perfusion parameters used for differentiating clear cell RCC from other subtypes with calculation of sensitivity, specificity, accuracy and area under the curve (AUC).

Histopathological diagnosis was obtained from radical nephrectomy ( $n=16$ ), partial nephrectomy ( $n=4$ ).

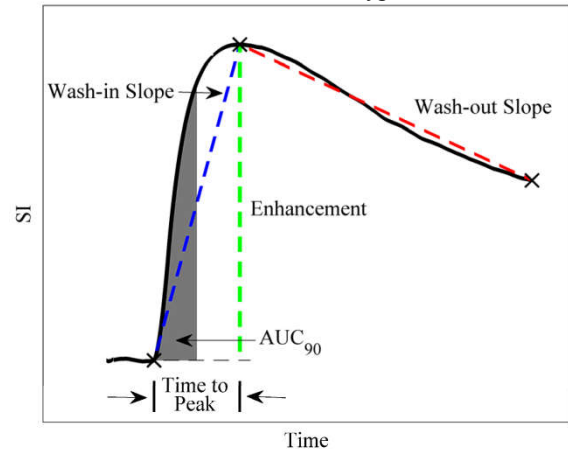
**RESULTS**

There were 20 renal masses, average size of tumor ranging from 2 to 7cm. Average age of patient 54,12 were men 8 women. Histopathologic analysis was obtained from radical nephrectomy ( $n = 16$ ), partial nephrectomy ( $n = 4$ ) specimens. Tumor involved in right kidney about 12cases and left kidney 8cases.

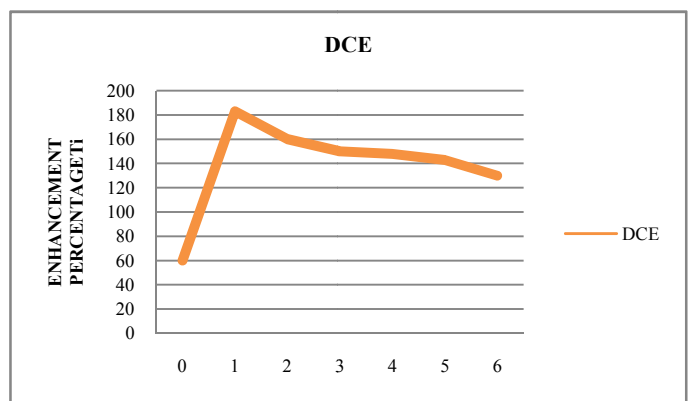
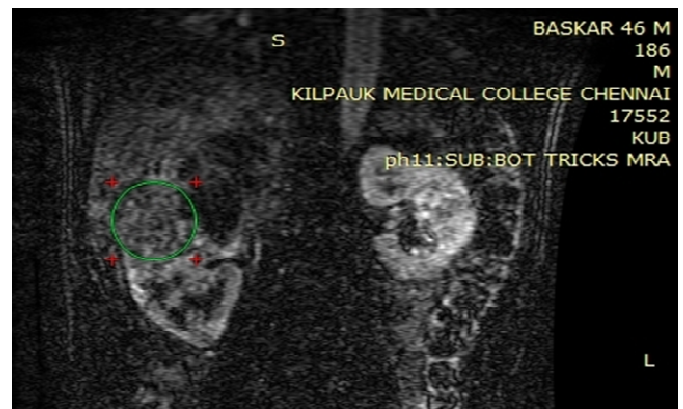
The final pathological subtypes of RCC were clear cell carcinomas ( $n=10$ ), papillary carcinomas ( $n=6$ ), and chromophobe carcinomas ( $n=4$ ). The mean and standard deviation of ER and WR for subtypes of RCC are illustrated in Table 1. The cut-off of ER and WR used to differentiate clear cell RCC from other subtypes with calculation of sensitivity,

specificity, accuracy and AUC. The mean ER of clear cell, papillary and chromophobe RCC were  $177 \pm 18.4$ ,  $44 \pm 5.05$  and  $119 \pm 7.14$ , respectively. There was significant difference in ER between clear cell RCC and other subtypes (papillary and chromophobe RCC) ( $P=0.001$ ) and a significant difference in ER between papillary and chromophobe RCC ( $P=0.001$ ).

The mean WR of clear cell RCC was  $30 \pm 3.4$ , and of papillary and chromophobe subtypes of RCC  $47 \pm 8.9$  and  $43 \pm 9.9$ , respectively. There was a significant difference in WR between clear cell RCC and other subtypes of RCC

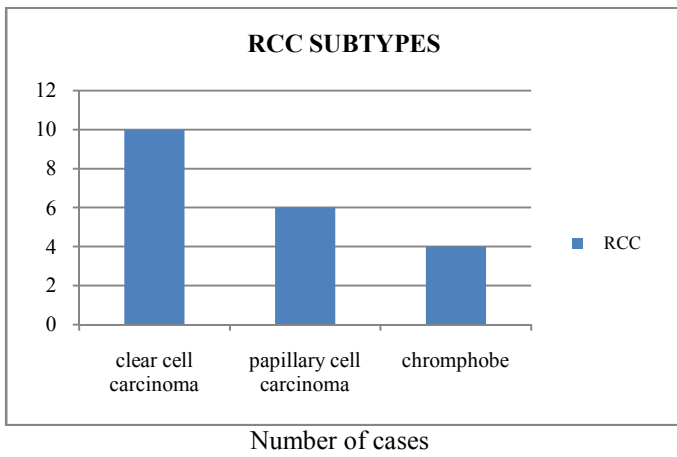


**Figure 1** Time intensity curve (TIC)



**Figure 1** A DCE MRI Right Upper Pole mass

Time intensity curve shows Enhancement ratio – 183 and Wash out ratio -33 Post operative histopathology shows – clear cell carcinoma



**Table No 1** RCC subtypes Enhancement and washout ratio

Tumors	ER	WR
Clear cell carcinoma	177±18.6	30±3.4
Papillary carcinoma	44±5.05	47±8.9
Chromophobe carcinoma	119±7.14	43±2.3

**DISCUSSION**

Pretreatment determination of subtypes of RCC is particularly important for patients who are either poor surgical candidates or who have a metastatic disease, although knowledge of the tumor subtype may also be helpful for surgical planning in patients who are surgical candidates. Clear cell RCC, which accounts for about 65–70% of all RCCs, has generally worse outcomes than other RCC types in part because of its high metastatic potential [6,7,8]. Dynamic contrast-enhanced (DCE) computed tomography (CT) provides a useful method of differentiating clear cell RCC from non-clear-cell RCC since studies have shown that non-clear-cell RCC is a less vascularized lesion than clear cell RCC(9,10).Recent improvements in MR imaging techniques allow for a new paradigm in oncologic imaging by shifting from a pure morphologic evaluation of tumors(ie, measurements of tumor size and extent) toward an assessment of the physiologic characteristic of tumors, including evaluation of tumor perfusion, oxygenation, and diffusion characteristics. There are three different types of perfusion MRI (pMRI) techniques: dynamic contrast-enhanced (DCE), dynamic susceptibility contrast (DSC), and arterial spin labeling (ASL)(11).

In DCE and DSC pMRI, signal intensity on postcontrast MRI images is changed after the intravenous injection of gadolinium-based contrast agent (GBCA). Based on postprocessing models, the change in signal intensity can be used to measure perfusion parameters (12,13).

Rotem *et al* ASL MR imaging enables distinction among different histopathologic diagnoses in renal masses on the basis of their perfusion level. Oncocytomas demonstrate higher perfusion levels than RCCs, and papillary RCCs exhibit lower perfusion levels than other RCC subtypes (14).

In this study, the clear cell RCC showed the highest ER (177%) followed by chromophobe RCC which showed a moderate ER (119%) while papillary RCCs demonstrated the lowest ER (44%).

Sun MR *et al* reported mean percentage signal intensity change of clear cell, papillary, and chromophobe RCCs of

205.6%, 32.1%, and 109.9%, respectively (clear cell versus papillary RCCs,  $P=0.0001$ ; papillary versus chromophobe RCCs,  $P=0.02$ ; clear cell versus chromophobe RCCs,  $P=0.01$ ) [15].

Ahmed Abdel Khalek *et al* the clear cell RCC showed the highest ER (188%) followed by chromophobe RCC which showed a moderate ER (120%) while papillary RCCs demonstrated the lowest ER (35%)(6).

Ankur Goyal *et al* ADC values provide a non-invasive means to predict the nuclear grade and histological subtype of RCC. Cellularity and morphology are other tumor attributes contributing to the variation in ADC values of RCCs (16). Limitations of this study 1.small study group, larger number of patients required for better outcome.2. In this study semiquantitative parameters applied for prediction of histological RCC subtypes, studies with multiparametric imaging and quantitative analysis using pharmacokinetic models to produce physiological quantitative perfusion parameters such as blood flow, blood volume and endothelial permeability coefficient and histogram analysis of whole lesion enhancement are recommended

**CONCLUSIONS**

Dynamic contrast enhancement histogram analysis feasible and can potentially be used to differentiate ccRCC from pRCC with high accuracy. DCE MRI combined with diffusion weighted image improve accuracy in histology subtypes of RCC. Preoperative determination of histology subtypes of RCC more useful for patients planned for targeted therapy to downstage inoperable tumor and RCC metastasis.

**References**

1. MR Imaging of Renal Masses: Correlation with Findings at Surgery and Pathologic Analysis Ivan Pedrosa, MD, *et al RadioGraphics* 2008; 28:985–1003
2. Reuter VE. The pathology of renal epithelial neoplasms. *Semin Oncol* 2006; 33(5):534-543.
3. Cheville JC, Lohse CM, Zincke H, Weaver AL, Blute ML. Comparisons of outcome and prognostic features among histologic subtypes of renal cell carcinoma. *Am J Surg Pathol* 2003; 27(5):612-624.
4. Smith AD, Shah SN, Rini BI, Lieber ML, Remer EM. Morphology, Attenuation, Size, and Structure (MASS) criteria: assessing response and predicting clinical outcome in metastatic renal cell carcinoma on antiangiogenic targeted therapy. *AJR Am J Roentgenol.* 2010; 194(6):1470-8.
5. Escudier B, Eisen T, Stadler WM, *et al.* Sorafenib in advanced clear-cell renal-cell carcinoma. *N Engl J Med* 2007; 356(2):125-134.
6. Ahmed Abdel Khalek Abdel Razek, *et al* Assessment of Semiquantitative Parameters of Dynamic Contrast-Enhanced Perfusion MR Imaging in Differentiation of Subtypes of Renal Cell Carcinoma *Pol J Radiol*, 2016; 81: 90-94
7. Compérat E, Camparo P: Histological classification of malignant renal tumours at a time of major diagnostic and therapeutic changes. *Diagn Interv Imaging*, 2012; 93: 221-31
8. Prasad S, Humphrey P, Catena J *et al*: Common and uncommon histologic subtypes of renal cell carcinoma:

- Imaging spectrum with pathologic correlation. *Radiographics* 2006; 26: 1795-810
9. Young JR, Margolis D, Sauk S *et al*: Clear cell renal cell carcinoma: discrimination from other renal cell carcinoma subtypes and oncocytoma at multiphasic multidetector CT. *Radiology*, 2013; 267: 444-53
  10. Shebel H, Elsayes K, Sheir K *et al*: Quantitative enhancement washout analysis of solid cortical renal masses using multidetector computed tomography. *J Comput Assist Tomogr*, 2011; 35: 337-42
  11. Zokalj I, Marotti M, Kolarić B: Pretreatment differentiation of renal cell carcinoma subtypes by CT: The influence of different tumor enhancement measurement approaches. *Int Urol Nephrol*, 2014; 46: 1089-100
  12. Oliva M, Glickman J, Zou K *et al*: Renal cell carcinoma: T1 and T2 Signal Intensity Characteristics of Papillary And Clear Cell Types Correlated With Pathology. *Am J Roentgenol*, 2009; 192: 1524-30.
  13. YanWu, Young Suk Kwon, Mina Labib *et.al* Magnetic Resonance Imaging as a Biomarker for Renal Cell Carcinoma Hindawi Publishing Corporation Disease Markers Volume 2015, Article ID 648495.
  14. Rotem S. Lanzman, MD Phil M. Robson, PhD Maryellen R. Sun, MD *et.al* Arterial Spin-labeling MR Imaging of Renal Masses: Correlation with Histopathologic Findings Volume 265: Number 3-December 2012 radiology.rsna.org
  15. Sun MR, Ngo L, Genega EM *et al*: Renal cell carcinoma: Dynamic contrast-enhanced MR imaging for differentiation of tumor subtypes-correlation with pathologic findings. *Radiology*, 2009; 250: 793-802.
  16. Ankur Goyal1, Raju Sharma1, Ashu S Bhalla *et .al* Diffusion-weighted MRI in renal cell carcinoma: A surrogate marker for predicting nuclear grade and histological subtype. *Acta Radiologica* 2012; 53: 349-358.

**How to cite this article:**

Govindarajan Ramanujam *et al* (2018) 'Role of Dynamic Contrast-Enhanced Perfusion Mr Imaging In Differentiation of Subtypes of Renal Cell Carcinoma- A Prospective Study', *International Journal of Current Advanced Research*, 07(4), pp. 11673-11676. DOI: <http://dx.doi.org/10.24327/ijcar.2018.11676.2027>

\*\*\*\*\*