

SUBCUTANEOUS ZYGOMYCOSIS MASQUERADING AS A SOFT TISSUE SARCOMA – A CASE REPORT

Prashant Mule¹, Rohini Kelkar², Sanjay Biswas³ and Vivek Bhat⁴

^{1,2,3}Department of Microbiology, Tata Memorial Hospital, Mumbai, India- 400 012

⁴Department of Microbiology, Advanced Center for treatment, Research and Education in Cancer, New Mumbai, India-410 210

ARTICLE INFO

Article History:

Received 11th January, 2018

Received in revised form 24th

February, 2018 Accepted 9th March, 2018

Published online 28th April, 2018

Key words:

Basidiobolus, Zygomycosis, soft tissue sarcoma, potassium iodide.

ABSTRACT

Basidiobolus ranarum is a known cause of subcutaneous zygomycosis. The clinical presentation of the subcutaneous disease is quite characteristic. We present the case of painless subcutaneous Zygomycosis involving the right upper arm mimicking soft tissue sarcoma. The fluorescent microscopy with calcofluor white stain showed broad, ribbon-like, relatively aseptate hyphae suggestive of Zygomycetes species. A Lacto Phenol Cotton Blue mount from the culture showed broad hyphae and many asexual spores some of them showing hyphal forms with globose to pyriform shaped conidia of sizes varying from 30-50 µm in diameter. The morphology was characteristic of *Basidiobolus ranarum*. Patients with Basidiobolomycosis responds well to oral potassium iodide therapy as well to azoles, particularly itraconazole and posaconazole. Patient was treated with oral potassium iodide 40 mg/kg per day for a week with addition of oral itraconazole 100 mg/day and the treatment continued for six months.

Copyright©2018 Prashant Mule et al. This is an open access article distributed under the Creative Commons Attribution License, which permits unrestricted use, distribution, and reproduction in any medium, provided the original work is properly cited.

INTRODUCTION

Entomophthoromycosis (subcutaneous zygomycosis) is an infection caused by several fungi belonging to the phylum Zygomycota. These are saprophytic fungi found in the soil, decaying fruit and vegetable matter and are found ubiquitously in the environment. *Basidiobolus ranarum* (*B. haptosporus*, *B. meristoporus*) is a fungus belonging to the order Entomophthorales under the family Zygomycota. Basidiobolomycosis is a predominantly subcutaneous infection involving the trunk and limbs in immunocompetent hosts. It can cause a variety of clinical manifestations including subcutaneous zygomycosis, gastrointestinal zygomycosis and occasionally an acute systemic illness similar to that caused by the Mucorales¹. Subcutaneous zygomycosis is the commonest presentation with cases reported from many tropical countries including India²⁻⁴. The mode of infection is likely to be local inoculation following traumatic injuries and insect bites. Children and young adults are commonly affected. Males are more often affected compared to females. Clinically these infections present as subcutaneous nodules affecting the gluteal and thigh region although there are case reports affecting the head and neck region as well. Here we report an unusual case of subcutaneous zygomycosis caused by *Basidiobolus* with an unusual mass arising from the upper

extremity which mimicked a soft tissue malignancy. The biopsy revealed this to be subcutaneous Zygomycosis caused by *Basidiobolus*.

CASE REPORT

A two years old male child was brought to the outpatient department with a swelling in the right forearm for the 5 months. There was a slow, gradual increase in size of the swelling. It was firm and nodular in consistency, around 10 cm in length, spanning 6 cm, occupying almost whole circumference of the right forearm, sparing the lateral side. The swelling was lobulated at multiple sites with slight reddening around these nodules [Fig. 1].

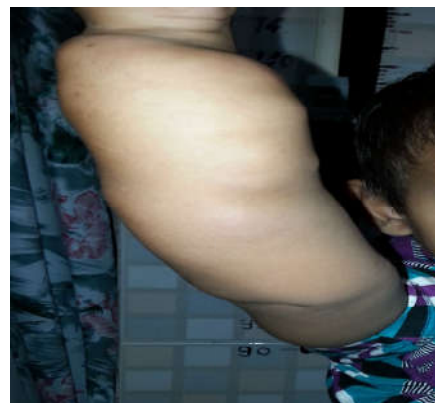

Fig 1 Nodules over the swelling Swelling extending from the wrist joint to the proximal forearm without joint involvement

*Corresponding author: Prashant Mule

Department of Microbiology, Tata Memorial Hospital, Mumbai, India- 400 012

He had no neurological deficit clinically and pulses were not palpable. The patient has no history of trauma, thorn prick, fever or any other major illness in the recent past. The rest of the general and systemic examination was normal. Routine laboratory investigations were normal and his HIV status was negative. Due to size and location of the lesion, the differential diagnosis of a Soft tissue Sarcoma was considered. Ultrasound was done to rule out any vascular malformations [Fig. 2].

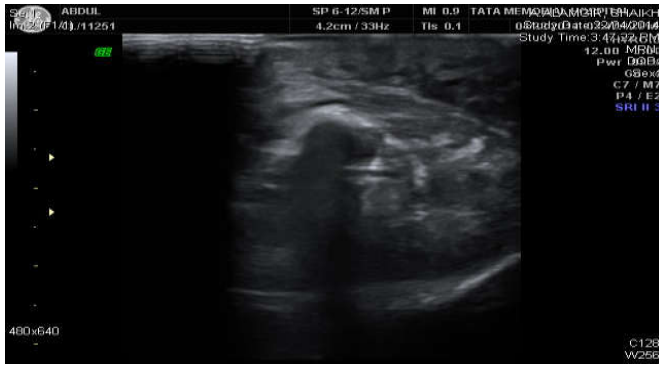

Fig 2 Solid looking lesion without any vascular malformations.

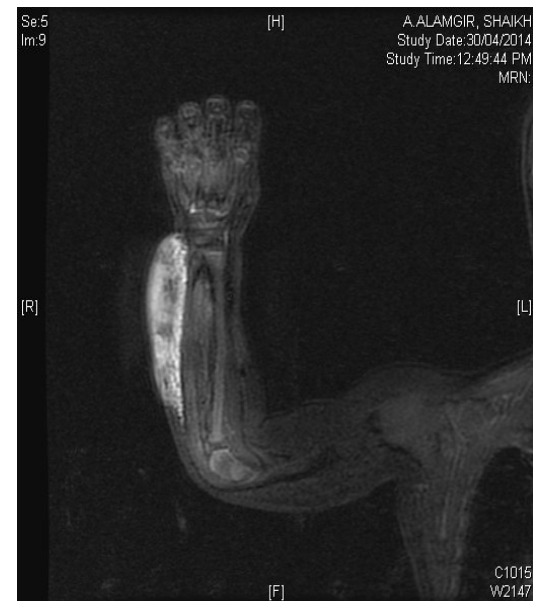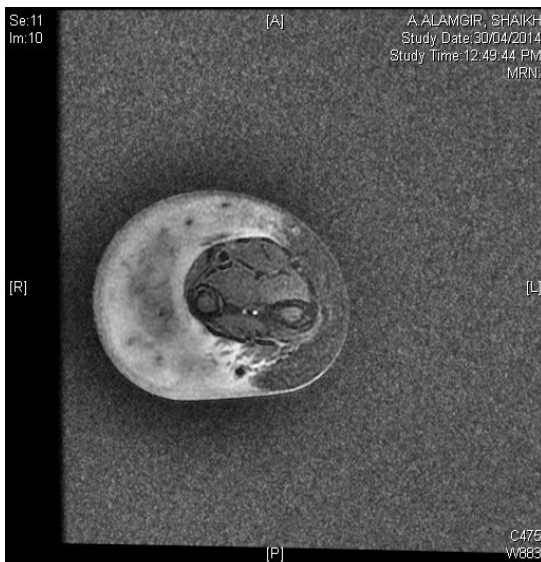


Fig 3 The composite MRI image of the medial aspect of lower 2/3rd of the right forearm.

After USG ruled out vascular abnormality, the MRI indicated an uncertain benign etiology [Fig 3]. The lesion in the MRI was compartmentalized without invasion or infiltration into surrounding structures and well maintained fat planes. Fig. 3 The composite MRI image reveals a large lesion involving the medial aspect of lower 2/3rd of the right forearm. The mass lies in the subcutaneous plane. It shows multiple central hypointense areas with surrounding oedema. It measures 7.7 cms in craniocaudal extent and encases the underlying structures over 180° without disrupting the fascial plane. It shows heterogeneous enhancement on post contrast scans. Few vessels are seen within the mass with maintained flow voids. No evidence of extension is seen in the muscular compartment. The neurovascular bundle appear intact. The wrist joint and elbow joints are uninvolved. This circumferential growth without invasion of fascial planes is unlike any common tumor in children and a possibility of non cancer etiology like subcutaneous granuloma annulare was considered. With no definitive diagnosis, an incisional biopsy was performed. The biopsy tissue included the overlying skin and underlying soft tissue, right up to the bone. The histopathological examination revealed necrotizing granulomatous inflammation involving deep dermis and the subcutaneous tissue. Broad fungal hyphae were seen in the center of the granulomas [Highlighted by GMS and PAS stains], also called as the ‘Splendore-Hoepli phenomenon’ [Fig. 4 & 5].

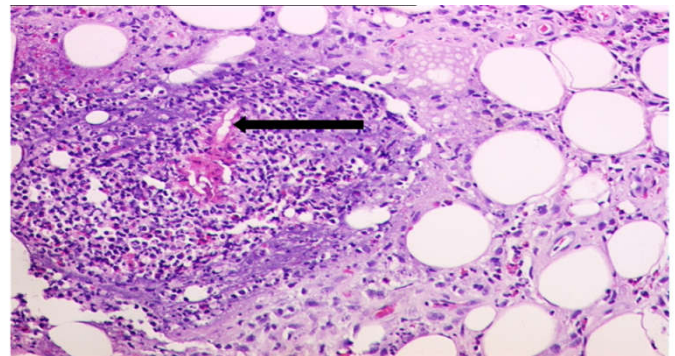


Fig 4 Fungal hyphae seen as negative shadow (shown by arrow) within neutrophilic abscess of the soft tissue. (H & E stain, magnification x 100).

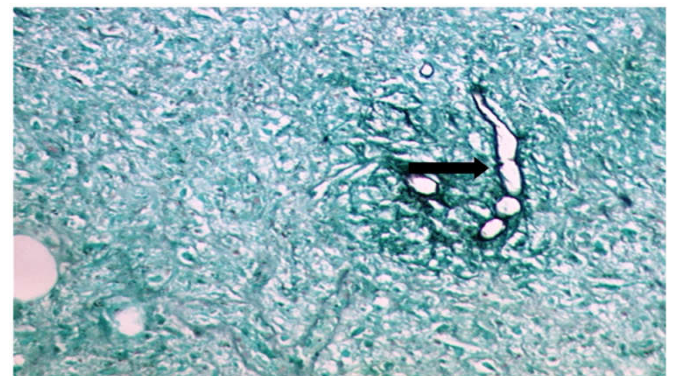


Fig 5 Grocott's Gomori methenamine silver [GMS] stain demonstrating the fungal hyphae (arrow, magnification x400).

There was no evidence of neoplasia. A part of the specimen was sent for microbiological analysis. The fluorescent microscopic examination with Calcofluor White stain showed broad, ribbon-like, relatively aseptate hyphae suggestive of Zygomycetes species (Fig. 6). The specimen was processed on Sabouraud's Dextrose Agar, Cornmeal Agar and Potato Dextrose Agar.

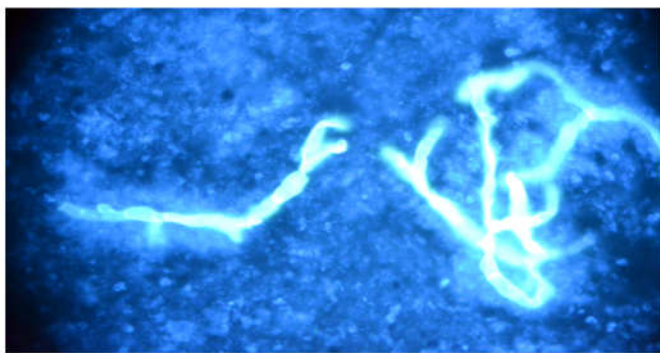


Fig 6 Calcofluor White stain showing relatively broad aseptate hyphae suggestive of Zygomycetes species.



Fig 7a Growth of the fungus on BHI with blood agar at 30°C (obverse) showing colony morphology that is radially folded.



Fig.7b Growth of the fungus on SDA at 30°C (reverse)

Growth was rapid (3-4 days) on Sabouraud's Dextrose Agar at 30 °C (Fig. 7a and 7b). The growth was flat, dry, yellowish brown in color. Over the time, the growth became radially folded. A Lacto Phenol Cotton Blue mount from the culture showed broad hyphae and many asexual spores some of them showing hyphal forms. The mount showed globose to pyriform shaped conidia of sizes varying from 30-50 µm in diameter. The conidia were smooth-walled and had granules inside them.

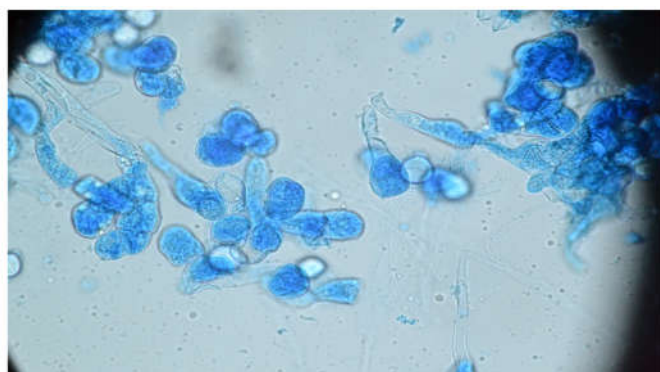


Fig 8 Lacto Phenol Cotton Blue showing conidia and broad aseptate hyphae

The morphology was characteristic of *Basidiobolus ranarum* (Fig. 8). In the past, clinical isolates of *Basidiobolus* were classified as *B. ranarum*, *B. meristosporus* and *B. haptosporus*. But recent taxonomic studies based on antigenic analysis, isoenzyme banding and restriction enzyme analysis of rDNA indicate that all human pathogens belong to *B. ranarum*⁵. Few characteristic features that aided in the microbiologic diagnosis are forcible ejection of sporangioles. This causes production of many satellite colonies (Fig. 9). The sporangioles that are ejected can form a mirror image of the growth.

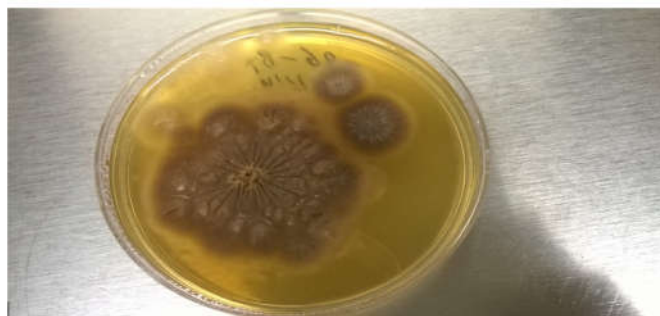

Fig 9 Forcible ejection of sporangioles with production of satellite colonies

DISCUSSION

Zygomycosis of the upper extremity is a rare clinical entity and is seen in patients who are immunocompromised, patients with trauma or injury to the forearm, patients with burn injuries or patients on chemotherapy. Infections in immunocompetent is rare. The fungi in the Class Zygomycetes are divided into two Orders namely Mucorales and Entomophthorales. Mucorales affect only the immunocompromised patient causing mortality in excess of 60% in those affected. The fungi in Entomophthorales are mainly arthropod parasites. The name of the order is derived from the Greek word 'Entomon' meaning insect. The literal meaning of Entomophthora is insect destroyer. These fungi are pathogenic to insects and are found in soil, decaying vegetation and gastrointestinal tracts of amphibians like toads, frogs and small reptiles⁶. Entomophthorales, which include *Basidiobolus* and *Conidiobolus* genera, affect the immune competent individual, causing principally chronic infection of the subcutaneous tissue⁷. Basidiobolomycosis is a rare disease caused by the fungus *Basidiobolus ranarum*, an environmental saprophyte, found worldwide⁸. Usually basidiobolomycosis is a subcutaneous infection that is transmitted through traumatic inoculation⁸. *B. ranarum* was described from animal and environmental sources as early as 1886. The first human case was reported in 1956 in a patient from Indonesia. Although, the organism is found world-wide, there are estimated to have been only a few 100 cases of infection. *Basidiobolus* infections have historically been limited to tropical and subtropical areas, occurring as a chronic subcutaneous mycosis of the trunk and extremities in immunocompetent hosts, primarily children and young adults⁶. *B. ranarum* spends part of its life cycle in the intestine of the agamid lizard and is liberated as spores and mycelia in the lizard excrement. The spores germinate, and the organism grows saprophytically on lizard droppings, from which it may be picked up by individuals with traumatic lesions. Basidiobolomycosis occurs predominantly in healthy individuals. *B. ranarum* typically causes a chronic infection of the peripheral or subcutaneous tissue, usually on the arms, trunk, and buttocks. The most common presentation for basidiobolomycosis is on the thighs and buttocks in a "bathing

suit" distribution⁶. The infection is characterized by a hardened nodule, which expands and spreads locally. Although, the nodules will eventually ulcerate the overlying skin, dissemination usually does not occur. The nodular lesions contain inflammatory cellular material with many eosinophils, accounting for the associated erythema and warmth of the skin. The infection is slowly progressive without treatment but may heal spontaneously. *B. ranarum* has been reported to cause gastrointestinal infections, lymph node and muscle involvement apart from chronic granulomatous subcutaneous infection. *Basidiobolus* is relatively thermotolerant and is capable of growing, at 37°C, similar to the pathogenic Mucorales. It is hypothesized that thermotolerance is an important virulence factor for these organisms, allowing them to establish infections *in vivo* with those possessing growth capabilities above 37°C having the advantage of survival in the febrile patient.

Basidiobolomycosis may resemble other infections, especially, other tropical infections, which present with subcutaneous lesions. *Basidiobolus* infection may resemble other fungal infections (Pythiosis and Sporotrichosis), parasitic infections (filarial elephantiasis and Onchocerciasis), bacterial infections (Mycobacterium tuberculosis and Mycobacterium ulcerans), and other diseases, including Burkitt's lymphoma. While the direct examination may suggest the provisional diagnosis, culture remains the "gold standard" for diagnosis.

Biopsy of subcutaneous tissue demonstrates broad, thin-walled hyphae together with acute and/or chronic inflammatory cell infiltrates. The mycelium of *Basidiobolus* is more septate than the hyphae of other zygomycetes. Hyphae are easily visualized with H and E stain. Histologically, basidiobolomycosis is associated with eosinophilic infiltration which was also the case in our patient. This has been postulated to be due to a mixture of Th1 (granuloma) and Th2 type of immune response. This causes the release of cytokines like IL-4 and IL-10 which in turn are helpful in recruiting eosinophils at the affected site⁹. The other histological features are presence of broad thin walled infrequently septate hyphal fragments enveloped by eosinophilic "Splendore-Hoeppli" material¹⁰. The organism does not typically invade the blood vessel and tissue; necrosis and tissue infarction are therefore not present. Most patients with entomophthoromycosis respond very well to oral potassium iodide therapy as well to azoles, particularly itraconazole and posaconazole. After complete excision the patient was treated with oral potassium iodide 40 mg/kg per day. After one week of treatment with potassium iodide, oral itraconazole was added in a dose of 100mg/day and the entire treatment continued for six months. To summarize Subcutaneous zygomycosis presents as a painless subcutaneous swelling usually in young age. It is usually seen in the natives of Asia, Africa, and South America. Demonstration of the aseptate fungal hyphae on histopathology and confirmation by culture clinches the diagnosis. Most patients with entomophthoromycosis respond very well to oral potassium iodide therapy as well to azoles, particularly itraconazole. Treatment with potassium iodide and azoles is the gold standard. Our experience with this case highlights the importance of awareness and early recognition of this condition to prevent disfigurement produced by advanced disease, misdiagnosis, and unnecessary surgical intervention.

Acknowledgements

We are thankful to the Department of Microbiology and Department of Paediatric solid tumors.

Conflict of Interest

Author declares no conflicts of interest

Funding

Not applicable

Ethical Approval

Not applicable

Consent

Written guardian consent has been taken

Guarantor

First (corresponding) and Second author

References

1. Zavasky DM, Samowitz W, Loztus T, Segal H, Carroll K. Gastrointestinal zygomycotic infection caused by *Basidiobolus ranarum* - case report and review. *Clinical Infectious Disease* 1999; 28:1244-1248.
2. Koshi G, Kurien T, Sudarsanan D, Selvapandian AJ, Mannmen KE. Subcutaneous phycomycosis caused by *Basidiobolus* - a report of 3 cases *Sabouraudia* 1972;10(3):237-243.
3. Dasgupta LR, Agarwal SC, Varma RA, Bedi BM, Chatterjee H. Subcutaneous phycomycosis from Pondicherry, South India. *Sabouraudia* 1976;14(2):123-127.
4. Sood S, Sethi S, Banerjee U. Entomophthoromycosis due to *Basidiobolus haptosporus*. First case from a surgical wound. *Mycoses* 1997;40(9-10):345-346.
5. Sujatha S, Sheeladevi C, Khyriem AB, Parija SC. Subcutaneous Zygomycosis caused By *Basidiobolusranarum* - a case report. *Indian J Med Microbiol.* 2003 Jul-Sep;21(3):205-6.
6. Chander J. Zygomycosis. Textbook of Medical Mycology. 3rded. New Delhi. Mehta Publisher 2011. p. (361-86)
7. Prabhu RM, Patel R. Mucormycosis and entomophthoromycosis: A review of the clinical manifestations, diagnosis and treatment. *ClinMicrobiol Infect.* 2004;10:31-47
8. *Sugar AM: Agents of mucormycosis and related species.* In Mandell, Douglas and Bennetts's principles and practice of infectious diseases. 6th edition. Edited by Mandell GL, Bennett JE, Dolin R. Philadelphia, USA: Elsevier; 2005:2973-84.
9. S.Rane, A.Jayaraman, S.Puranik, S.Deshmukh, and V.Bapat, "Entomophthoromycosis-Report of four cases," *Indian Journal of Dermatology, Venereology and Leprology*, vol. 68, no. 5, pp. 296-297, 2002.
10. F. W. Chandler and J. C. Watts, "Fungal Diseases," in Anderson's Pathology, I. Damjanov and J. Linder, Eds., Mosby, St. Louis, Mo, USA, 10th edition, 1996.
