



Research Article

A STUDY OF COSMETIC EVALUATION OF VARIOUS METHODS OF SCAR CORRECTION

Om Prakash Gupta^{1*}, Shainda Laeeq², Saurabh Srivastava³ and Shalini Gupta⁴

¹Department of Surgery, Prasad Institute of Medical Sciences, Lucknow, India

^{2,3,4}Department of Oral Pathology & Microbiology, King George's Medical University, Lucknow, India

ARTICLE INFO

Article History:

Received 20th November, 2017

Received in revised form 27th

December, 2017

Accepted 14th January, 2018

Published online 28th February, 2018

Key words:

Scars, Keloids, Aesthetic, Dermatologists, Techniques.

ABSTRACT

An individual's facial appearance is one of his most obvious characteristics of his personality and facial disfigurement is judged to be among the least desirable 'handicaps'. physical attractiveness has a statistically significant effect on self-esteem and other measures of psychic well-being. Scars are psychologically distressing for the patients and have an impact on the quality of life and self esteem of the patients. Scar revision is an aesthetic skill which is mastered by plastic surgeons and encroached now by dermatologists. Scars on the face are aesthetically unacceptable and various techniques have been improvised for making a scar aesthetically acceptable.

Copyright©2018 Om Prakash Gupta et al. This is an open access article distributed under the Creative Commons Attribution License, which permits unrestricted use, distribution, and reproduction in any medium, provided the original work is properly cited.

INTRODUCTION

Facial attractiveness is recognized as being important in various situations as diverse as education, relationship, marriage and employment. An individual's facial appearance is one of his most obvious characteristics of his personality and facial disfigurement is judged to be among the least desirable 'handicaps'. Body Image is a basic component of self-concept and our feeling of personal identity. A normal face plays a very important role in the development of social and mental well being in this highly competitive society that places considerable emphasis on youth and beauty.

Studies have shown that physical attractiveness has a statistically significant effect on self-esteem and other measures of psychic well-being. The physically attractive enter life with a halo effect and receive preferential treatment over their unattractive counterparts from cradle to adult life viz. by the nurses in nurseries (Corter *et al.*, 1980), the parents (Boukydis, 1981), the playmate (Dion, 1973), the teachers (Adams *et al.* 19), the opposite sex (Kallick, 1978) and the employer (Cash *et al.* 1977). However, it is not meant to imply that physically attractive are better people than the unattractive but that they are offered far greater opportunities for success and happiness.

Scars are formed after surgical procedures and different types of trauma, especially burn injuries. Some scars heal quickly, while others develop into hypertrophic scars or keloids. These problematic scars often need to be treated for months or even

years. While there have been new innovations in scar treatment in recent years, effective treatment options are lacking. There is no scientific evidence of the efficacy of the most common scar treatment and prevention methods. Even the smallest surgical operation leaves a scar. Some scars heal well, leading to an unnoticeable fine line, whereas others are prone to develop scar hypertrophy or, in the worst case, transform into keloids. Wounds closed with excess tension are known to produce more scar tissue (Ogawa *et al.* 2011). In some cases, tension-free closure cannot be achieved, with skin cancer surgery as an example. Scars produced by trauma, especially burn injuries, are more prone to hypertrophy (English and Shenfelt 1999). This poses a difficult problem for the rehabilitation of burn victims (Serghiou *et al.* 2009). Hypertrophic scars (HSC) and keloids are often associated with symptoms such as pain and itching (Wolfram *et al.* 2009). They can create significant functional problems, such as restricted movement, especially when located near joints (Ladak and Tredget 2009). Untreated HSCs develop contractures that can be debilitating, a fact unfortunately often seen in developing countries (Prasanna *et al.* 2004). Scars have a significant impact on patients' psychological welfare (Truong *et al.* 2005). Besides the somatic problems, HSCs affect especially the acceptability to one's self and others as well as social functioning and emotional well-being (Brown *et al.* 2008a).

The ongoing studies concerning scars have focused on producing treatments to reduce or even prevent scar formation (Oocleston *et al.* 2008). Based on the scarfree foetal wound healing, the newest innovation, transforming growth-factor (TGF) B3, has shown potential in reducing scar formation (Ferguson *et al.* 2009).

*Corresponding author: **Om Prakash Gupta**

Department of Surgery, Prasad Institute of Medical Sciences, Lucknow, India

Skin graft donor site wounds pose a problem especially in burn victims. Research aims at finding an optimal donor site treatment that would alleviate pain and reduce scar formation. The skin graft donor site is a wound of standard depth and offers a unique possibility to study dermal wound healing and skin scarring in vivo.

There are several ways to treat and prevent scar hypertrophy, but none have been shown to be effective alone (Mustoe *et al.* 2002). Instead, scars are treated with a combination of methods, including pressure garment therapy, silicone gel sheeting, cortisone injections and physiotherapy (Ogawa, Karagoz *et al.* 2009). The cost of these treatments is considerable (Aarabi *et al.* 2007). Still, there is no evidence of the effect of the most widely used treatments – silicone gel sheeting has been used for over 20 years but has not been proved to affect the outcome of HSCs (O'Brien and Pandit 2006). Pressure garments are thought to relieve scar hypertrophy or at least alleviate the symptoms. However, recent studies, especially a meta-analysis by Anzarut *et al.*, have questioned the need for pressure garment therapy, which yields considerable costs especially in burn centres (Anzarut *et al.* 2009, Harte *et al.* 2009). One obvious reason for the poor quality of scar studies is the lack of objective, reliable methods for scar assessment.

Scarring comprises various processes involving many factors, and scars have distinctive differences from normal tissues in terms of appearance and pathology. Scars have been classified on the basis of differences from normal tissues. However, currently, there is no definite established method for the classification of scars, and various criteria such as reasons for scar development and characteristics of the scars are concurrently used [1].

Scarring affects patients following trauma, burns, and surgical procedures.

Techniques

The techniques may be broken down into the categories of techniques of

1. Excision
2. Irregularization
3. Abrasion
4. Flap repair
5. Medical and adjunctive treatment.

Excision

- a. Incision placement
- b. Fusiform incision or fusiform scar revision(FSR)
- c. Scar repositioning
- d. Partial serial excision
- e. Tissue expansion

Irregularization

- a. Z-plasty
- b. W- plasty
- c. Geometric broken line closure(GBLC).

Abrasion

1. Scalpel abrasion
2. Shave excision
3. Dermabrasion
4. Laser

Flap repair

1. Loco-regional flaps
2. Distant flaps

Grafting (aesthetic unit grafting)

Medical and Adjunctive treatment

1. Silicone gel sheet application
2. Steroid injection
3. Avoidance of sunlight exposure and application of sun protective creams
4. Cosmetics and hair styling.

Objective

1. To study the behavior of scar with regards to:
 - a. Orientation of scar in relation to RSTL.
 - b. Effect of removal of tension at scar line by strapping of micropore or cyanoacrylate.
 - c. Various method of stitching technique.
2. To study the outcome of dermabrasion/CO2 laser in management of multiple pitted scarring of face, and as a final touch-up resurfacing of scar after scar revision.
3. To study the advantages and disadvantages of tissue expander in the management of large area scarring of face.

Scar revision is a tricky procedure, and our aim is formulate guidelines by noting the above observations, so that the best option is selected and scar becomes less visible.

The Study was conducted on patients visiting the outpatient department and those admitted to the Plastic Surgery, S.N Medical College, Agra, during last one year.

Patient selection criteria

Inclusion criteria

1. All types of small to moderate sized post traumatic, post-infective/ inflammatory, post-surgical, or post burns.
2. Moderate sized area scarring resulting from trauma or burn involving only two or three aesthetic units of face.
3. Multiple small pitted post-acne or post-pox scarring

Exclusion criteria

1. Post-burn facial scarring involving entire hemiface or full face.
2. Post-burn facial scarring leading to severe ectropion of lips or eyelids.

Recordings of the patients were done on the following heads:

Relevant history

- Age of the patient
- Etiology of scarring
- Any keloidal or hypertrophic tendency
- Duration of scar(age of scar)
- Any previous surgical intervention.

Detailed local examination

- Site and number of scars.
- Type of scar(depressed or elevated, keloid or hypertrophic, linear or area scar etc.)

- Orientation of scar in relation to natural crease or RSTL
- Any contour abnormalities
- Condition of surrounding skin.

Photographic recordings were done in preoperative, 1 week, 3 months and 6 months postoperative periods.

Observations were recorded under the following heads:

- Scar monitoring by noting changes in the length width, elevation/depression, colour and itching.
- Patient satisfaction.

Clinical procedures

Suturing techniques

For straight-line closure we have used subcutaneous 4-0/5-0 chromic catgut or 5-0/6-0 Vicryl stitches with buried knots, followed by running subcuticular 6-0 nylon stitches, for W-Plasty, Z-Plasty or curved line closure, we have used subcutaneous 4-0/5-0 chromic catgut or 5-0/6-0 vicryl stitches with buried knots, and interrupted 6-0 nylon stitches for skin closure.

Excisional techniques

Fusiform scar revision

This was the most common technique employed in removing small scars. Excisions were designed to fall into one of the favorable areas (e.g. in(1) natural facial contour lines or creases (2) RSTL,(3) the junction of one facial landmark or aesthetic unit with another or (4) inside the hairline). The opposing angles were measured less than 30 degrees. Careful attention was given to closure with precise alignment of tissue layers and skin eversion.

The long axis of the fusiform excision should be straight and lines whose ends fall in the same RSTL. It does not have to follow the direction of scar. The short axis should not be too wide as compared to the long axis so that the dog ears will not be created at the extremities. The scalpel should cut the skin at right angle to the surface. Some undermining was done for slight skin border eversion while suturing. Scar below the skin was not removed, as it will serve as a support for the revised skin scar. In cases of depressed scar we have also used turnover flap of adjacent subcutaneous fatty tissue underneath the skin closure to fill the depression.

Meticulous attention was paid to closure in fusiform excision, and care was taken to follow the natural skin lines as they gently curve, rather than creating a straight line where none normally exists.

Scar repositioning

Small, existing scars that lie close to RSTL or another favorable site was repositioned using excision techniques. For example scars on the midface were moved to the nasolabial crease, those on the forehead to the hairline and those on the lateral cheek into the periauricular crease. Repositioning of scars often involves the sacrifice of some tissue lying between the scar and the more favorable site, so it is important to be certain that repositioning will not cause greater deformity before proceeding with surgery.

Partial serial excision

Large scars or old skin grafts that cannot be eliminated in one procedure without causing distortion or gross asymmetry was approached by using the method of partial serial excision. Removing a portion of the scar and advancing only the normal adjacent skin over several procedures eliminated scar. The speed at which this can be achieved depends on the size and location of the lesion and the age of the patient. It is to be noted that the closure of wound should be supported by subcutaneous non-absorbable suture (except in the final revision) so as to prevent scar widening in between the procedures.

Tissue Expanders

More coverage may be obtained with one surgical procedure. The selection of tissue expanders was based on the size of the 'true' skin defect and not on the measured size of the skin lesion to allow over expression, expanders with widths of twice the calculated distance were implanted (using 2-to-1 base dimensions rule) because whatever the size or circumferential shape of a tissue expander, the "mound" of tissue following its placement subcutaneously has a cross section eventually approximating to a semicircle. If the width of flat expander is twice the radius ($2r$), then the expanded surface is $2\pi r/2$, which approximate to $3r$. The gain is thus r , or half the width of the flat expander. An expander twice as wide as the defect to be covered off thus produces an excess of tissue sufficient to cover both donor site and defect, irrespective of shape (Fig.3) to improve the accuracy of the measurement for lesions in a complex topographical location like the anterior neck, we are using two or more lines drawn from the one fixed bony point to the another fixed bony point across the affected skin.

During the expander insertion we go through the previously scarred area (preferably by a radial incision) to avoid any new scar and to save maximum of normal tissue for expansion. In the post-operative period we provide antibiotic coverage (1st generation cephalosporin) for two weeks. Expansion was started on 14th post operative day, and stitches were removed on 21st day.

Expansion was done by distilled water or normal saline at weekly interval by using 23 gauge scalp-vein set fitted to a syringe. A flap, that was 30-50% larger than the calculated requirements was used as a rough guide to decide the time to stop the expansion.

Irregularization techniques

Z-plasty

Z-plasty was used where the breaking up of straight-line scar that crosses the RSTL was needed, or correction of a lower lid ectropion in contracted linear scar.

Three basic technical principles of Z-plasties were followed during its execution: (1) diagonals should always fall over the scar; (2) the diagonals and limbs of each Z-plasty should always be of equal length on the face 1 to 1.5 cm is the size most frequently used because scars resulting from larger Z-plasties are usually more noticeable. Larger Z-plasties (2-3cm) were occasionally used in very deep and depressed scar where the having effect is of paramount importance. Smaller single Zs(0.5) were used to improve small ATL scars.(3) the longer the scar, the more Zs should divide it, so that after

transportation of the flaps the added length in one direction at the expense of the other direction is taken diffusely from the surrounding areas. In multiple Z-plasties segments should not be smaller than 1cm because of its tendency to result in a series of bump and furrows. The limbs should be as close to the RSTL as possible but never over 60° from the diagonal. Multiple Z-plasties were employed in trapdoor scars and in large contracted oblique scars. Z-plasties was avoided in scars that require disruption but that may not tolerate the elongation that inevitably results.

Meticulous care was taken in suturing the Z. The tip of the flap will require a mattress suture plus a very superficial interrupted stitch to make sure that the tip does not invert.

W-plasty

W-plasty is an irregularization technique used to treat antitension line (ATL) scars and consists of excising consecutive small triangles on each side of a wound or scar and imbricating the resultant triangular flaps. After W-plasty, scar becomes accordion like that has some degree of elasticity. W-plasty was employed for the ATL scars on the forehead, cheeks, chin and nose, although the Z-Plasty is more appropriate to areas about the eyes and mouth. The running W-plasty was used to break up long scars running perpendicular to RSTL on the cheek.

It was also used effectively over curved areas such as the mandibular angle to irregularize a long, complex, straight-line scar.

The technique begins with the marking out of a series of consecutive triangles (w's) along the wound or scar edge. The arms should be between 5 mm and 7 mm in length, and one arm of the triangle should be drawn in parallel to the RSTL. After excision of the triangles, superficial undermining of adjacent tissues is performed, and the triangular shaped flaps are then imbricated. Care should be taken to preserve the subcutaneous scar tissue, because this can provide a stable bed for new scar healing.

Abrasion techniques

Dermabrasion

Shallow, crater-like facial scars were treated with dermabrasion. The surrounding tissue is brought down to a level closer to that of the depressed region. This allows the lesion to blend into the surrounding normal skin because less of a shadow is created by the depression to draw attention to the scar.

Dermabrasion was also used in conjunction with other scar revision techniques in a sequential fashion. Running W-plasty and Z-plasty revision, if indicated were followed by dermabrasion to better blend the new scar with the surrounding skin.

We have used No. 40, 60 and 100 flint papers, which are sterilized by autoclaving and cut into strips. These strips were wrapped over the back of the thumb forceps to be used during abrasion.

Laser Abrasion

Various types of laser may be used as laser resurfacing of face in place of dermabrasion. We have used this CO2 laser

(continuous mode at 5-7 watts, and the beam was defocused) to give final touch-up to the selected, previously revised scars.

Flap repair

Loco-regional

Various types of loco-regional flaps like advancement, rotation, transposition, interposition, limberg and bi-lobed flaps were used for scar revision and camouflage.

Grafting

Grafting was usually avoided when other methods are available, as matching facial skin colour and texture with a graft is difficult and the results may prove esthetically disappointing. But even if grafting was the only option available, the principle of esthetic unit grafting was applied.

We have used full thickness skin graft harvested from the post auricular region to apply over the area scarring (e.g. over the lower half of the dorsum of the nose). Since the scars are usually depressed, scar tissue is superficially deepithelised, and the margins are undermined to fit the FTG edge to edge. Careful edge-to-edge stitching with bolster dressing is applied.

Medical and Adjunctive treatment

Steroid Injection

Injection triamcinolone (Kenacort) 10-20ng/ml was given intralesionally in the postoperative period where the scar line was showing the tendency of hypertrophy or keloid formation.

Adjuncts to healing

Revised wound was immobilized and was carried out for as long as the patient were able to tolerate it. We have used anti-tension taping after stitch removal using skin strips or cyanoacrylate, especially in areas of facial animation, to prevent stretching of scars.

For antitension taping 3 to 5 mm wide strips of micropore were applied perpendicular to the scar line after pulling the surrounding skin towards the center. This application method is taught to the patients so that they can wash their face daily and able to apply antitension taping by them in front of a mirror. For more camouflaging affect, skin- coloured tapes (e.g. Handyplast) may be used to avoid visibility of the tapes. We are also using an alternative method of antension strapping by using common Feviquik glue (cyanoacrylate). After washing the face and drying it for few minutes, the feviquik glue is applied in a strip fashion perpendicular to the scar direction after pulling the surrounding skin towards the center. The glue is allowed to dry for 2 to 3 minutes in the same position. The patients are instructed not to peel the membranous coat of the glue during washing of the face. This type of antitension strapping usually remains in place for atleast 7 to 10 days and allows the patients to wash their faces daily without need to change the strapping coat. This method of strapping is very less visible, very cheap and can be reapplied when it peels off. Patient's compliance also increases greatly by this method of strapping.

Antibiotic ointment with petroleum base was applied along the incision lines, and on denuded and dermabraded areas to prevent drying, skin desiccation, and crusting all of which may prolong healing. Prolonged (usually one month) use of ointment was advised on the wound that followed the dermabrasion.

Direct sunlight exposure was avoided for 6 months, and sun protective cream (combination of Oxybenzone USP 3.0% w/w & Octyl Methoxycinnamate USP 5.0% w/w with SPF value of 10+) was applied over the scar to prevent pigmentary abnormalities.

Similarly, massage was advised on a new scar, on initial epithelial healing has occurred. This may serve to realign collagen fibers in the scar and allow it to soften more rapidly.

Silicone gel sheet &/or pressure therapy by moulds and casts to prevent or treat hypertrophic tendency. We advise our patients to apply silicone gel sheet after washing their face and the gel sheet. Face and sheet allowed to dry for few minutes, and then the sheet is applied which is supported at their place by few micropore strips.

Adjuncts to Scar Revision and Comouflage

In scars that cannot be further improved with revision and that remain unsightly, camouflage with makeup may be the patient's only recourse. Hair styling may serve to camouflage particular scars. Though the art of makeup application and hair styling, desirable features may be enhanced and attention drawn away from those that are less appealing. In many patients, this can be a significant aid to regaining self esteem and to the acceptance of facial scars.

RESULT AND DISCUSSION

Demographic dissemination of subjects

The total numbers of 54 subjects were included in the study form out patients departments, department of plastic surgery unit, department of surgery, S.N. Medical College, Agra, with the chief complaint of the scar. The subjects included in the study were briefed about the study and informed consent form was signed by all the patients before starting the procedure. The patients were divided into groups broadly into male and female and subdivide as per their material status and age groups, the age group was consider, 15-25, 26-35 and 36-45 years, the maximum number of female patients were reported during study period due to different region of their injury, about 64.81%, and only 35.19% male patients, and maximum were unmarried 89.47%. The three age groups included 15-25, 26-35 and 36-45 years of the male patients, 42.10%, 52.63% and 5.26% respectively, and for female patients 37.14%, 57.14% and 5.71%

Table 1 Distribution of patients

Gender	Subjects	Marital Status		Age Group (Years)		
		Unmarried	Married	15-25	26-35	36-45
Male	19	17	02	08	10	01
Female	35	33	02	13	20	02

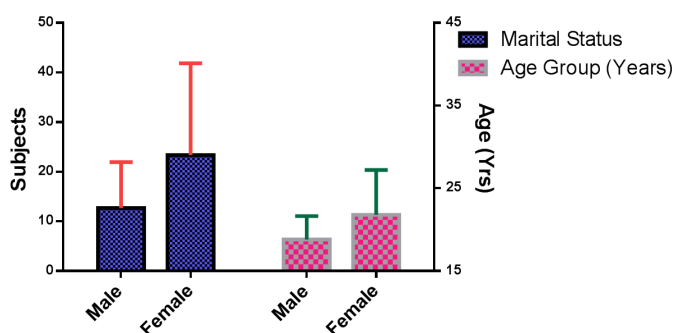


Figure 1 Representation the distribution of Subjects according to their Sex, Marital Status, and divided age group (15-25, 26-35 & 36-45)

respectively, maximum number of patients were found in the age group 26 to 35 years for both male and female subjects, all the data summarized in table no.1, about 95% patients reported for the study were under the age group 15 to 35 years, shown in Figure no 1.

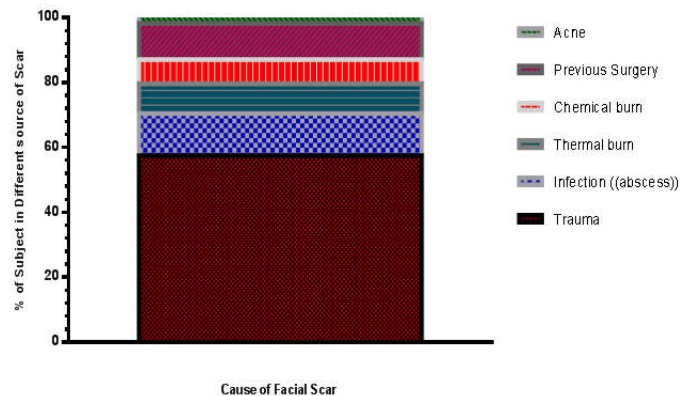
Table No. 2 Occupation of the subjects

Occupation	Subjects
Students	41
Housewives	1
Self-employed	8
Government employed	4

In table no 2, clearly showed that 75.92% patients of scar belonged from student category, which shows young age psychological response towards scar.

Table no 3 Etiology of Scar

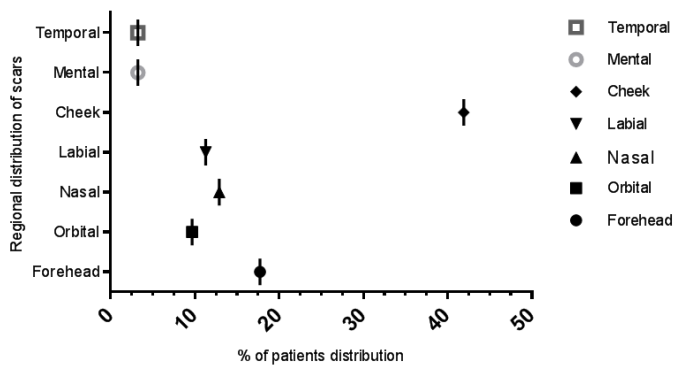
Sr. No	Source	Subjects
1	Trauma	31
2	Infection (abscess)	7
3	Thermal burn	5
4	Chemical burn	4
5	Previous Surgery	6
6	Acne	1



The maximum number of patient was reported as trauma cases of scar, about 57.41% and after that infection, thermal burn, chemical burn, previous surgery and acne, 12.96%, 9.26%, 7.41%, 11.11% and 1.85% respectively, the trauma cases included, dog bite, road traffic accident and human nail bite etc, and infection (abscess), thermal burn, due to blast in crackers, burn of hot metal and due to application of lime over mole. The chemical burn included the application of a high dose of medicine or cream application over the white patch.

Table no 4 Regional Distribution of Scar in Relation to Aesthetic Unit of Face

Aesthetic unit of face		Total number of scar			
		Area Scar	TL Scar	ATL Scar	
Forehead	Frontal	8	2	-	6
	Supraorbital	3	1	1	1
Orbital	Upper lid	3	-	2	1
	Lower Lid		2	1	-
Nasal	Dorsum	5	3	-	2
	Tip	1	-	1	-
	Side wall	0	-	-	-
Labial	Alar	2	1	-	1
	Soft triangle	0	-	-	-
	Upper lip	6	3	2	1
Cheek	Lower lip	1	-	1	-
	Infraorbital	3	-	3	-
	Zygomatic	3	-	1	2
	Buccomandibular	17	1	5	11
Temporal	Parotid masseteric	3	2	-	1
	Mental	1	1	-	-
		-	1	1	1



The regional distribution of scar was excluding multiple pitted post-acne scars managed by tissue expansion. The highest incidence of scars was found in cheek aesthetic unit about 41.93%, other larger group was forehead, 17.74%, only 2 scars over the mental region and 02 scars at temporal region were found, all the data was summarized in table no 4 and presented in figure no 3.

Various type of procedure for scar elimination

Some of the scars required a combination of the procedure, described in Table no. 5, common procedure employed for facial scar management was fusiform scar revision (FSR), elliptical excision and primary closure. This procedure was done on 45 scars in 35 patients. Another more frequently used method was W-plasty, 5 scars in 5 patients, subcutaneous turn over flat was used in 2 scars and 1 scars tissue grafting was performed to fill depressed scars. Dermaplaning was employed in 5 patients and laser abrasion was used in another 5 patients.

Table no 5 Procedure used for Scars Elimination

Procedure	No of procedures performed
ESR	45
W-plasty	5
Z-plastic	5
Dermabrasion or dermaplaning	5
Tissue expansion technique	4
Subcutaneous Fat flap	2
Limberg flap and other local flaps	3
Scar Tissue Grafting	1

Change in length of the scar after various revision procedure

The average change in the length of the scars after various revision procedures, fusiform scar revision there was 20.08%, about 1.20 time increased in the length of scar, while after w-plasty 113.15%, about 2.13 times increased in the length of the scar and after Z-plasty, there was%, about times increased in the length of scars, all the data summarized in table no

Table no 6 Change in the length of Scars after various revision procedures

Procedure	Avg. Ore-op length	Avg. Post-op length	Avg. change in length (mm)	Percentages increased	Time increases in length
FSR	31.12	37.38	6.25	20.08	1.20
W-plasty	38.0	81.0	43.0	113.15	2.13
Z-plasty	24.50	74.0	49.5	202.04	3.02

Post-operative widening of scar in relation to aesthetic unit and RSTL

The average postoperative widening of scars in relation to an aesthetic unit of the face and scar direction with RSTL, the study showed maximum widening in upper labial unit with scar direction 60-90° with RSTL (4mm). Next to this was a Bucco-mandibular subunit of the cheek with scar direction 60-90° (3 mm) and the same subunit with scar direction 15-60° (2.2 mm). Minimum scar widening was in the forehead and orbital unit with scar direction <15°, summarized in table no 7.

Table no 7 Post-operative widening of scar in relation to aesthetic unit of face and scar direction (in relation to RSTL)

Aesthetic unit of face ↓	Direction of scar in relation to RSTL →	Avg. widening of scar in mm		
		<15°	15°-60°	60°-90°
		0.5 (mm)	1 (mm)	0.62 (mm)
Forehead	Frontal	0.5	1	0.62
	Supraorbital	0.5	-	0.5
	Upper lid & eye brow	0.5 (eye brow)	2 (lid)	0.5 (eye brow)
Orbital	Lower Lid	-	-	-
	Dorsum	-	1.5	1
	Tip	-	0.5	-
	Side wall	-	-	-
Nasal	Alae	0.5	-	-
	Upper lip	0.8	1.2	4
Labial	Lower Lip	-	2.0	-
	Infraorbital	0.62	-	-
	Zygomatic	-	0.5	0.5
	Buccomandibular	1.5	2.2	3.0
Cheek	Parotid masseteric	1	-	2.0
Mental		0.5	1	-
Temporal		-	1	2

Postoperative widening of scar in relation to age

Table 8 summarized the post operative widening of scars in various age groups in relation to the direction of the scar to RSTL. The maximum widening was noticed in the age group of 20-29 years.

Table no 8 Postoperative widening of scar in relation to age

Age group	Age post-op widening of scar (in mm) with scar direction in relation to RSTL		
	<15°	15°-60°	60°-90°
0 - 9	-	0.5	-
10 - 19	0.75	1.42	1.38
20 - 29	0.80	2.2	2.0
30 above	.5	1.2	-

Complication of scar revision

The complication of scar revision procedure, the most common and refractory complication was stretching of the scar >3 mm, optimized in 14.28% patients, which was managed by prolonged strapping of scar and two of them required a further scar revision. The other most common complication was mild to moderate hypertrophy of scar, which was then managed by silicone gel sheet (SGS). The complication was infected cyst formation in one patient with FTG over the dorsum of the most scar, managed by cyst drainage, antibiotic and SGS. Hyper pigmentation was seen in 6 patients, which was managed by strict avoidance of direct sunlight exposure, sun protective cream, SPF 10+ along with 2% hydroquinone cream.

Elevation of the margin of scar mild irregularity was seen in 6 patients, 5 of them were managed by laser abrasion and one by derma abrasion.

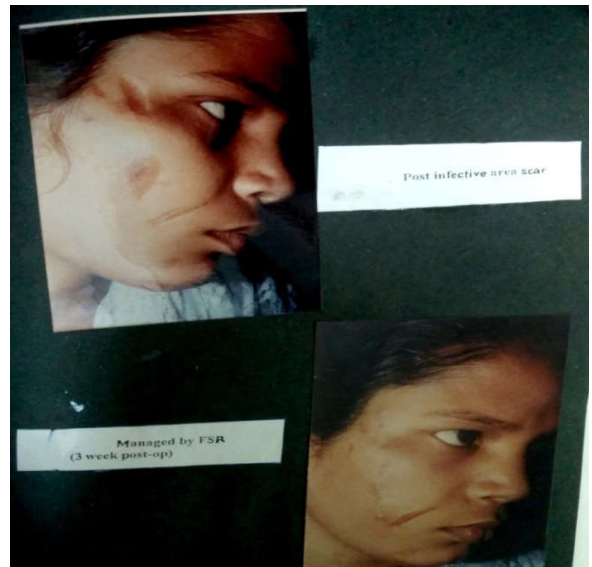Table no 9 Complication of scar revision procedure

Complications	Subjects
Hypertrophy of scar	5
Scar stretching	7
Infected cyst formation and swelling of FTG	1
Hyperpigmentation	6
Elevation and irregularity of Margins	6

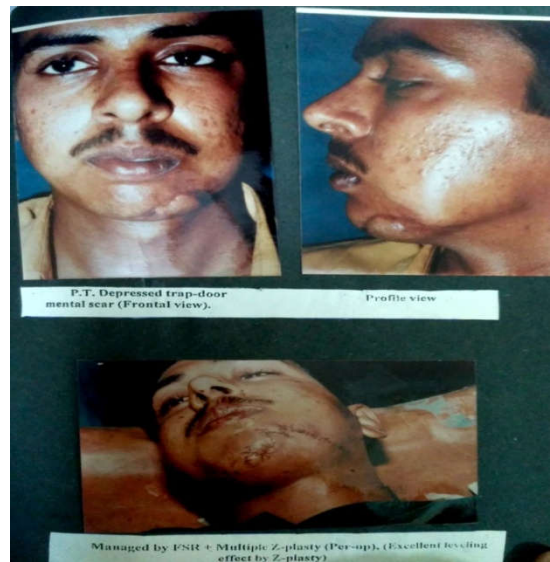Patients' satisfaction after scar revision procedures

Satisfaction	Subjects	Remark
Satisfied	32	-
Scar not improved ±	11	One lost to follow up in post-op period
Unsatisfied (scar worsened)	5	Most common cause for dissatisfaction was scar widening

The patients satisfaction ration for scar revision procedure, 65.30% patients were satisfied by the applied procedure, 22.44% complained that their scar was not improved in good condition but remained as preoperative level and the unsatisfied was about 10.20%, because their scars become worse than their pre-operative appearance, mostly because of stretching of scars.



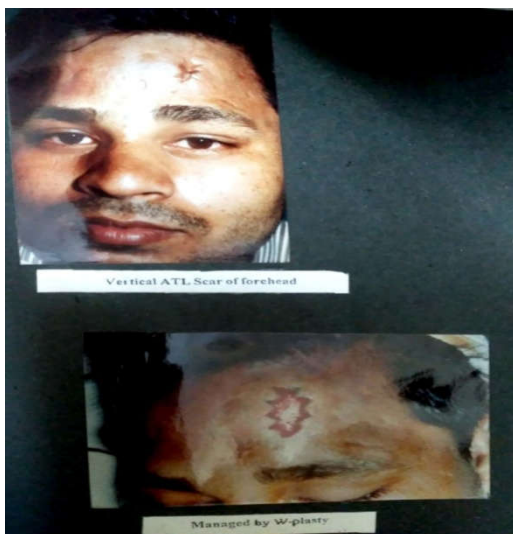Managed by FSR 3 week Post-op



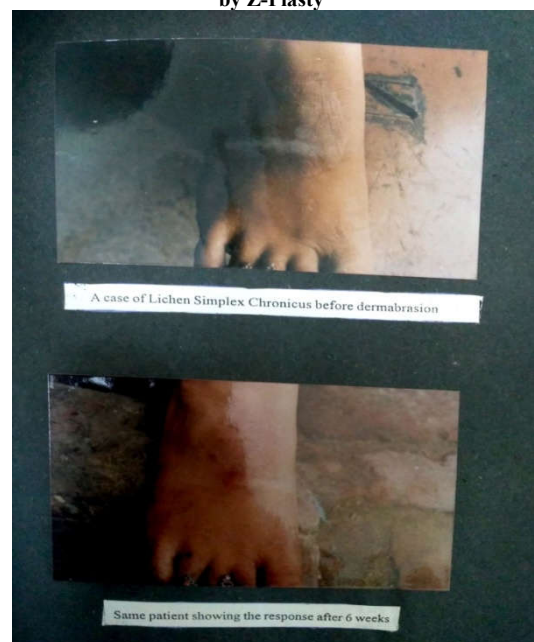
Managed by FSR+multiple Z-Plasty (Per-op), Excellent leveling effect by Z-Plasty



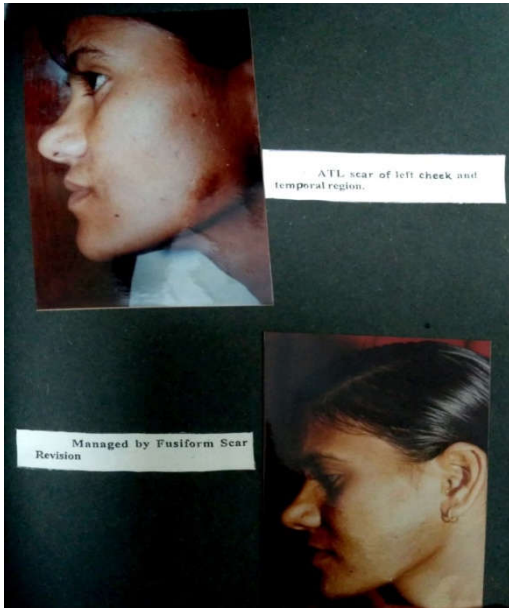
Post-op right profile view



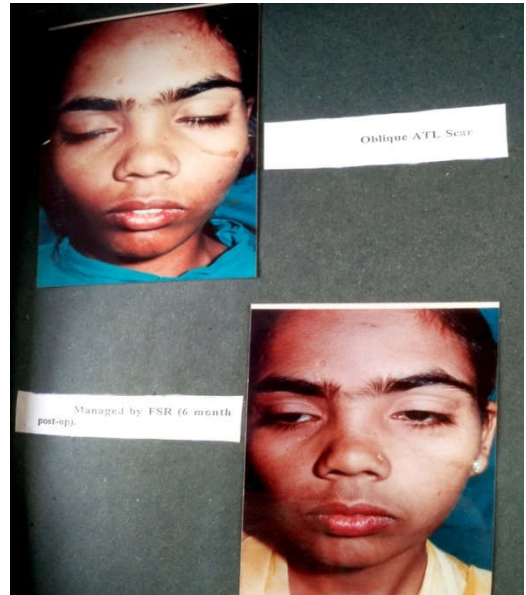
Managed by W-Plasty




Dermabrasion technique response after 6 weeks




Managed by Fusiform Scar Revision



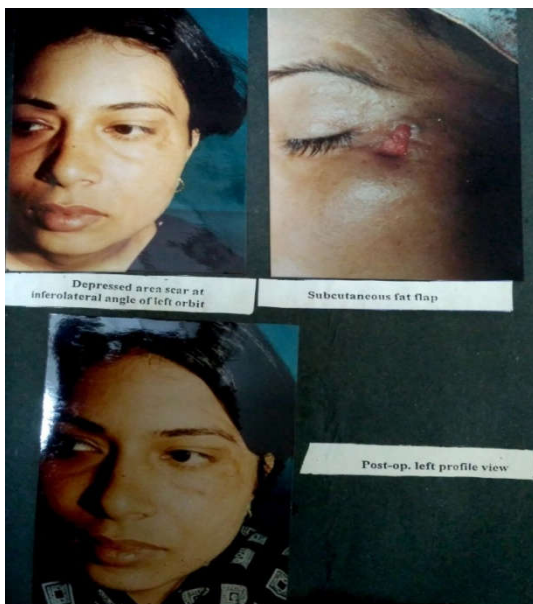Managed by FSR (6 month Post-Op)




Photograph 12 Week Post Peel




Managed by FSR



Subcutaneous Fat Flap



Managed by subcutaneous Fat Flap+ FSR



Managed by FSR 3 month Post-Op

CONCLUSION

The study on 67 scars on 54 patients was conducted in the last one year. We found that most of the linear scars and smaller area scars with long axis in the direction of RSTL are effectively managed by Fusiform Scar Revision (FSR) technique. Revision of forehead scars provided good results by any of the revision procedures as it moves less during facial expression in comparison to cheek and lips. It also has a good firm convex bony support. Orbital scars also respond favorably to scar revision by Fusiform Scar Revision (FSR) because of plenty of loose and thin non sebaceous skin in this aesthetic unit. The scar resulting from FSR may be favorably hidden in the natural skin folds. Labial and cheek aesthetic unit scars were difficult to manage due to their strong propensity of post-operative widening inspite of taking all the precautions in suturing and post-operative strapping. This is probably because the skin over the cheeks and the lips has a high degree of movement during facial expressions.

Scars over the upper part of dorsum of nose can be easily revised by FSR. Post operative strapping by micro pore strips or cyanoacrylate provides equally effective prevention of widening. On the other hand cyanoacrylate strapping is cheap, easy to apply and once applied remains on the face for 5-7 days, allowing the patients to wash their faces daily. Deepithelised scar tissue and subcutaneous fat flap are very useful and effective ways for the treatment of depressed scars. Dermabrasion provides good result in case of generalized pitted post acne facial scarring. Dermabrasion is useful tool for the final touch up procedure after scar revision to remove remaining minor irregularities. Flint paper dermabrasion is a cheap and effective method of Dermabrasion. Prevention of sun exposure is very important for a good result. Though the number of patients managed by laser abrasion in this study is quite small, it is a useful and rapid method for removal of minor postoperative irregularities remaining after scar revision. The biggest disadvantage of laser abrasion is the astronomically high cost of the equipment. Tissue expansion technique is useful in the management of post-burn or post-traumatic large area scarring of face. Other than the very high cost of expanders there are various complications related to it like, pocket infection, implant exposure, thinning and necrosis of overlying skin, post operative contraction of flap and webbing of neck, temporary unsightly appearance etc. For the optimal management of facial scars using tissue expansion the true defect of a scar should be calculated. Expanders are best inflated at weekly intervals to prevent excessive thinning of the overlying flap. Careful lookout should be kept for appearance of erythema, excoriation and ulceration.

References

1. M, Pirkanmaa, Assessment of Skin Scars in Clinical Practice and Scientific Studies Academic Dissertation presented on December 2nd, 2011.
2. Seong Hwan Bae, Yong Chan Bae, Analysis of Frequency of Use of Different Scar Assessment Scales Based on the Scar Condition and Treatment Method, Archives of plastic surgery, Arch Plast Surg, 2014, March; 41(2), 111-115.
3. Regina Fearmonti, Jennifer Bond, Detlev Erdmann, and Howard Levinson, A Review of Scar Scales and Scar Measuring Devices, e Plasty Volume 10, 354-363.

How to cite this article:

Om Prakash Gupta *et al* (2018) 'A Study of Cosmetic Evaluation of Various Methods of Scar Correction', *International Journal of Current Advanced Research*, 07(2), pp. 10329-10337. DOI: <http://dx.doi.org/10.24327/ijcar.2018.10337.1745>
