



**Case Report**

**TRUE INCA BONE WITH UNILATERAL EPIPTERIC BONE - A RARE CASE REPORT**

**Hema Nagpal\*<sup>1</sup>, Vishal Modgil<sup>2</sup> and Ruchi Sharma<sup>3</sup>**

<sup>1,2</sup>Department of Anatomy, ITS Dental College, Muradnagar

<sup>3</sup>Department of Anatomy, AIPT, Noida

**ARTICLE INFO**

**Article History:**

Received 14<sup>th</sup> November, 2017

Received in revised form 6<sup>th</sup>

December, 2017

Accepted 18<sup>th</sup> January, 2018

Published online 28<sup>th</sup> February, 2018

**Key words:**

Inca bone, wormian bone, epipteric bone

**ABSTRACT**

The squamous part of the occipital bone consists of an upper membranous (interparietal) part and a lower cartilaginous (supraoccipital) part and in rare cases the membranous part may be separated from the supraoccipital part by a suture. It is then called as the interparietal or inca bone. We reported a rare case of true inca bone with unilateral epipteric bone and many wormian bones in a human skull. There is also presence of bilateral squamatization of coronal suture in the distal part. Knowledge of inca bone and wormian bone is important for the neurosurgeons orthopedic surgeons, anthropologists, radiologists and forensic experts.

*Copyright©2018 Hema Nagpal., Vishal Modgil and Ruchi Sharma. This is an open access article distributed under the Creative Commons Attribution License, which permits unrestricted use, distribution, and reproduction in any medium, provided the original work is properly cited.*

**INTRODUCTION**

Skull comprises of many paired and unpaired bones. These bones develop either by intra membranous ossification or by endochondral ossification. But the occipital bone which is situated at the back and lower part of the cranium, shows both type of ossification. The curved, expanded plate of occipital bone behind the foramen magnum is named as squama occipitalis. Extending lateralward from this on either side are two curved lines, one a little above the other. The upper line is often faintly marked, is named as highest nuchal line. The lower line is termed as superior nuchal line. That part of the squama which lies above the highest nuchal lines is named as planum occipitale, the part below the highest nuchal line is termed as planum nuchale. The planum occipitale of the squama is developed in membrane, and may remain separate throughout life then it known as interparietal bone or inca bone. The rest of the bone is developed in cartilage. The number of nuclei for the planum occipitale is four, two appearing near the middle line about the second month, and two some little distance from the middle line about the third month of fetal life. The planum nuchale of the squama is ossified from two centers, which appear about the seventh week of fetal life and soon unite to form a single piece. Union of the upper and lower portions of the squama takes place in the third month of fetal life.<sup>1</sup>

HC Srivastava described more elaborate development of occipital bone.

*\*Corresponding author: Hema Nagpal*  
Department of Anatomy, ITS Dental College, Muradnagar

He described that the part above the highest nuchal line is interparietal part and part below is supraoccipital part. According to him the supraoccipital part develops both in cartilage and membrane, the part lying between the superior and highest nuchal lines known as the torus occipitalis transversus is ossified in membrane by a pair of centres. This segment of bone is labelled as the intermediate segment which probably never separates from the cartilaginous supraoccipital. This part of the supraoccipital represents the original membranous part of the primitive occipital bone of lower animals where the interparietals form part of the parietals. The interparietal bone lying above the highest nuchal lines develops in membrane by 2 pairs of centres, 1 pair for the lateral plate and the other for the medial plate. Each centre consists of 2 nuclei. Failure of fusion between these centres or their nuclei with each other and with the supraoccipital part may give rise to interparietal bone or true inca bone. This is the true interparietal bone which has migrated from the parietals of lower animals during evolution to become part of the occipital bone in man.

When it appears as an anomaly in the form of an independent separate bone, the suture between it and the supraoccipital lies at the level of highest nuchal lines.<sup>2</sup>

Extra bones pieces which are present in the sutural joints of skull are known as wormian bones. These pieces of bones are named after the Danish physician 'Ole Worm' who first described them. These are irregular bones that ossified from extra ossification centres in the bones of cranium. Epipteric bone is the small sutural bone found in the region of pterion.

Inca bones are clinically very relevant in skiagraphy of human skull. Sometimes inca bones may be misdiagnosed as a fracture line on x-rays.<sup>3</sup> Inca ossicles may be beneficial for personal identification in both forensic medicine and anthropology.<sup>4,5</sup>

### Observations

The present case of Inca bone was obtained as an incidental finding in adult skull from the Department of Anatomy, ITS Dental College, Muradnagar, U.P. India. We also reported five wormian bones, bilateral partial squamation of the coronal suture and incomplete metopic suture in the same skull (Fig1). The suture separating the inca bone from the rest of the occipital bone was present at the level of highest nuchal line and at a distance of 1.8 cm from the external occipital protuberance. We also measured the dimensions of inca bone which were 5.2 X 6.4 (cm). Right parieto incal ratio is 2.5:1 and left parieto incal ratio is 2.6:1. The occipito incal ratio is 1.2:1.

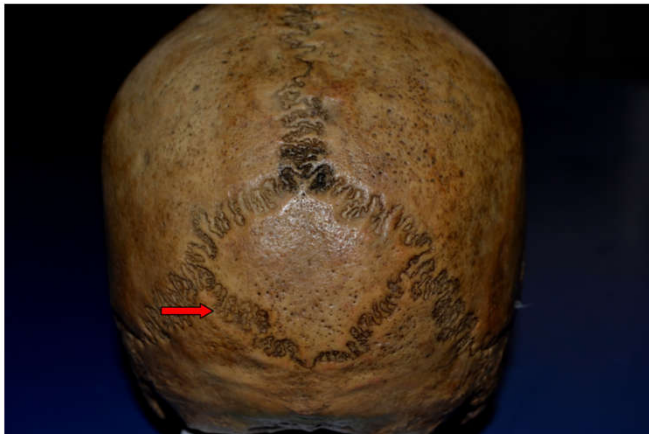


Fig 1 Photograph showing large inca bone and arrow indicate suture at the level of highest nuchal line

We observed five wormian bones which were present at the site of left pterion (epipteric bone), left parietomastoid suture, distal end of left occipitomastoid suture and a pair of small sutural bones in the region of frontonasal suture. Bilateral partial squamation of the coronal suture was present in its distal part (Fig2).

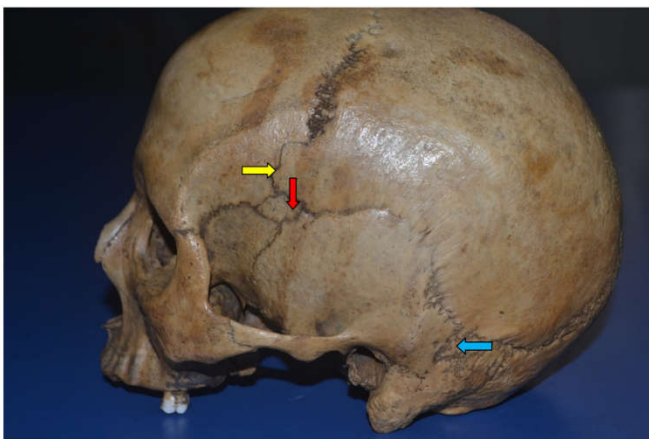


Fig 2 showing partial squamation of coronal suture (yellow arrow left epipteric bone, red arrow and left parietomastoid bone, blue arrow)

The occurrence of inca bone or interparietal bone is quite rare. Srivastava, studied 620 skulls in 1992 and he found complete

separate interparietal bone in only three specimens (0.8%). According to the measurements reported by Srivastava the distance of the suture of inca bone was 2 cm above the external occipital protuberance and 0.4 cm above the superior nuchal line near the lambdoid suture. He stated that when interparietal bone develops as a complete separate bone, the suture between it and rest of the occipital bone lies at the highest nuchal line. The present case report correlates well with the study of Srivastava.<sup>2</sup> In 1998 Yucel *et al.* reported the incidence of interparietal bones in 2.8% of the skulls. They did not report complete separate interparietal bone in any of the skulls in their study.<sup>6</sup> In 1986 Saxena *et al.* in a Nigerian study reported the incidence of interparietal bone in 2.5% of the skulls.<sup>7</sup> In a central Indian study done by Marathe *et al.* 2010 reported the presence of Inca bone in 1.315% of the skulls.<sup>3</sup> In a study done by Pal *et al* in gujrati population incidence of inca bone was reported to be 2.6%.<sup>8</sup>

Matsumura *et al* stated that the inca bones have their lower edge situated slightly above the external occipital protuberance. In contrast the sutural bones have an irregular arrangement and they do not possess a triangular line as in the case of inca bone.<sup>9</sup> So in the current case report, the additional bone with its base situated above the external occipital protuberance, can surely be labeled as the true interparietal or the inca bone.

Wormian bones are present in the sutures or at sites of anterior and posterior fontanelles. Wormian bones are often seen in the lambdoid suture. According to many radiologists more than ten wormian bones are considered to be abnormal. Wormian bones are associated with many disorders including Down syndrome, Progeria, Hypothyroidism, Rickets, Pyknodysostosis etc. In radiographs they mimic fracture lines and may be mistaken as a fracture of occipital bone. Wormian bone present at pterion may produce complications in neurosurgical procedures like burr hole over there may cause inadvertent penetration of orbit. So the radiologists, forensic experts, neurosurgeons, orthopedic doctors, anthropologists and anatomists should be aware about the presence and importance of inca bones and wormian bones.

### References

1. Williams PL, Bannister LH, Berry MM, Collins P, Dyson M, Dussek JE, Ferguson MWJ. Gray's Anatomy. 38th Ed., London, Churchill Livingstone. 1995; 583-606.
2. Srivastava HC. Ossification of the membranous portion of the squamous part of the occipital bone in man. *J Anat* 1992; 180, 219-24.
3. Marathe RR, Yogesh AS, Pandit SV, Joshi M, Trivedi GN. Inca - interparietal bones in neurocranium of human skulls in central India. *J Neurosci Rural Pract.* 2010; 1: 14-16.
4. Shiono H., Muraoka S., Adachi H., Tabata N. & Morita M. An Os Incae in the occipital region of the cranium found during identification of skeleton. *Res. Pract. Forens. Med.*, 26:35-9, 1983
5. Purkait R. & Chandra H. The identity of Inca, medicolegal importance and suggested nomenclature of variants. *J. Anat.Soc. India*, 38(3):162-71, 1989.
6. Yucel F, Egilmez H, Akgun Z. A study of the interparietal bone in man. *Turk J Med Sci.* 1998; 28: 505-509.

7. Saxena SK, Chowdhary DS, Jain SP. Interparietal bones in Nigerian skulls. *J Anat.* 1986; 144: 235-237.
8. Pal GP, Tamakar BP, Routal RV, Bhagvat SS. The ossification of the membranous part of the squamous occipital bone in man. *J Anat* 1984;138:259-66.
9. Matsumura G, Uchiumi T, Kida K, Ichikawa R, Kodama G. Developmental studies on the interparietal part of the human occipital squama. *J Anat* 1993; 182, 197-204.

**How to cite this article:**

Hema Nagpal *et al* (2018) 'True Inca Bone with Unilateral Epipteric Bone - A Rare Case Report', *International Journal of Current Advanced Research*, 07(2), pp. 10022-10024. DOI: <http://dx.doi.org/10.24327/ijcar.2018.10021.1679>

\*\*\*\*\*