



Research Article

A STUDY OF CLINICAL OUTCOME AFTER PHACOEMULSIFICATION CATARACT SURGERY IN DIABETIC AND NON-DIABETIC PATIENTS

Onkar Bharatbhushan Chavan., Archana Sunil Nikose*, Pratik Narendra Mohod and Pradnya Mukesh Laddha

Salve Institute of Medical Sciences Hingna Road, Nagpur

ARTICLE INFO

Article History:

Received 10th November, 2017

Received in revised form 9th

December, 2017

Accepted 26th January, 2018

Published online 28th February, 2018

Key words:

Cataract surgery, phacoemulsification, diabetic retinopathy, progression of diabetic retinopathy

ABSTRACT

Purpose: To evaluate the clinical outcome and the progression of diabetic retinopathy after phacoemulsification cataract surgery in diabetic and non-diabetic patients.

Materials and Methods: This prospective study included 40 diabetic patients with or without diabetic retinopathy and 80 non-diabetic patients. All patients underwent uncomplicated phacoemulsification surgery with clear corneal temporal incision with foldable intraocular lens implantation. Follow up was done on day 1, day 7, after 1 month, 3 months and 6 months. During follow up all the patients underwent visual acuity testing and detailed anterior and posterior segment examination.

Results: The final best corrected visual acuity at the end of 1 month and 6 months was in the range of 6/9-6/6 in 95% of cases as well as controls. 2 diabetic cases (5.55%) without pre-operative diabetic retinopathy developed mild diabetic retinopathy at the end of 6 months. One case (2.5%) where vision was deteriorated from 6/12 to 6/36 due to progression of diabetic retinopathy.

Conclusion: The final visual outcome was improved in both the groups and was comparable. The progression of diabetic retinopathy was related to the duration of diabetes and the uncontrolled diabetic status and not to the uncomplicated phacoemulsification surgery.

Copyright©2018 Onkar Bharatbhushan Chavan et al. This is an open access article distributed under the Creative Commons Attribution License, which permits unrestricted use, distribution, and reproduction in any medium, provided the original work is properly cited.

INTRODUCTION

Diabetes is the commonest metabolic disorder affecting the people all over the world. As per WHO estimates, globally, 422 million adults aged over 18 years were living with diabetes in 2014. South-East Asia and Western Pacific Regions accounting for approximately half the diabetes cases in the world. Diabetes caused 1.5 million deaths in 2012. Higher-than-optimal blood glucose was responsible for an additional 2.2 million deaths as a result of increased risks of cardiovascular and other diseases, for a total of 3.7 million deaths related to blood glucose levels in 2012.^[1] India has the distinction of having the largest number of people with diabetes. According to Diabetes Atlas published by the International Diabetes Federation (IDF); there were an estimated 40 million persons with diabetes in India in 2007. The number is predicted to rise to almost 70 million people by 2025. The countries with the largest number of diabetic people will be India, China and USA by 2030.^[2] Patients with diabetes mellitus (DM) have a higher prevalence of lens opacities^[3] and develop cataract at an earlier age than non-diabetics.^[4]

It has been estimated that up to 20% of all cataract surgery is performed on diabetes patients.^[5] Many such patients have pre-existing diabetic retinopathy (DR) at the time of cataract surgery. Cataract in diabetes patients reduces their visual acuity (VA), renders adequate examination of the retina more difficult or sometimes impossible, and makes photocoagulation of DR more difficult. Therefore, it is important to perform cataract surgery for visual rehabilitation.

Studies have reported the progression of retinopathy after extra capsular cataract extraction (ECCE)^[6] and suggested to delay cataract surgery especially in patients with more advanced diabetic retinopathy.^[7,8] However, besides visual rehabilitation, a substantial percentage of diabetics require lens extraction to permit proper diagnosis and treatment of retinopathy. Earlier cataract extraction in diabetic patients, before macular oedema develops, may help stabilize retinopathy-associated macular oedema and improve the long-term visual prognosis.^[9]

With the progress of surgical techniques, the modern phacoemulsification is well known to have smaller incisions, quicker recovery of vision and less postoperative inflammation.^[10] The observations of few recent researches has also reassured us that phacoemulsification and posterior chamber lens implantation in diabetics do not aggravate retinopathy and have fewer postoperative complications (with

*Corresponding author: **Archana Sunil Nikose**

Salve Institute of Medical Sciences Hingna Road, Nagpur

the exception of transient corneal oedema) than in previous extracapsular series^[11,12].

The present research was thus conducted to study the clinical outcome after phacoemulsification in diabetic patients and to evaluate the progression of diabetic retinopathy in these cases.

MATERIAL AND METHOD

This hospital based prospective interventional control trial was carried out in rural based tertiary care centre for a period of 2 years during September 2015 to august 2017. The study protocol, patient information sheet, and consent form were approved by the Institutional ethics committee (Ethics committee registration No.ECR/88/Inst/MH/2013/RR-16) and followed the tenets of the declaration of Helsinki. By keeping power 80% and confidence 95% and ratio of cases to controls is 1:2, the sample size was 40 in cases and 80 in controls.

Patients were selected from the ophthalmology outpatient department and divided into two groups. Group I included 40 diabetic patients having cataract with or without diabetic retinopathy and group II included 80 non-diabetic patients with cataract.

Preoperatively all patient’s were informed in details regarding the study and informed consent was taken. All patients in both groups underwent detailed ocular and systemic examination. Ocular examination in the form of visual acuity, slit lamp examination, applanation tonometry, conjunctival smear, sac syringing, A scan was done. All underwent a detailed indirect ophthalmoscopy for grading of diabetic retinopathy and diabetic macular oedema. Systemic investigations like haemoglobin, fasting blood sugar, post meal blood sugar, glycosylated haemoglobin, urine albumin and sugar were done. In cases of diabetic retinopathy and diabetic macular oedema, patients underwent fundus fluorescein angiography and later treated accordingly by laser photocoagulation. Patients with diabetic macular oedema was advised optical coherence tomography. Standard protocols to manage diabetic macular oedema and diabetic retinopathy prior to cataract surgery were adopted.

Patients in both groups underwent phacoemulsification cataract surgery with clear corneal temporal incision with foldable intraocular lens implantation. Follow up was done on day 1, day 7, after 1 month, 3 months and 6 months. During follow up all the patients underwent detailed anterior and posterior segment evaluation.

RESULTS

Over half of the study subjects in both groups were between 51-60 years of age with mean age of cases and controls as 60.05 years and 60.34 years respectively (p-0.96).(Fig. 1)

Fig 1 Comparison of study groups as per Age

Age Group	Group		Total
	Cases	Controls	
51-60	23 57.5%	48 60.0%	71 59.2%
61-70	16 40.0%	30 37.5%	46 38.3%
71-80	1 2.5%	2 2.5%	3 2.5%
Total	40 100.0%	80 100.0%	120 100.0%
p- value - 0.96			

In our study, duration of diabetes was less than 5 years in 87.50%, 6-10 years in 7.50% and duration more than 10 years was noted in 5.00% of patients. Thus, 12.5 % of patients had duration of diabetes more than 6 years. (Fig.2)

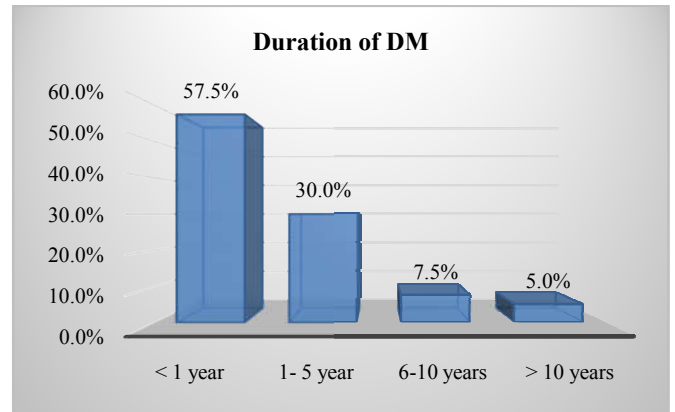


Fig no 2 shows the duration of diabetes among cases

All the cases were on anti-diabetic treatment, thus no difference was observed among cases and controls with respect to fasting and post-prandial blood sugar levels (p>0.05). Mean glycosylated haemoglobin level of diabetic cases was 4.6 mg%, showing good glycemic control.(Fig 3)

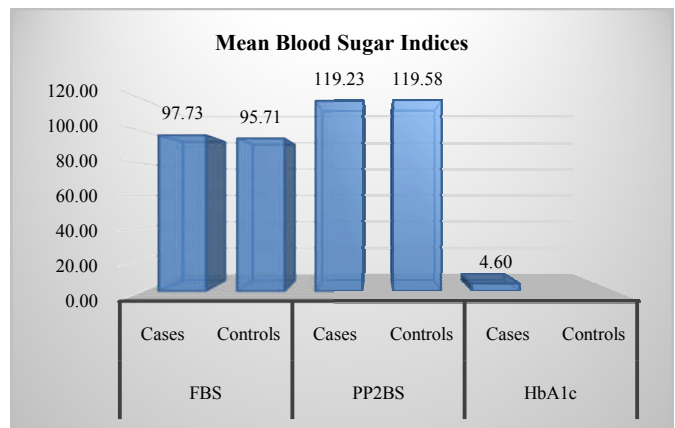


Fig no 3 shows comparison of study groups as per Mean blood sugar Indices

Preoperative diabetic retinopathy evaluation was done by using ETDRS grading system. According to which mild NPDR was found in 5 % and moderate NPDR was found in 5 % of patients. No DR was found in 90% of patients. Post-op BCVA was comparable between study groups at 1 and 6 month post phacoemulsification (p-0.129, 0.25).(Fig 4)

Post-op BCVA	1 month		6 month	
	Cases	Controls	Cases	Controls
6/6	35 87.5%	73 91.25%	35 87.5%	73 91.25%
6/9	3 7.5%	7 8.75%	3 7.5%	7 8.75%
6/12	2 5.0%	0 0.0%	1 2.5%	0 0.0%
6/18 or lower	0 0.0%	0 0.0%	1 2.5%	0 0.0%
Total	40 100.0%	80 100.0%	40 100.0%	80 100.0%
p- value	0.129		0.25	

A total of 90% cases had no evidence of DR prior to surgery while mild NPDR was seen in 2 cases and moderate NPDR was seen in 2 cases. Post-phacoemulsification 85% cases had no evidence of DR while 3 cases (7.5%) had mild NPDR and 2 cases (5%) had moderate NPDR. Severe NPDR was seen in

only 1 cases post-surgery. The difference was statistically non-significant. (Fig No. 5).

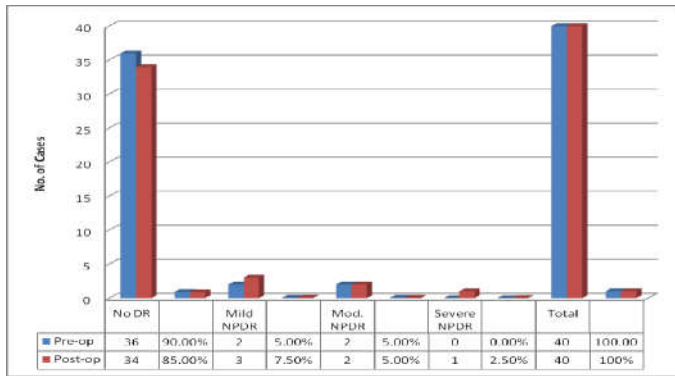


Fig No.5 shows diabetic retinopathy progression after phacoemulsification

DISCUSSION

A total of 120 patients fulfilling the inclusion criteria were included in this study.

In the present study, 80 patients were included in non-diabetic group, among these 37 were females and 43 males. The mean age of this group was 60.30 years. The diabetic group had 40 patients out of which 19 were females and 21 males. The mean age was 60.05 years.

Similar age presentation of cataract patients have been observed by other authors, Al-Sharkawy HT^[13] conducted a similar case control study, in their study mean age was 58.92 ± 6.88 years, whereas patients of non diabetic group their mean age was 60.69 ± 9.11 years. They did not match for age in their study and they observed there was no statistically significant difference in age between the two groups.

The Framingham study^[14] revealed a three-to fourfold increased prevalence of cataract in diabetic patients under the age of 65, and up to a twofold increased prevalence in patients above 65.

Another study by Li *et al.*^[15] reported mean age of cataract patients to be 64.8 years in diabetics and 65 years in controls which is in accordance with the our study.

Most of the cases had been diagnosed diabetics for less than 5 years (87.5%) while 5% cases were diagnosed as diabetes for over 10 years. All diabetic cases were operated only after well control of sugar levels, thus no difference was observed among cases and controls with respect to fasting and post-meal blood sugar levels before surgery in our study.

Preoperative diabetic retinopathy evaluation was done by using ETDRS grading system. According to which mild NPDR was found in 5 % and moderate NPDR was found in 5 % of patients. No DR was found in 90% of patients.

Many studies on cataract surgery in diabetics tend to report a lower incidence of complications and better visual outcome.^[16,17] This trend of improvement may be due to better preoperative management of retinopathy, evolutions in operative techniques and appreciation of the importance of systemic factors such as glycemic and hypertensive control.^[18] In our study the BCVA at 1month of follow-up is 6/9-6/6 in 95% of cases and 6/12 and below in 5% of patients. There was no significant deterioration of vision on 6 month follow-up except in one case (2.5%) where vision was deteriorated from 6/12 to 6/36 due to progression of diabetic retinopathy.

Our results are similar to those reported by Zaczek A *et al.*^[19] in their study visual acuity after phacoemulsification was improved in a 88% of the study subjects with few cases of diabetes having vision not improved or less improved as compared to controls.

Sebestyen JG.^[20] has also reported that Diabetic patients with little or no retinopathy enjoy the same good prognosis as individuals without diabetes.

Hashmi FK *et al.*^[21] reported that, 93.3% of the operated eyes had normal vision while 4.4% and 2.2% had moderate (borderline) and poor vision respectively. Pre-existing diseases accounted for 93.9% of the moderate /poor outcome. Mohammad Naeem *et al.*^[22] also showed good vision after cataract surgery in 88.3% and poor vision in 4.7% of patients due to progression of diabetic retinopathy.

Straatsma BR^[23] found no statistically significant difference in operative or postoperative complications in diabetics, with and without non proliferative retinopathy, and non-diabetics in extra capsular cataract extraction with posterior chamber intraocular lens. Postoperative visual acuity of 20/40 or better was obtained in 93% of diabetic eyes and 96% of non-diabetic eyes, a difference that was not statistically significant.

Calvin Sze-un Fong *et al.*^[24] also reported improvement of VA by an average two lines for patients both with and without diabetes.

This shows that if diabetic eye does not have retinopathy, controlled diabetes and surgery is done by an experienced surgeon, the post-operative results are comparable to non-diabetic.

In our study, preoperatively, among 40 diabetic cases, 36 (90%) patients had no DR whereas mild NPDR was seen in 2 cases (5%) and moderate NPDR was seen in 2 cases (5%). Postoperatively, there was a progression of no DR to mild DR in 2 cases (5.55%), mild NPDR to moderate NPDR in one case (50%) and moderate NPDR to severe NPDR in one case (50%) at the end of 6 months. These results were comparable with the study done by Liao and Ku^[25], showed progression of retinopathy among no DR in 12.5% and progression of retinopathy among mild – moderate DR in 57.9% of cases.

In our study, out of total 40 diabetic cases, 4 (10%) showed the diabetic retinopathy at end of 6 months after phacoemulsification cataract surgery. All 4 cases were examined thoroughly for both eyes fundii examination, fundus fluorescein angiography, Blood sugar levels and HbA1c on 6 months of follow-up and compared with baseline blood sugar level. All 4 cases (100%) showed similar retinopathy in fellow eye, deranged blood sugar level and high HbA1c level.

These results were comparable with the study done by Romero *et al.*^[26] on non -proliferative diabetic retinopathy and macular edema progression after phacoemulsification. In their study, diabetic retinopathy among the operated eyes progressed in 31patients (23.48%) and in fellow eye in 28 patients (21.21%). This progression was associated with high levels of HbA1C and diabetes mellitus duration in both groups. Hence they concluded that uneventful phacoemulsification cataract surgery may not hasten DR progression.

Similarly, Squirrel *et al.*^[27] also showed among total 50 diabetic cases, retinopathy progression was observed in 10 operated eyes (20%) and eight fellow eyes (16%). There was

no significant difference in progression of retinopathy ($p=0.63$) in both operated and non operated groups.

CONCLUSION

This prospective hospital based control trial was carried out on total number of 120 patients who were divided into two groups. The case group had 40 diabetic patients and the control group had 80 non-diabetic patients.

The postoperative visual outcome after phacoemulsification in both the groups was in the range of 6/9- 6/6 i.e. in 95% of patients. The intra operative procedure in both the groups was similar and uneventful.

The second aim of our study was to evaluate the progression of diabetic retinopathy in the diabetic group. There was a progression of no DR to mild DR in 2 cases (5.55%), mild NPDR to moderate NPDR in one case (50%) and moderate NPDR to severe NPDR in one case (50%) after 6 months of phacoemulsification in the diabetic group.

All patients with DR underwent cataract surgery only after adequate control of DR. All diabetic patients need close observation for at least 6 months following surgery to intervene as and when required to prevent visual loss from diabetic maculopathy and other consequences of diabetic retinopathy.

Our conclusion after the study was that progression of diabetic retinopathy was not related to the uncomplicated phacoemulsification. As phacoemulsification does not cause significant increase in risk of the DR progression, due to better preoperative management of retinopathy, evolutions in surgical techniques and better glycemic control. Also now-a-days the visualization and monitoring of DR can be done in better way due to advanced equipments.

The progression after uncomplicated phacoemulsification have been reported to be similar to the natural course of DR over time and that may be due to uncontrolled diabetic status and duration of disease.

Thus phacoemulsification in diabetics should be carried out confidently without the fear of progression of diabetic retinopathy, because of better visualization, monitoring and advanced treatment strategies.

References

1. World Health Organisation. Global report on diabetes. Geneva. 2016.
2. International Diabetes Federation. IDF atlas 2015. London. 2015.
3. Kleinbek R, Moss SE. Prevalence of cataracts in a population-based study of persons with diabetes mellitus. *Ophthalmology* 1985;92:1191-6.
4. Nielsen NV, Vinding T. The prevalence of cataract in insulin-dependent and non-insulin-dependent-diabetes mellitus. *Acta Ophthalmol Scand* 1984;62:595-602.
5. Hamilton AMP, Ulbig MW & Polkinghorne P. Epidemiology of diabetic retinopathy. Management of Diabetic Retinopathy. *BMJ* 1996; 1:15.
6. Dowler JG, Hykin PG, Lightman SL, Hamilton AM. Visual acuity following extracapsular cataract extraction in diabetes: a meta-analysis. *Eye* 1995;9:313-7.
7. Schatz H, Aticnza D, McDonald HR, Johnson RN. Severe diabetic retinopathy after cataract surgery. *Am J Ophthalmol* 1994;117:314-21.
8. Pollack A, Lebia H, Bukelman A, Oliver M. Cystoid macular oedema following cataract extraction in patients with diabetes. *Br J Ophthalmol* 1992;76:221-4.
9. Dowler JG, Kulwant SS, Hykin PG, Hamilton PA. The natural history of macular edema after cataract surgery in diabetes. *Ophthalmology* 1999; 106:663-8.
10. Laurell CG, Wickstrom K, Zetterstrom C, Lundgren B. Inflammatory response after endocapsular phacoemulsification or conventional extracapsular lens extraction in the rabbit eye. *Acta Ophthalmol Scand* 1997;75:401-4.
11. Wagner, T., Knaflitz, D., Rauber, M., and Mester, U. Influence of cataract surgery on the diabetic eye (a prospective study). *Ger J Ophthalmol*. 1996; 5: 79-83.
12. Antcliff, R.J., Poulson, A., and Flanagan, D.W. Phacoemulsification in diabetics. *Eye*. 1996; 10: 737-41.
13. Al-Sharkawy HT. Corneal endothelial changes in type 2 diabetes mellitus before and after cataract surgery. *Journal of the Egyptian Ophthalmological Society*. 2015 Apr 1;108(2):79.
14. Pollreisiz A, Schmidt-Erfurth U. Diabetic cataract: Pathogenesis, epidemiology and treatment. *J Ophthalmol* 2010;2010:608751.
15. Li, M. H., Fu, X. L. & Yang, W. F. Effect and risk factors for corneal endothelial cells after phacoemulsification in diabetic cataract patients. *International Eye Science* 2016;16:1048-51.
16. Henricsson M, Heijl A, Janzon L. Diabetic retinopathy before and after cataract surgery. *Br J Ophthalmol* 1996;80:789-93.
17. Javadi MA, Zarei-Ghanavati S. Cataracts in diabetic patients: a review article. *Journal of ophthalmic & vision research*. 2008 Jan;3(1):52.
18. Early Treatment Diabetic Retinopathy Study Research Group. Photocoagulation for diabetic macular edema. Early Treatment Diabetic Retinopathy Study report number 1. *Arch Ophthalmol* 1985;103:1796-806.
19. Zaczek A, Olivestedt G, Zetterström C. Visual outcome after phacoemulsification and IOL implantation in diabetic patients. *British journal of ophthalmology*. 1999 Sep 1;83(9):1036-41.
20. Sebestyen JG. Intraocular lenses and diabetes mellitus. *Am J Ophthalmol* 1986;101:425-28.
21. Hashmi FK, Khan QA, Chaudhry TA, Ahmad K. Visual Outcome of Cataract Surgery. *J Coll Physicians Surg Pak*. 2013;23(6):448-9.
22. Naeem M, Khan A, Khan MZ, Adil M, Abbas SH, Khan MU *et al*. Cataract: trends in surgical procedures and visual outcomes; A study in a tertiary care hospital. *J Pak Med Assoc*. 2012; 62(3): 209-12.
23. Straatsma BR, Pettit TH, Wheeler N, Miyamasu W. Diabetes mellitus and intraocular lens implantation. *Ophthalmology*. 1983;90(4):336-43.
24. Fong CS, Mitchell P, Rochtchina E, Loryn TD, Hong T, Wang JJ. Visual outcomes 12 months after phacoemulsification cataract surgery in patients with diabetes *Acta Ophthalmologica*. 2010;90(2):173-78.

25. Liao S-B, Ku W-C. Progression of diabetic retinopathy after phacoemulsification in diabetic patients: A three-year analysis. *Chang Gung Med J* 2003;26(11):829-34.
26. Romero-Aroca P, Fernández-Ballart J, Almena-García M, Méndez-Marín I, Salvat-Serra M, Buil-Calvo JA. Nonproliferative diabetic retinopathy and macular edema progression after phacoemulsification: Prospective study. *J Cataract Refract Surg* 2006;32:1438-44.
27. Squirrell D, Bhola R, Bush J, *et al*: A prospective, case controlled study of the natural history of diabetic retinopathy and maculopathy after uncomplicated phacoemulsification cataract surgery in patients with type 2 diabetes. *Br J Ophthalmol* 2002;86: 565-71.

How to cite this article:

Onkar Bharatbhushan Chavan *et al* (2018) 'A study of clinical outcome after phacoemulsification cataract surgery in diabetic and non-diabetic patients', *International Journal of Current Advanced Research*, 07(2), pp. 10092-10096.
DOI: <http://dx.doi.org/10.24327/ijcar.2018.10096.1695>
