



SHAPING ABILITY OF PROTAPER GOLD AND WAVE ONE GOLD FILES BY USING CONE-BEAM COMPUTED TOMOGRAPHY

*Shalini Singh¹, Tarun Gupta², Nitin Mirdha³, Jogesh Purohit⁴,
Roshni Arora⁵ and Yesh Sharma⁶

^{1,2,3,4,5}Vyas Dental College and Hospital, Kudi Haud, Pali Road, Jodhpur

⁶Conservative Dentistry and Endodontics, Maharaja Ganga Singh Dental College, Siriganganagar, Rajasthan

ARTICLE INFO

Article History:

Received 9th October, 2017

Received in revised form 10th

November, 2017

Accepted 26th December, 2017

Published online 28th January, 2018

Key words:

Volume of removed dentin, Apical transportation; Centering ratio; cone beam computed tomography; M wire; ProTaper Gold; G-Wire; reciprocating motion; WaveOne Gold.

ABSTRACT

Introduction: M-Wire and rotating motion of ProTaper Gold (PG), G-wire and reciprocating motion of WaveOne Gold (WOG) are the recent innovations using thermal treatment. Therefore, a study was planned to evaluate the shaping ability of ProTaper Gold and WaveOne Gold using cone beam computed tomography (CBCT)

Methodology: Thirty freshly extracted mandibular teeth were selected and stored in saline until use. All teeth were scanned pre and post operatively using CBCT. All teeth were accessed and divided into two groups. (1) Group 1 (PG, n = 15): Instrumented with ProTaper gold (7%/#20). (2) Group 2 (WOG, n = 15): Instrumented with primary file (7%/#20) WaveOne Gold. Sections at 3, 5, and 7 mm were obtained from the pre and post-operative scans. Volume of removed dentin, apical transportation and centering ratio were measured and statistically analyzed.

Results: WaveOne Gold showed lesser apical transportation and volume of removed dentin when compared to ProTaper Gold groups at 3, 5 and 7 mm. WaveOne Gold showed lesser degree of straightening when compared to ProTaper Gold.

Conclusion: This study concluded that WaveOne Gold maintained the original canal anatomy better and did not remove excess dentin while chemomechanical preparation as compared to ProTaper Gold.

Copyright©2018 Shalini Singh et al. This is an open access article distributed under the Creative Commons Attribution License, which permits unrestricted use, distribution, and reproduction in any medium, provided the original work is properly cited.

INTRODUCTION

Chemo-mechanical preparation is one of the most critical procedures in endodontic treatment which influences root canal irrigation and obturation.¹ Nickel-titanium (NiTi) instruments offer numerous advantages to overcome the procedural errors of stainless steel.^{2,3} They are flexible, preserve the original canal shape during preparation, and have a reduced tendency to transport the apical foramen. Despite these advantages, the major troubles of NiTi files are their high cost and unexpected instrument fracture.²

Metal fatigue and fracture are end results of cyclic compression and elongation, which is frequently seen in traditional continuous rotation of files in curved root canals leading the instrument to flex during every rotation.⁴

Recently, biomechanical preparation with reciprocating motion has been postulated to reduce the possibility of unexpected file fractures.

*Corresponding author: Shalini Singh

Vyas Dental College and Hospital, Kudi Haud, Pali Road, Jodhpur

ProTaper Gold (PG) works on rotating motion and is made of NiTi-alloy called M-wire which is considered to feature a progressively tapered design that claimed to improve the cutting efficiency and safety.⁵ WaveOne Gold (WOG) works on principle of reciprocating motion and is claimed to be able to completely shape and clean root canals with only one single use instrument. These files are made of a special NiTi-alloy called G-Wire which is created by an innovative thermal treatment process. The benefits of this G-Wire NiTi are increased flexibility of the instruments and improved resistance to cyclic fatigue.⁶

There is paucity of literature comparing the shaping ability of ProTaper Gold and WaveOne Gold. Therefore, this study was planned. Null hypothesis tested as new manufacturing methods and type of rotary motion will not have any effect on their shaping ability of root canals.

METHODOLOGY

Thirty freshly extracted human mandibular molars having curved canals (25–30°) were selected and cleaned for any debris and stored in saline until use. All teeth were evaluated

radiovisiographically to rule out any calcification. Pre-instrumentation CBCT scanning was done.

Teeth were accessed using an Endo-Access bur (Dentsply Maillefer) in a high-speed handpiece. 10 K size files (Dentsply Maillefer) were inserted through the mesiobuccal canals (MB), and the canal curvature was evaluated according to Schneider's method. Only canals with curvatures of 25–30° were included in this study. The distal roots with the respective part of the crown were sectioned at the furcation level using a low-speed diamond under water and discarded. The determination of the working length was established by inserting size 10 K-file to root canal terminus and subtracting 1 mm from this measurement which was then confirmed using electronic apex locator. The teeth were numbered from 1 to 30 and randomly assigned to two groups (n = 15 each). The "simple method" was chosen and a randomized list of numeric unique identifiers was produced by the software, thus obtaining the following study groups: Group PG and group PU. These teeth were divided into two groups of 15 each after randomization of the sample.

Group 1 (PG, n = 15): Instrumented with ProTaper Gold (Dentsply Maillefer, Ballaigues, Switzerland) in the sequence S1>SX>S1>S2>F1 (7%/#20) as it can be considered as standard control preparation in continuous rotation in pecking motion according to manufacturer's recommendations.

Group 2 (WOG, n = 15): Instrumented with small file (7%/#20) WaveOne Gold (Dentsply Maillefer, Ballaigues, Switzerland) in reciprocating motion.(clockwise-140°, counterclockwise-45°).

Root canal shaping

Root canal procedure was performed by a single operator (Shalini Singh) according to the manufacturers' instructions for each system. The NiTi rotary files were operated using an electric motor (X-Smart plus; Dentsply Maillefer) with a 16:1 reduction handpiece. Glyde (Dentsply Maillefer) was used as a lubricant during instrumentation. A glide path was performed using ProGlider (Dentsply Maillefer; size 16, 0.02 taper) file to the working length. Apical preparation was completed with a size 20 file using the file order specified by the manufacturer. In ProTaper Gold file system, the first three shaping files were used with a brushing action, and the last finishing file was used with a non-brushing action until the working length was reached. During instrumentation, the canals were irrigated with 2 mL 5% NaOCl. After instrumentation, 1 mL of 17% Ethylenediaminetetraacetic acid was applied for 3 min followed by final irrigation with 3 mL of NaOCl. Each instrument was used to prepare three canals and then discarded.

Cone-Beam Computed Tomography analysis

Custom-made specimen holders were used for placement of sectioned tooth in which each root could be positioned in the same place before and after instrumentation. Pre- and post-instrumentation measurements of MB canals were calculated (Figure 1). The volume of removed dentine was measured in mm³ for each root canal by subtracting the un-instrumented canal volume from the instrumented canal volume.⁷ Canal transportation and Centering ratio were calculated at three cross-section levels, i.e., 3, 5, and 7 mm from the apical end of the root using the following equation:

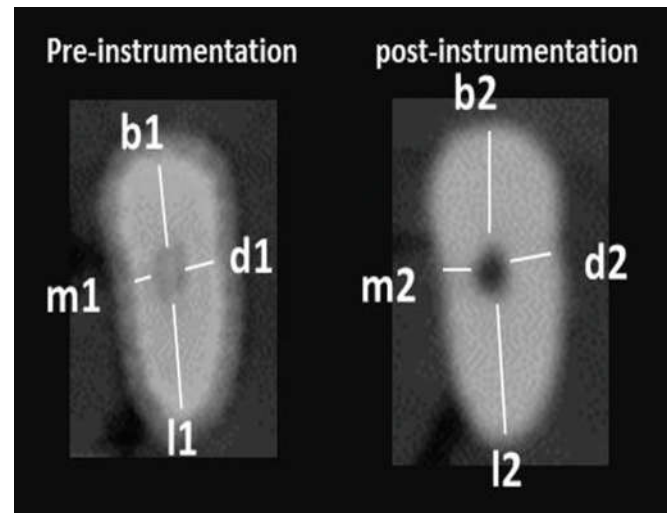


Figure 1 Pre and Post instrumentation Cone-beam computed tomography

Degree of canal transportation: Mesiodistally = $(m_1 - m_2) - (d_1 - d_2)$

Buccolingually = $(l_1 - l_2) - (b_1 - b_2)$

Canal centering ratio = $(m_1 - m_2) / (d_1 - d_2)$ or $(d_1 - d_2) / (m_1 - m_2)$

Statistical analysis

A statistical analysis (SPSS 15.0; SPSS Inc., Chicago, IL, USA) of the data was performed using independent t-test. Statistical significance level was set at $P < 0.05$.

RESULT

Volume of removed dentine

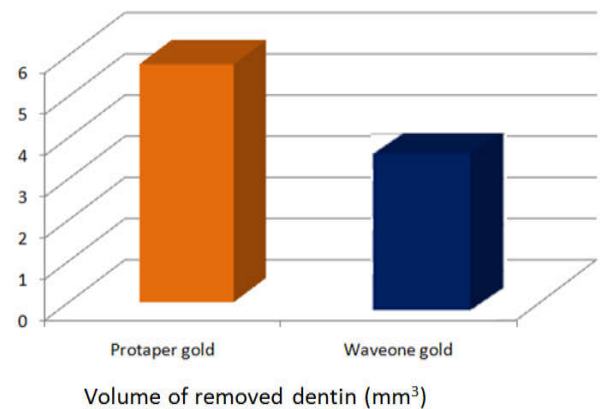


Figure 2 Mean±standard deviation of volume of removed dentine (mm³) for tested groups and statistical analysis

Canal Transportation

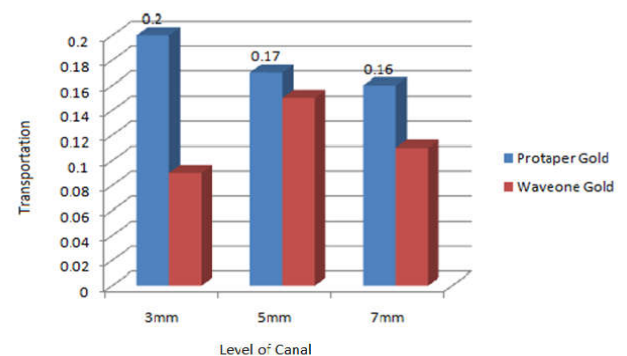


Figure 3 Mesio-distal canal transportation for tested groups.

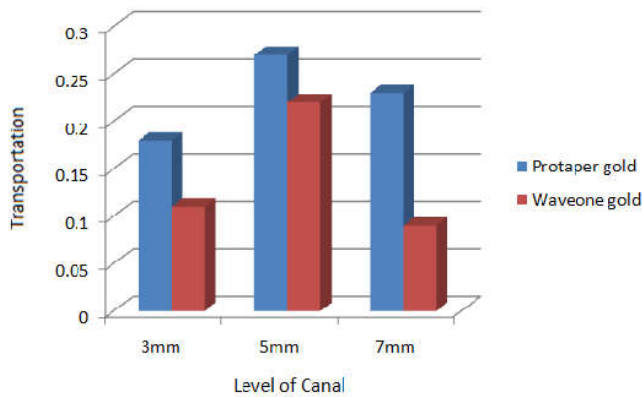


Figure 4 Bucco-lingual canal transportation for tested groups.

Centering Ratio

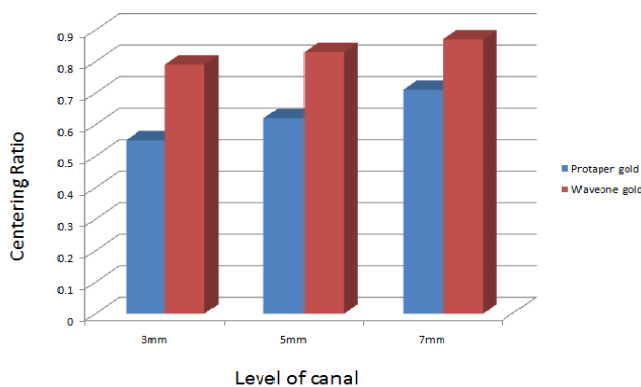


Figure 5 Centering ratio for tested groups

DISCUSSION

The purpose of this study is to compare the shaping ability of two newly introduced NiTi rotary instruments recommended for the preparation of curved root canals, one of which works on principle of reciprocating movement and another by continuous rotary movement.

Crowns corresponding to the mesial roots were retained to mimic the clinical conditions where the tension is produced during canal instrumentation by file, due to interference of cervical dentine projections.⁷

The CBCT imaging technique was used for assessment of shaping ability of the two files as it provides a precise, reproducible, three-dimensional assessment of alterations in dentine thickness and root canal volume before and after preparation without damaging the specimens.⁸

The angle of curvature at 25-30° was preferred as it is considered as moderate curvature according to American Association of Endodontists (AAE) Endodontic Case Difficulty Assessment to obtain results that cover a large scale of cases.⁹

Curvatures with high susceptibility to iatrogenic mishaps usually exist at these three levels: 3, 5, and 7 mm, which represent the apical, middle, and coronal thirds of the root canals, respectively, hence were chosen for evaluation in study.¹⁰

In this study, regarding the volume of removed dentine, PG showed significant difference as compared to WOG (Figure 2). This finding could be attributed to the geometrical and cross-section design of PG and WOG.

In the present study, at 3 mm mesiodistally, the transportation is more with ProTaper Gold than WaveOne Gold, which was statistically significant (Figure 3). Yoo and Cho. reported similar results where WaveOne reciprocating system maintains original canal contour better than files with continuous rotation, which tend to transport the outer canal wall of the curve in the apical part of the canal.¹¹ At all the levels, 3mm, 5mm, 7mm, WaveOne Gold reported to have significant difference in centering ratio as compared to ProTaper Gold (Figure 5). WaveOne showed more centered preparation when compared to ProTaper Gold. Berutti et al. reported that reciprocating movement allows more centralized biomechanical preparation as compared to continuous rotary motion, especially in the apical third.¹² At 7 mm level, buccolingually, there was statistically significant transportation with ProTaper Gold than WaveOne Gold (Figure 4). This could be attributed to the sequence of ProTape Gold files which has progressive tapers sequence along the shaft and are used in circumferential brushing motion, WaveOne Gold has a fixed taper from D1 to D3, a progressively decreasing percentage tapered design from D4 to D16.¹³

Further evaluations of the clinical performance of the tested brands in vivo are needed to give reliable recommendations for endodontists.

CONCLUSION

Within the limitations of this study, it was concluded that WaveOne Gold reciprocation file respected original canal anatomy better than ProTaper Gold continuous file.

Financial support and sponsorship

None.

Conflicts of interest

There are no conflicts of interest.

References

1. You SY, Kim HC, Bae KS, Baek SH, Kum KY, Lee W. 2011. Shaping ability of reciprocating motion in curved root canals: A comparative study with micro-computed tomography. *J. Endod.*, 37: 1296-1300.
2. Yared G. 2008. Canal preparation using only one NiTi rotary instrument: Preliminary observations. *Int. Endod. J.*, 41: 339-44.
3. Yared G. Canal preparation with only one reciprocating instrument without prior hand filing: A new concept. Available from: http://www.vdw-reciproc.de/images/stories/pdf/GY_Artikel_en_WEB.pdf [Last accessed on 2011 Dec 09].
4. Peters OA, Peters CI, Schonenberger K, Barbakow F. 2003. ProTaper rotary root canal preparation: Assessment of torque and force in relation to canal anatomy. *Int. Endod. J.*, 36: 93-9.
5. Amr M E, Shaymaa E E. 2016. Shaping ability of ProTaper Gold and ProTaper Universal files by using cone beam computed tomography. *Ind. Dent. J. Res.*, 27: 37-41.
6. Dentsply Tulsa Dental Specialties. WaveOne Gold. Available at: https://www.dentsply.com/content/dam/dentsply/pim/manufacturer/Endodontics/Obturation/Gutta_Per

- cha_Points/WaveOne_Gold_Gutta_Percha_Points/W1G_Brochure_EN.pdf. Accessed October 14, 2016.
7. Hashem AA, Ghoneim AG, Lutfy RA, Foda MY, Omar GA. 2012. Geometric analysis of root canals prepared by four rotary NiTi shaping systems. *J. Endod.*, 38: 996-1000.
 8. Hartmann MS, Barletta FB, Camargo Fontanella VR, Vanni JR. 2007. Canal transportation after root canal instrumentation: A comparative study with computed tomography. *J. Endod.*, 33: 962-5.
 9. Schneider SW. 1971. A comparison of canal preparations in straight and curved root canals. *Oral. Surg. Oral. Med. Oral. Pathol.*, 32: 271-5.
 10. Michetti J, Maret D, Mallet JP, Diemer F. 2010. Validation of cone beam computed tomography as a tool to explore root canal anatomy. *J. Endod.*, 36: 1187-90.
 11. Yoo YS, Cho YB. 2012. A comparison of the shaping ability of reciprocating NiTi instruments in simulated curved canals. *Restor. Dent. Endod.*, 37: 220-7.
 12. Berutti E, Paolino DS, Chiandussi G, Alovise M, Cantatore G, Castellucci A, et al. 2012. Root canal anatomy preservation of waveOne reciprocating files with or without glide path. *J. Endod.*, 38: 101-4.
 13. Ruddle CJ. 2016. Single-file shaping technique: Achieving a gold medal result. *Dent. Today.*, 35: 98-103.

How to cite this article:

Shalini Singh *et al* (2018) 'Shaping Ability of Protaper Gold and Wave One Gold Files by Using Cone-Beam Computed Tomography', *International Journal of Current Advanced Research*, 07(1), pp. 9436-9439.
DOI: <http://dx.doi.org/10.24327/ijcar.2018.9439.1561>
