

ACCIDENTAL BLAST OF AN IMPROVISED BIRD SCARER GUN: A CASE REPORT

Sandeep Kumar Giri*, Luv Sharma., Vinod Kumar., SK Dhattarwal and Pankaj Keshwani

Department of Forensic Medicine, Pt. B. D. Sharma PGIMS, Rohtak

ARTICLE INFO

Article History:

Received 11th October, 2017

Received in revised form 10th November, 2017

Accepted 26th December, 2017

Published online 28th January, 2018

Key words:

Blast injury, explosive material, improvised gun.

ABSTRACT

Blast injuries are encountered frequently these days in the civilian population due to terrorist activities and unsafe use of explosives. Explosive related deaths fall into three categories, namely; accidental, homicidal and suicidal. Accidental deaths usually occur either at the workplace or when untrained individuals handle legal, unlicensed or illegal fireworks and inflammable explosive materials or substances. In medico-legal practice, forensic medicine experts face chemical explosions more commonly as compared to the mechanical explosions. The authors present a case of accidental blast with classical blast injuries and thermal burns due to explosion during mixing up of explosive materials in an improvised bird scarer gun by a farm caretaker.

Copyright©2018 Sandeep Kumar Giri et al. This is an open access article distributed under the Creative Commons Attribution License, which permits unrestricted use, distribution, and reproduction in any medium, provided the original work is properly cited.

INTRODUCTION

An explosion is the sudden release of previously confined energy and the easily recognisable characteristics of this process are the production of heat, large quantities of gas, and plenty of noise.¹ Explosion may be natural, chemical (bombs), nuclear, electrical (produced by a high current electrical fault) and mechanical (steam boilers burst, air tank burst).² Compression of the air in front of the pressure wave, which heats and accelerates air molecules, leads to sudden increase in atmospheric pressure and temperature transmitted to the surrounding environment as a radially propagating shock wave, known as the Blast wave.³ In medico-legal practice chemical explosions are most common while mechanical are less common.² The present case, is an example of a chemical explosion. The details of this rare incidence with autopsy findings are discussed ahead.

Case report

A 32 years male who was working as a farm caretaker was brought to the Accident and Emergency department of our institute with a history of blast injuries. He had used the mixture of Gandhak and Potash (Sulphur and Potash) in an iron pipe as an improvised gun to produce a sound blast which deters birds, pests, and wildlife animals in an environmentally friendly way. As he was unaware about the hazardous or life threatening effect of this mixture. On the day of the incident, he routinely tried to deter birds and animals from the fields but became the victim of a blast injury due to the

explosion while mixing the sulphur and potash in the iron pipe. In spite of best efforts patient lost his life within four hours of the incident. After that, the dead body of the victim was shifted to the mortuary of Deptt. of Forensic Medicine, PGIMS, Rohtak for the autopsy. The postmortem examination findings are mentioned and depicted below.

Postmortem examination findings

- The dead body was of an averagely built male individual. [Figure-1]
- Surgical bandages were present around the head and left hand, stained with blood at places. [Figure- 1]
- Little finger of left hand was missing. [Figure- 1 and 4]
- Yellowish powdery stains were present over the body at places more so over face and left leg. [Figure- 1]
- Singeing of scalp hair more so over frontal region eyebrows, eyelashes were present. [Figure- 1]

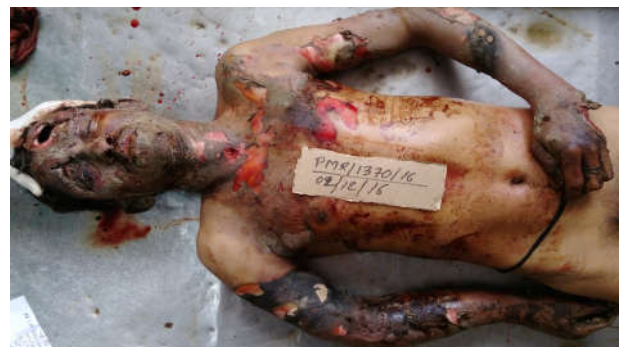

Figure 1 Showing above mentioned findings and burns over the body

*Corresponding author: Sandeep Kumar Giri

Department of Forensic Medicine, Pt. B. D. Sharma PGIMS, Rohtak

Injuries

An irregularly shaped lacerated wound was present over the left side of forehead [Figure-2] along with a visible bony defect over underlying frontal bone over an area of 5 x 2 cm. Margins of the wound and bony defect were irregular and showed infiltration of blood. On dissection, underlying soft tissues were ecchymosed. On further dissection, a linear fracture was found radiating from the posterior margin of the bony defect going posteriorly along the sagittal plane over the left side of frontal bone and left parietal bone. Another linear fracture was radiating from the posterior one third of above described linear fracture in coronal plane over the right parietal bone and crossing the midline upto 2 cm. On further dissection, dura was found to be torn over the left frontal region along with laceration of left frontal lobe and a piece of fracture bone was found to be embedded in the laceration. Subdural haemorrhage was present over the left frontal bone and subarachnoid haemorrhage was present diffusely over both cerebral hemispheres. [Figure-3]



Figure 2 Showing irregularly shaped lacerated wound over the left side of forehead along with a visible bony defect

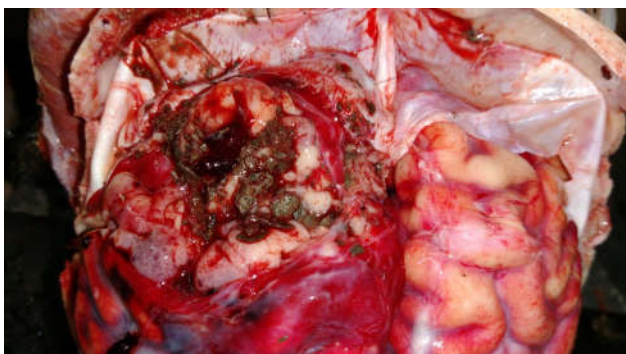


Figure 3 Showing torn dura, laceration of brain, Subarachnoid haemorrhage

A red diffuse contusion was present over the posterolateral aspect of right arm. On dissection, underlying soft tissues and deep muscles were ecchymosed. On further dissection, shaft of right humerus bone was found to be fractured through and through at the junction of upper and middle one third with infiltration of blood in the trabeculae of fractured ends.

A red diffuse contusion was present over the posterolateral aspect of right forearm. On dissection, underlying soft tissues and deep muscles were ecchymosed. On further dissection, shaft of right radius and ulna bones were found to be fractured through and through at the junction of middle and lower one third with infiltration of blood in the trabeculae of fractured ends. Avulsed lacerated wound was present over the palmer surface of right hand. Margins of the wound were irregular and

underlying deep muscles and tendons were lying exposed and ecchymosed.

Traumatic amputation of little finger and 5th metacarpal of left hand was present with irregular and ecchymosed margins of the wound and infiltration of blood in the trabeculae of available fractured portion of 5th metacarpal. On dissection, underlying soft tissues and deep muscles were ecchymosed. [Figure-4]



Figure 4 Showing traumatic amputation of little finger and 5th metacarpal of left hand

Superficial to deep burns were present over the face at places, anterior aspect neck and chest at places, anterior and posterior aspect of both upper limbs at places, anterior and medial aspect of left leg at places. Blackening and peeling of skin of right upper limb along with multiple blisters present over the posterolateral aspect at places. Burnt area corresponded to approximately 20 percent of total body surface area. [Figure-1]

After post-mortem examination, we opined that the cause of death in this case was the injuries described cumulatively due to blast effect and their complications.

DISCUSSION

An explosive material is a reactive substance that contains a great amount of potential energy that can produce an explosion if released suddenly, usually accompanied by the production of light, heat, sound, and pressure. It is of two types: (1) High order explosive: which after detonation produces instantaneous high pressure rapidly expanding gases which compress the surrounding air resulting into supersonic over pressurization shock or blast wave followed by negative pressure (suction) wave which lasts for about 5 times. (2) Low order explosive: which undergo deflagration instead of detonation thereby releasing slow energy as compared to high order explosives resulting in subsonic explosion lacking over-pressurization blast wave; examples are pipe bombs, gunpowder and most pure petroleum-based bombs such as Molotov cocktails.⁴

Injuries produced by the explosion depends on the various factors like surroundings and medium in which it explodes, distance from the incidence, pressure wave and its duration, and amount and composition of the explosive material. Depending on the distance from the blast centre, they are categories in the four patterns; primary, secondary, tertiary and quaternary.

Primary injuries caused by direct pressure effects of the blast wave which may affect the air containing organs like ear, lungs and gastrointestinal tracts. Secondary injuries caused by flying missiles (nuts, bolts, nails etc.) generated by the explosion. Secondary injuries usually show Marshal Triad i.e.

punctate lacerations, abrasions and bruise. Tertiary injuries produce when the victim is actually lifted up and thrown around by the blast wind, or when some heavy piece of masonry breaks and falls upon the victim causes fractures and traumatic amputation. Quaternary injuries resulting from inhalation of dust and toxic gases, exposure to radiation, thermal burns, and so on.⁴

Both sulphur and potash are used as fertilizers in the farm. Potash is any of various mined and manufactured salts that contain potassium in water-soluble form. Among the various chemical compounds of potash, only potassium nitrate has the explosive property and is used as fertilizer too.⁵

The mixture used by the farm caretakers i.e. sulphur and potash (potassium nitrate) is very similar to the mixture of black gunpowder which contains potassium nitrate (75%), charcoal (15%) and sulphur (10%) which has the explosive property in which potassium nitrate act as an oxidiser whereas sulphur and charcoal act as fuel.⁶

In this case, sulphur and potash used by the farm caretaker to produced sound blast which deters birds, pests and wildlife animals in an environmentally friendly way. The amount of the mixture used by him was of sufficient in amount to produce life threatening injuries due to blast. Due to his unawareness or carelessness about the used mixture, he became the victim of a blast injury.

The above-discussed case is an example of chemical explosion and a blast of low order explosive. The body of the victim bore approximately all patterns of injuries because he was very close to the centre of the blast.

CONCLUSION

The authors have attempted to provide further insight into blast injuries, which are rare events. Physicians and surgeons need to have a basic understanding of the pathophysiology of such injuries because the major prognostic factor for the favourable outcome is accessible and timely medical and surgical treatment along with implementations of preventable occupational measures for safety. Forensic experts also have to perform a complete and meticulous autopsy to reach the conclusion of a blast injury cases especially the cases in which no eyewitness was present.

Conflict of interest: None

References

1. Mathiharan K, Patnaik AK, editors. *Modi's Medical Jurisprudence and Toxicology*. 23rd ed. New Delhi: Lexis Nexis. 2006. p. 547.
2. Aggrawal A. *Textbook of Forensic Medicine and Toxicology*. 1st ed. Himachal Pradesh: Avichal Publishing Company. 2014. P.312.
3. Tsokos M, Paulsen F, Petri S, Madea B, Puschel K, Turk EE. Histologic, immunohistochemical and ultra-structural findings in human blast lung injury. *Am J Respir. Crit. Care Med*. 2003; 168:549-55.
4. Department of Health and Human Services, USA. CDC Injury prevention. Explosion and blast injuries, A primer for clinicians. Availbale from <https://www.cdc.gov/masstrauma/preparedness/primer.pdf>.
5. Kostick D. "Potash" *Minerals Handbook*. United States Geological Survey. 2011:58.
6. Reddy KSN, Murty OP. *The essentials of Forensic Medicine and Toxicology*. 33rd ed. New Delhi: Jaypee Brothers Medical Publishers. 2017. p. 214.

How to cite this article:

Sandeep Kumar Giri *et al* (2018) 'Accidental Blast of an Improvised Bird Scarer Gun: A Case Report', *International Journal of Current Advanced Research*, 07(1), pp. 9212-9214. DOI: <http://dx.doi.org/10.24327/ijcar.2018.9214.1513>
