



## VISUAL OUTCOME OF IRIS CLAW LENS IN APHAKIA IN THE ABSENCE OF ADEQUATE CAPSULAR SUPPORT

Christine Susan Roy<sup>1\*</sup> and Loganathan M<sup>2</sup>

<sup>1</sup>MS Ophthalmology, Sri Venkateshwaraa Medical College Hospital and Research Centre, Pondicherry, India

<sup>2</sup>Department of Ophthalmology, Sri Venkateshwaraa Medical College Hospital and Research Centre, Pondicherry, India

### ARTICLE INFO

#### Article History:

Received 15<sup>th</sup> September, 2017

Received in revised form 25<sup>th</sup>

October, 2017

Accepted 23<sup>rd</sup> November, 2017

Published online 28<sup>th</sup> December, 2017

#### Key words:

Aphakia, Best corrected visual acuity, Iris claw lens, visual outcome, lens stability

### ABSTRACT

**Aim:** To analyse the visual outcome, efficacy and stability of secondary iris claw lens implantation in aphakic eyes. **Material And Methods:** Prospective, descriptive study. 30 aphakic eyes with inadequate capsular support were evaluated and taken up for secondary iris claw lens implantation after obtaining ethical clearance approval. Written informed consent was obtained from the participants of the study. Patients with significant anterior and posterior segment pathologies were excluded from the study. A detailed examination was done including torch light examination, Best Corrected Visual Acuity assessed with +10 Diopters and pin hole, slit lamp biomicroscopy, indirect ophthalmoscopy and Goldmann Applanation Tonometry. Standard Iris claw lens was implanted following anterior vitrectomy. Post operatively, topical antibiotics and steroids were given in tapering doses for 6 weeks. Patients were followed up 6 months to evaluate the visual outcome and stability of iris claw lens. **Results:** All patients were in the age group of 45-80 years. 16 patients had aphakia in the right eye and 14 patients had aphakia in the left eye. Preoperatively, 20 patients (66%) had a vision of less than 6/18. Postoperatively 23 patients(76%) out of 30 aphakic patients obtained a vision of more than 6/12 and 7 patients(23%) obtained a vision of 6/24 to 6/18. 1 patient had decentration of the lens which was corrected with repositioning. **Conclusion:** Iris claw lens is safe and effective with a low complication rate to correct aphakia.

Copyright©2017 Christine Susan Roy and Loganathan M. This is an open access article distributed under the Creative Commons Attribution License, which permits unrestricted use, distribution, and reproduction in any medium, provided the original work is properly cited.

### INTRODUCTION

In aphakia, the crystalline lens is absent from its normal anatomical location in the patellar fossa due to congenital or acquired causes. Aphakia is more commonly due to acquired conditions, of which failure to implant an Intraocular Lens (IOL) following surgical removal of the cataractous lens is the commonest cause. Unaided visual acuity in aphakia is grossly reduced and patient is literally blind. Various options available to improve the vision include spectacles, contact lens, refractive surgery and secondary IOL implantation. Reduced peripheral vision, Jack in the box phenomenon, magnification of image up to 30%, spherical and chromatic aberrations are problems encountered with spectacle correction.<sup>1</sup> In unilateral aphakia spectacle correction also causes diplopia. Contact lens is useful in unilateral aphakia in young patients but it has its own limitations like allergy and infections and maintenance of adequate hygiene related to it.

The types of IOL available to correct aphakia are Posterior chamber, Sulcus fixated, Iris fixated, Scleral fixated and Anterior chamber IOL.

Following cataract surgery, Posterior chamber IOL (PCIOL) implantation remains the gold standard till date. In case of insufficient capsular support due to trauma or surgical complications, sulcus fixated, iris fixated, scleral fixated and anterior chamber IOL are to be considered to correct aphakia.<sup>2</sup> The advantages of IOL implantation in aphakic eyes are binocularity, spectacle independence, wider range of visual field and no magnification.

Sulcus fixated IOL is associated with cyclitis, iris atrophy, iris pigment dispersion and pupillary block. Whereas scleral fixated IOL is associated with sutural erosion, IOL tilting or decentration, vitreous prolapse and is more technically demanding.<sup>2,3</sup> Anterior chamber IOL (ACIOL) is associated with Uveitis-Glaucoma-Hyphaema (UGH) syndrome, corneal decompensation and cystoid macular edema. Iris fixated IOL can be anterior or posterior fixation. When iris tissue is available, posterior iris fixated IOL implantation is one of the ideal procedures of choice to treat aphakia. Since it is fixed to

\*Corresponding author: Christine Susan Roy

MS Ophthalmology, Sri Venkateshwaraa Medical College Hospital and Research Centre, Pondicherry, India

the mid-periphery of the iris, problems associated with IOL sizing, damage to the anterior chamber angle and the iris root are avoided. Also, iris-claw IOL does not cause significant pupillary distortion or interfere with the iris physiological vascularisation.<sup>4,5</sup> and has the advantage of posterior chamber location and absence of complications related with ACIOL and scleral fixated IOL. Iris-claw lens can also be implanted in patients with coloboma or partial loss of iris tissue following trauma. So far only few prospective studies are available about retropupillary fixation of iris-claw lens especially in Indian eyes.

**MATERIALS AND METHODS**

This study was conducted between November 2015 and May 2017. This is a prospective, descriptive study of 30 aphakic eyes in the age group of 45-80 years. Patients with aphakia with inadequate capsular support were included in the study. Patients with raised intraocular pressure, corneal decompensation, rubeosis iridis, significant posterior segment pathology, uveitis, aniridia, significant iris atrophy and paediatric aphakia were excluded from the study.

Preoperatively all the 30 patients underwent a complete and detailed ophthalmic examination. This included

1. initial torch light examination,
2. visual acuity with a Snellen’s chart and Best Corrected Visual Acuity (BCVA) using +10 Diopters and pin hole.
3. Keratometry and A scan using 117.0 as A constant and SRK/T formula was done to calculate the power of the IOL.
4. Slit lamp biomicroscopy for anterior segment evaluation was done. Pupil. iridodonesis and the position of peripheral iridectomy if present were also noted.
5. Retinal evaluation was done with +90 D and Indirect ophthalmoscopy.
6. Intraocular pressure was measured using Goldmann Applanation Tonometry.

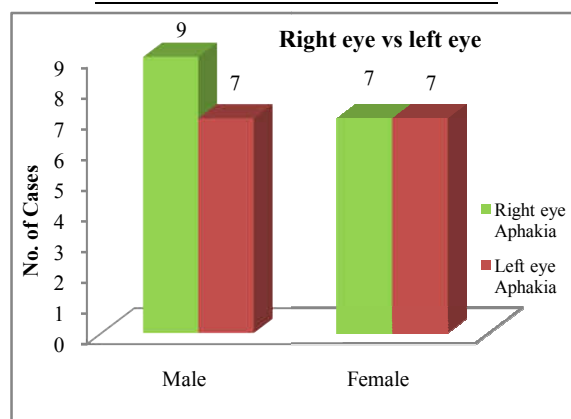
Two sideport incisions 180- degree apart were made. The anterior chamber was filled with a cohesive viscoelastic so that it could be easily removed later. This reduced the chance of raised IOP. A 5-6 mm point was marked on the cornea depending on the size of the IOL. A fornix based conjunctival flap was made. Hemostasis was achieved by cauterization of the bleeding vessels. A partial thickness inverted smile incision was made on the sclera with convexity around 0.5mm away from the limbus. Then a scleral tunnel was made and entry of around 1.5mm into the corneal tissue was made. Using a 3mm keratome, the anterior chamber is entered and enlarged so as to implant a 5mm IOL. Anterior vitrectomy was done if any vitreous strand was present in the anterior chamber and pupillary area. Iris claw lens was placed in the posterior chamber and enclaved to the iris. Post operatively, patients were given antibiotics and steroid eyedrops in tapering dose for 6 weeks. They were also given Non-Steroidal Anti-Inflammatory drugs for 6 weeks, as a prophylaxis against cystoid macular edema. Patients were followed up for 6 months that is on the 1<sup>st</sup> day, 1<sup>st</sup> week, 1<sup>st</sup> month, 3<sup>rd</sup> month and 6<sup>th</sup> month postoperatively and evaluated for BCVA, uveitis, CME, pigment dispersion, IOL stability (decentration and displacement).

**RESULTS**

This study was done on 30 aphakic eyes. Institutional ethical committee approval was obtained prior to the study. Written informed consent was obtained from all the participants of the study. Data was entered in MS Excel sheet and assessed. SPSS software was used. Student’s t test and Chi square test were used for statistical analysis (p value <0.002). The age of the patients ranged from 45-80 years. Out of 30 aphakic patients, 9 patients belonged to the age group of 66-70 years of which 5 were male and 4 were female patients.

**Table 1** Age group and gender of patients with aphakia

Age Group	Male	Female	Total
45 – 50	1	3	4
51 – 55	1	2	3
56 – 60	1	1	2
61 – 65	2	2	4
66 – 70	4	5	9
71 – 75	4	1	5
76 – 80	3	0	3
Total	16	14	30



**Figure 1** Right eye aphakia versus left eye aphakia

**Table 2** Preoperative slit lamp examination

Preoperative Slit lamp examination	No.
Normal	2
Iridodonesis	13
Floating Vitreous strands	10
PI at 1 o’clock position	3
Pseudoexfoliation	1

A total of 16 patients had Aphakia in the right eye and 14 patients had Aphakia in the left eye. Pre operatively , 12 patients(40%) had vision in the range of 6/18 to 6/9, 10 (33.33%) had vision in the range of 6/36 to 6/24 and 8 (26.66%) patients had a poorer vision of PL (+) to 6/60. Slit lamp findings showed iridodonesis in 13 patients (43.33%). 10 patients (33.33%) had floating vitreous strands. 3 patients (10%) had a PI done at 1 o’clock position and 1 patient had pseudoexfoliation. The fundus examination was normal in 83% of the patients. Floating vitreous strands were present in 10% patients and peripapillary atrophy in 7% of the patients. The best corrected visual acuity (BCVA) improved after the implantation of iris claw lens. 23 patients (76.66%) had a BCVA more than 6/12, 6 months post operatively. Ovalisation of pupil was seen in 8 patients. Decentered iris claw lens was seen in one patient.

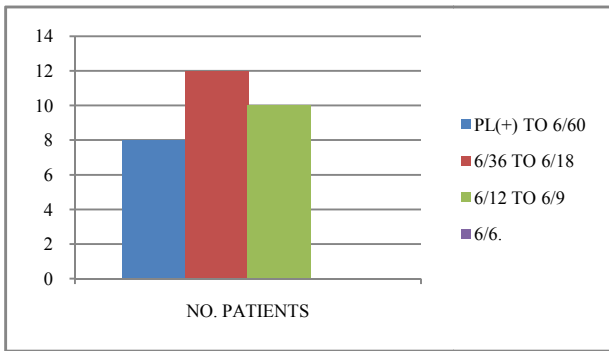


Figure 2 Preoperative best corrected visual acuity

Table 3 Posterior segment findings with +90 D lens and Indirect Ophthalmoscopy

Posterior segment	No.
Normal	25
Peripapillary Atrophy	2
Floating Vitreous and Strands	3

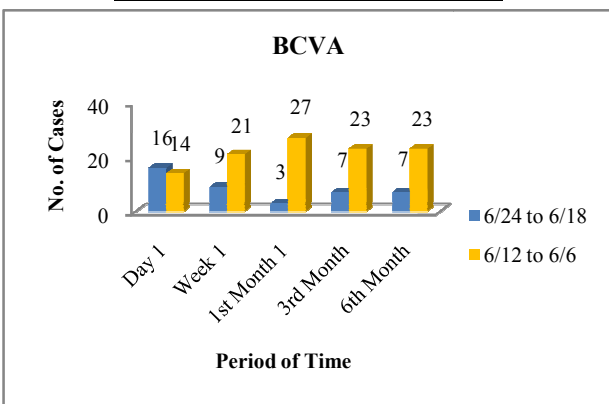


Figure 3 Post operative best corrected visual acuity (BCVA)

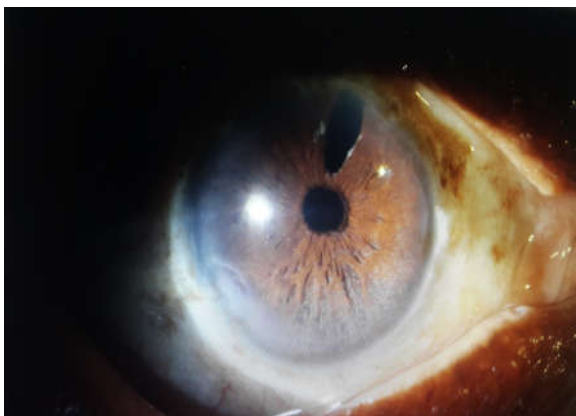


Figure 4 Preoperative slit lamp photograph of an aphakic eye

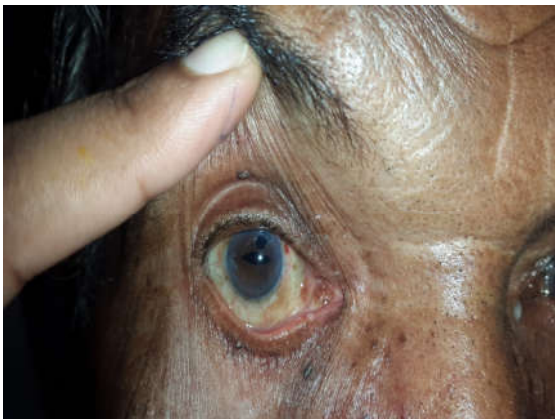

Figure 5 Preoperative clinical photograph of an aphakic eye

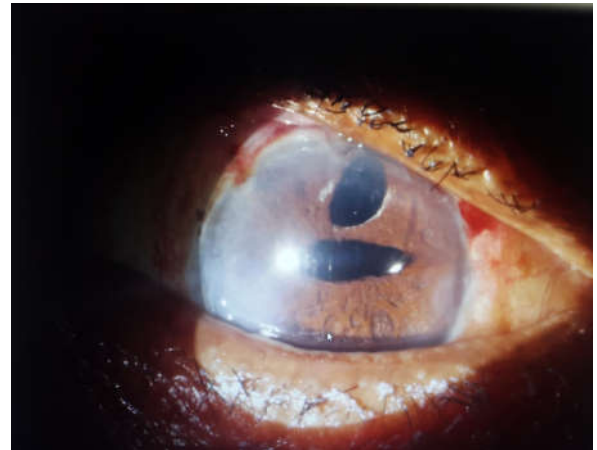

Figure 6 Postoperative photograph following iris-claw IOL implantation

## DISCUSSION

Secondary IOL implantation is a viable option in correcting aphakia with inadequate capsular support. It overcomes the problems encountered with spectacles and contact lenses. Among the various types of IOLs that can be used for implantation in aphakic patients, various studies have reported that iris-claw lens implantation is better to correct aphakia when there is inadequate capsular support. It is an effective procedure when iris support is feasible. Since it is fixed to the mid periphery, problems with IOL sizing, damage to the anterior chamber angle and the iris root are avoided.<sup>6,7</sup> In this prospective study, 30 aphakic eyes with inadequate capsular support underwent secondary iris-claw IOL implantation surgery. All cases underwent primary cataract surgery without PCIOL implantation. 53.33% patients had aphakia in the right eye and 46.66% patients had aphakia in the left eye. There were 16 (53.33%) male and 14 (46.66%) female patients. The mean age of the patients was 62.16 years and most patients (46.33%) belonged to the age group of 61-70 years. Right eye aphakia (56%) were more common than left eye aphakia (44%).

In a study conducted by Raghavendra Rao *et al* on 30 eyes with monocular aphakia due to complicated cataract surgery, the mean age was found to be  $57 \pm 10$  years and 50% of the patients belonged to the age group of 60-70 years. The number of males and females were equal.<sup>8</sup>

In a study by Sezar Helvacı *et al*, on iris-claw lens implantation in aphakic eyes, males (55%) were more common than females (45%). The mean age of the patients was  $69.2 \pm 7.4$  years. Right eye aphakia (55%) were more common than left eye aphakia (45%).<sup>9</sup>

In a study conducted by Maurice Schallenberg *et al*, on the long term results of aphakic correction with retropupillary fixated iris claw lens implantation (RPICL) on 31 aphakic eyes, the mean age was 72.66 years of which there were 20 males and 11 females.

53.33% patients had aphakia in the right eye and 46.66% patients had aphakia in the left eye in this study which was not very significant statistically.

Preoperative unaided visual acuity ranged from perception of light to 6/24 in most of the patients 18 patients (60%).

Preoperatively, the vision with +10 D was in the range of perception of light to 6/60 in 8 patients (26.66%), 6/36 to 6/18

in 12 patients (40%) and 6/12 to 6/9 in 10 patients (33.33%). Slit lamp findings showed iridodonesis in most of the patients (14 patients). 10 patients had floating vitreous strands. 3 patients had a PI done at 1 o'clock position and 1 patient had pseudoexfoliation. The fundus examination was normal in 83% of the patients. Floating vitreous strands were present in 10% patients and peripapillary atrophy in 7% of the patients. The best corrected visual acuity at the end of 6 months, after the implantation of iris claw lens was more than 6/12 (0.301 logMAR units) in 23 patients out of 30 patients.

This was similar to the study conducted by MunYueh Faria on 66 aphakic eyes in a 4 year period where the postoperative best corrected visual acuity (BCVA) was  $0.352 \pm 0.400$  logMAR units in all the patients.<sup>10</sup>

Patients were followed up for 6 months that is 1<sup>st</sup> week, 1<sup>st</sup> month, 3<sup>rd</sup> month and 6<sup>th</sup> month postoperatively. The main parameters checked on follow up were BCVA, stability of the lens, presence of uveitis, cystoid macular edema, and intraocular pressure. In this study, ovalisation of pupil was seen in 8 patients. This did not affect the visual outcome, hence it was not a significant complication. Decentration of the iris-claw lens was seen in 1 patient and it was managed by repositioning it. No other significant complications were seen.

We used a retropupillary iris claw intraocular lens due to its posterior chamber location.

In a study conducted by Matteo Folini *et al*, on the long term follow up of retropupillary iris-claw IOL implantation, 5% of the patients developed ovalisation of the pupil and 0.02 % patients developed a rise in Intraocular Pressure (IOP) which was managed medically. They concluded that the complications with RPICIOL were less as compared with its benefits.<sup>11</sup>

In a study conducted by KS Lett and PR Chaudhuri, it was suggested that in cases of acquired aphakia, iris-claw lens implantation is beneficial. It was a retrospective study of 32 aphakic eyes. Complicated phacoemulsification was the commonest cause for aphakia. Following iris-claw lens implantation, BCVA improved significantly in 65.6% of the eyes.<sup>12</sup> Retropupillary iris claw lens implantation has the advantages of a posterior chamber IOL due to its position and low intraoperative and postoperative complications. Also, the implantation process is technically simple.

## CONCLUSION

Secondary iris claw intraocular lens is an effective option to treat aphakia in the absence of adequate capsular support. It has lesser complication rates and a better visual outcome as compared to the other types of intraocular lenses.

## References

1. A K Khurana. Theory & Practice of Optics and Refraction, 3<sup>rd</sup> ed. Elsevier; 2014. p. 65-69.
2. A.J. Elkington, H.J. Frank and M.J. Greany. Clinical Optics, 3<sup>rd</sup> ed. Blackwell Science; 1999. p. 124-133.
3. David Abrams. Duke-Elder's Practice of Refraction, 10<sup>th</sup> ed. Elsevier; 2006. p. 71-72.
4. William. J. Benjamin. Borisch's Clinical Refraction, 2<sup>nd</sup> ed. Elsevier; 2006. p. 1087-1088.
5. Ashok Garg and JT Lin. Mastering Intraocular Lenses [IOLs] principles, Techniques and Innovations. 1<sup>st</sup> ed. Jaypee; 2007. p. 3-8.
6. Fereydoun F, Mostafa F, Foad H, Ali K *et al*. Iris Claw versus Scleral Fixation Intraocular Lens Implantation during Pars Plana Vitrectomy. *J Ophthalmic Vis Res.* 2012;7(2):118-124
7. Ashwini R, Narendra P. Comparison of iris-claw lens and sclera fixated intraocular lens in terms of visual outcome and complications. *J Clin Biomed Sci.* 2014;4(4):357-60
8. Raghavendra R, Ajita S. Iris claw intraocular lens: A viable option in monocular surgical aphakia. *Indian J Ophthalmol.* 2011;61(2):74-75
9. SezarHelvacı, Selahaddin Demirduzen, Huseyin Oksuz. Iris-claw intraocular lens implantation: Anterior chamber versus retropupillary implantation. *Ind J Ophthalmol.* 2016 Nov;64:45-48.
10. MunYuehFaria, Uno Pinto Ferreira, Joana Medeiros Pinto, David Cordeiro Sousa. Retropupillary iris claw intraocular lens implantation in aphakia for dislocated intraocular lens. *International Medical Case Reports Journal.* 2016;9:261-265.
11. Sri Ganesh, SheetalBrar and Kirti Relekar. Long Term Clinical and Visual Outcomes of Retrofixated Iris Claw Lenses Implantation in Complicated Cases. *The Open Ophthalmology Journal.* 2016; 10:111-118.
12. KS Lett, PR Chaudhuri. Visual outcomes following Artisan aphakia iris claw lens implantation. *Eye.* 2011;25:73-76

### How to cite this article:

Christine Susan Roy and Loganathan M (2017) 'Visual Outcome of Iris Claw Lens in Aphakia in the Absence of Adequate Capsular Support', *International Journal of Current Advanced Research*, 06(12), pp. 8123-8126.  
DOI: <http://dx.doi.org/10.24327/ijcar.2017.8126.1293>

\*\*\*\*\*