



REVASCULARIZATION OF A NON-VITAL IMMATURE PERMANENT CENTRAL INCISOR- A CASE REPORT

Rajas Prasad*, Shivaprakash P.K and Mahantesha T

Department of Pediatric and Preventive Dentistry, P.M.N.M Dental College and Hospital, Bagalkot, Karnataka

ARTICLE INFO

Article History:

Received 15th September, 2017

Received in revised form 25th

October, 2017

Accepted 23rd November, 2017

Published online 28th December, 2017

Key words:

Revascularization, Biodentine, Immature permanent incisor

ABSTRACT

A 9 – year- old female patient was referred with a chief complaint of pain with the maxillary central incisors. clinical and radiographic examination revealed a negative response to vitality and percussion tests with immature root and open apices. After disinfection of the canal, bleeding was induced in the canal up to the cemento-enamel junction (CEJ). The blood was allowed to clot for 5 minutes and a Biodentine plug was placed over the clot, 3-4 mm below the CEJ and a temporary glass ionomer cement restoration was placed which was later replaced by a permanent composite resin restoration. Clinical and radiographic findings over a 6 month follow-up showed complete root maturation and intact supporting soft tissues without sinus tract , pain or swelling.

Copyright©2017 Rajas Prasad et al. This is an open access article distributed under the Creative Commons Attribution License, which permits unrestricted use, distribution, and reproduction in any medium, provided the original work is properly cited.

INTRODUCTION

Traumatic injuries to young permanent teeth majorly occur before completion of root formation.¹ The most frequently affected teeth are the central and lateral maxillary incisors, which are aesthetically located, with a 20-30% prevalence in young patients.² Around half of these traumatized teeth may result in necrosis of the pulp, but only 8.5% of them exhibit signs and symptoms of disease.³ The total destruction of Hertwig's epithelial root sheath will result in the arrest of normal root development leading to divergent dentinal walls and absence of the apical stop, which poses clinical challenges for conventional root canal treatment.

Regenerative endodontic procedures (REP) were adduced to overcome the disadvantages of the clinical management of necrotic immature permanent teeth (NIPT)⁴ and are currently gaining popularity over traditional apexification procedures. They are 'biologically based procedures designed to replace damaged structures, including dentine and root structures, as well as cells of the pulp-dentine complex'.⁵ presently, the term revascularization is broadly used in the current literature, but its use is in dispute. Initially, this term was suggested by Trope because the nature of the tissue that formed after the treatment within the root canals was unpredictable, and the only certainty was the presence of a blood supply.⁶

Iwaya *et al.* (2001)⁴ and Banks and Trope (2004)⁷ were the pioneers in publishing a REP case report on a necrotic mandibular central incisor and on a necrotic immature

permanent mandibular second premolar respectively. According to their reports, after invoking intracanal bleeding, the blood clots were covered with calcium hydroxide and MTA respectively. The findings of both studies showed a thickening of the root canal walls and continued root development.^{4,7}

To date, MTA has been the material of choice for REP procedures due to the survivability of undifferentiated dental pulp stem cells (DPSC) after their exposure to MTA, which has the capacity to form new hard tissues. In addition to its ease of displacement during condensation, it has other disadvantages, like long setting time, difficult handling and potential tooth discoloration.¹⁴ Because anterior teeth are more susceptible to trauma, it is important for aesthetic reasons to use materials that do not cause tooth discoloration after REP. To avoid these shortcomings, many different materials have been developed, like Biodentine (Septodont, Saint Maurdes-Fosses, France), which is a calcium-silicate material that sets in approximately 12 min, does not wash out easily, is simple to handle and does not cause discoloration.¹⁴

CASE REPORT

A 9-year-old female patient came to the Department of Pedodontics, P.M.N.M Dental College and hospital, Bagalkot, with the complaint of pain in the upper front tooth region. The patient was medically fit. The past dental history revealed that the patient had a fall while riding a bicycle 4 months back. The teeth were not tender to percussion and did not respond to vitality tests.

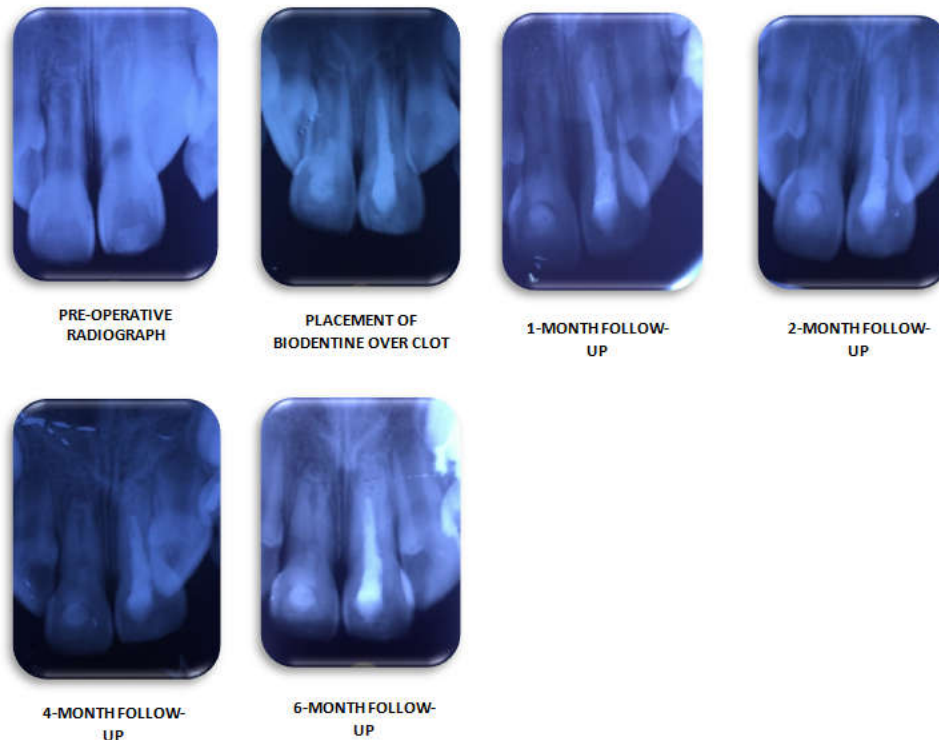
The pre-operative intra-oral periapical radiograph revealed immature left and right upper central incisors with a wide open

*Corresponding author: **Rajas Prasad**

Department of Pediatric and Preventive Dentistry,
P.M.N.M Dental College and Hospital, Bagalkot, Karnataka

apex. On the basis of clinical and radiographic findings, the teeth were diagnosed to have chronic irreversible pulpitis. After weighing all the options, pulp revascularisation with Biodentine was decided upon.

The clinical follow up at 2, 4 and 6 months showed an adequate clinical function, complete root maturation, intact supporting soft tissues and absence of clinical symptoms. The tooth was later sealed with a composite resin.



The patient and the parent were explained about the procedure thoroughly and an informed consent was obtained. On approval of the treatment plan, the root canal treatment was initiated.

Local anaesthesia was administered followed by the placement of the rubber dam. An access cavity was prepared. The canal was irrigated with 5.25% NaOCl solution and Saline in the first appointment. The working length was determined radiographically. The canal was gently dried using sterile paper points and triple antibiotic paste (TAP) was placed in the canal to disinfect it. The access cavity was temporized with temporary filling material (Cavit; 3M/ESPE, Seefeld, Germany). The patient was recalled after two weeks.

In the second appointment, the canal was irrigated using 17% ethyldiaminetetraacetic acid (EDTA) to remove smear layer and Chlorhexidine solution and saline to flush out the TAP without damaging the stem cells present in the periapical region. Then the canal was dried using sterile paper points. A #20 K-file (DentsplyMaillefer, Ballaigues, Switzerland) was then used to irritate the periapical tissues and induce bleeding into the canal upto the CEJ level and allowed to clot for 5 minutes. The bleeding could be induced only in the maxillary right central incisor and hence, revascularization was carried out only in this tooth. Apexification using Biodentine (BD, Septodont, Saint maur des Fossses, France) followed by obturation was done in the maxillary left central incisor.

A mixture of Biodentine was placed over the blood clot in the maxillary right central incisor using endodontic pluggers 3-4 mm below the level of the CEJ. After 30 minutes, a light-cure glass ionomer cement restoration (GC FUJI II LC, GC Corp, Tokyo, Japan) was placed over the access cavity and the patient was scheduled for a follow up.

DISCUSSION

Root canal maturogenesis is based on inducing a blood clot in the canal space by mechanically irritating the periapical tissues, which promotes mesenchymal stem cells within the root canal, which differentiate in order to stimulate root development.⁹ Regardless of the type of tissue growth, REP promotes greater root development than conventional apexification methods do.¹⁵

All regenerative endodontic procedures stem from the research published by Nygaard - Ostby, which revealed that vasculature could be established to support new tissue growth in the empty root canal through the formation of a blood clot in the pulp space.⁸ According to this principle, the periapical area is deliberately damaged to induce bleeding and a fibrin clot, which begins healing after tissue injury. Fibrin, a biopolymer secreted to promote haemostasis and wound healing, is responsible for blood clot formation and stabilization, which serves as a scaffold for stem cells deriving from apical papilla (SCAP).^{9, 10}

SCAP provides a source of primary odontoblasts that promotes the continued root development and, as a result of proximity to the periodontal blood supply, can survive pulp necrosis even in the presence of periradicular infection.¹⁰

Although there are no evidence-based guidelines to support a standard protocol to achieve the most favourable outcome in REP, many regenerative endodontic treatment protocols have been proposed depending on the type of the irrigant; the irrigation method; the intracanal dressing; the type of scaffold; and the blood clot-protecting material. Mechanical instrumentation of the root canal is contra-indicated due to the thin walls of teeth, which could further increase the risk of root

fracture.¹¹ Therefore, disinfection of the root canal system depends solely on the irrigant's effectiveness. The most popularly used disinfection irrigant is sodium hypochlorite (NaOCl), in different concentrations, including 6%, 5.25%, 2.5%, 1.25% and 0.5%.¹² Also, ethylenediaminetetraacetic acid (EDTA) has proved to promote the release of growth factors embedded in dentine that help in both the regenerative processes as well as stem cell proliferation, migration, and differentiation.¹³

The sealing properties and excellent biocompatibility of MTA makes it the material of choice for clot protection.¹⁶ Biodentine is a relatively new calcium silicate cement promoted as a dentine substitute that can be used for all MTA indications. Its advantages include: no tooth discoloration, easy handling, fast setting time and promotion of bone regeneration, as confirmed by recent cell culture studies.¹⁴

Predictors of a clinically successful REP include lack of signs and symptoms of disease, such as pain, swelling, sinus tract, radiographic evidence of periapical healing, as well as increased root length and canal wall thickness, indicative of continued root development, and many authors include positive response to sensitivity testing.¹⁷ Unhealed periapical lesions (sinus tract or swelling recurrence, root resorption and larger or unchanged periapical lesion), fractures, and failure to induce periapical bleeding are the main causes associated with failures after RET.¹⁸

CONCLUSION

The present case confirms that Biodentine can be considered as a very effective material to support REP in immature teeth that have undergone trauma and aid in root maturogenesis. The 6-month follow up showed adequate clinical function, complete root maturation, intact supporting soft tissues and absence of clinical symptoms.

References

1. Andreasen JO, Ravn JJ. Epidemiology of traumatic dental injuries to primary and permanent teeth in a Danish population sample. *Int J Oral Surg* 1972;1(5):235-9.
2. Andersson L. Epidemiology of traumatic dental injuries. *Pediatr Dent* 2013; 35(2):102-5.
3. Robertson A, Andreasen FM, Bergenholtz G, Andreasen JO, Nore'n JG. Incidence of pulp necrosis subsequent to pulp canal obliteration from trauma of permanent incisors. *J Endod* 1996; 22(10):557-60.
4. Iwaya SI, Ikawa M, Kubota M. Revascularization of an immature permanent tooth with apical periodontitis and sinus tract. *Dent Traumatol* 2001; 17(4):185-7.
5. Murray PE, Garcia-Godoy F, Hargreaves KM. Regenerative endodontics: a review of current status and a call for action. *J Endod* 2007;33(4):377-90.
6. Trope M. Regenerative potential of dental pulp. *J Endod* 2008;34(7 Suppl.):S13-7.
7. Banchs F, Trope M. Revascularization of immature permanent teeth with apical periodontitis: new treatment protocol? *J Endod* 2004;(4):196-200.
8. Ostby BN. The role of the blood clot in endodontic therapy an experimental histologic study. *Acta Odontol Scand* 1961;19(3/4): 324-53.
9. Lovelace TW, Henry MA, Hargreaves KM, Diogenes A. Evaluation of the delivery of mesenchymal stem cells into the root canal space of necrotic immature teeth after clinical regenerative endodontic procedure. *J Endod* 2011;37(2):133-8. 13.
10. Huang GT, Sonoyama W, Liu Y, Liu H, Wang S, Shi S. The hidden treasure in apical papilla: the potential role in pulp/dentin regeneration and bioroot engineering. *J Endod* 2008;34(6): 645-51.
11. Cvek M. Prognosis of luxated non-vital maxillary incisors treated with calcium hydroxide and filled with gutta-percha. A retrospective clinical study. *Endod Dent Traumatol* 1992;8(2):45-55.
12. Martin DE, De Almeida JF, Henry MA, Khaing ZZ, Schmidt CE, Teixeira FB, et al. Concentration-dependent effect of sodium hypochlorite on stem cells of apical papilla survival and differentiation. *J Endod* 2014;40(1):51-5.
13. Galler KM, Buchalla W, Hiller KA, Federlin M, Eidt A, Schiefer-steiner M, et al. Influence of root canal disinfectants on growth factor release from dentin. *J Endod* 2015;41(3):363-8.
14. Valle's M, Roig M, Duran-Sindreu F, Mart'nez S, Mercade' M. Color stability of teeth restored with biodentine: a 6-month in vitro study. *J Endod* 2015;41(7):1157-60.
15. Jeeruphan T, Jantarat J, Yanpiset K, Suwannapan L, Khewsawai P, Hargreaves KM. Clinical research: Mahidol study 1: comparison of radiographic and survival outcomes of immature teeth treated with either regenerative endodontic or apexification methods: a retrospective study. *J Endod* 2012;38:1330-6.
16. Huang SC, Wu BC, Kao CT, Huang TH, Hung CJ, Shie MY. Role of the p38 pathway in mineral trioxide aggregate-induced cell viability and angiogenesis-related proteins of dental pulp cell in vitro. *Int Endod J* 2015;48(3):236-45.
17. Alobaid AS, Cortes LM, Lo J, Nguyen TT, Albert J, Abu-Melha AS, et al. Radiographic and clinical outcomes of the treatment of immature permanent teeth by revascularization or apexification: a pilot retrospective cohort study. *J Endod* 2014;40(8): 1063-70.
18. Nagata JY, Soares AJ, Souza-Filho FJ, Zaia AA, Ferraz CC, Almeida JF, et al. Microbial evaluation of traumatized teeth treated with triple antibiotic paste or calcium hydroxide with 2% chlorhexidine gel in pulp revascularization. *J Endod* 2014;40(6): 778-83.

How to cite this article:

Rajas Prasad et al (2017) 'Revascularization of A Non-Vital Immature Permanent Central Incisor- A Case Report', *International Journal of Current Advanced Research*, 06(12), pp. 8022-8024.
DOI: <http://dx.doi.org/10.24327/ijcar.2017.8024.1274>