

DIFFUSE SYSTEMIC SCLEROSIS: A RARE ENTITY

Mamta Sharma¹ and Mandeep Kaur²

¹Department of Oral Medicine & Radiology, Indira Gandhi Govt Dental College, Jammu

²Department of Oral Pathology & Microbiology, Indira Gandhi Govt Dental College, Jammu

ARTICLE INFO

Article History:

Received 15th July, 2017

Received in revised form 19th

August, 2017 Accepted 25th September, 2017

Published online 28th October, 2017

ABSTRACT

The oral cavity can be truly called as window of the body, because oral manifestation accompany many systemic diseases. There are many diseases whose symptoms are unique to oral cavity, others may involve other parts of the body. So as a dental practitioner every patient should be examined properly to rule out any systemic pathology present in the body. This case report describes a rare presentation of diffuse systemic sclerosis with brief review of literature.

Key words:

Scleroderma, localised, systemic, collagen disorder.

Copyright©2017 Mamta Sharma and Mandeep Kaur. This is an open access article distributed under the Creative Commons Attribution License, which permits unrestricted use, distribution, and reproduction in any medium, provided the original work is properly cited.

INTRODUCTION

Systemic scleroderma, also known as diffuse systemic scleroderma is an autoimmune disease of connective tissue. It derives its name from a Greek word 'Sclerosis' which means hard and 'Derma' which means skin. It is also called as 'Hidebound Disease'.¹ It is characterized by accumulation of collagen, and by injuries to small arteries, blood vessels and visceral organs. There are two forms of scleroderma: Localised (limited) and Systemic (diffuse). The localized form mainly affects skin of face, hands and feet. The systemic form involves skin and may also progress to visceral organs, including kidney, heart, lungs and gastrointestinal tract. Etiology is unclear and is believed to be an autoimmune disorder. Overall no racial predilection is seen. Most common age groups is 30-50 years.² A substantial female preponderance with female to male ratio of 3:1 is seen, however diffuse systemic sclerosis occurs equally in females and males.³

Prognosis is determined by the form of the disease and the extent of visceral involvement. Patient with limited cutaneous scleroderma have 10 years survival rate of 75%, less than 10% develop pulmonary hypertension after 10-20 years. Patients with diffuse cutaneous scleroderma have 10 year survival rate of 55%. Death is mostly due to involvement of lung, heart and kidney involvement. There is also slight increase in risk of cancer. Cigarette smoking decrease the overall survival rate.^{4,5}

Case Report

A 48-year-old male patient reported to the Department of Oral medicine and Radiology with a complaint of pain in the lower left posterior region since 5-6 days. Patient was well cooperative to the environment and moderately built. Patient had undergone treatment for a skin disease in the past. Skin over face, hand and feet was slightly tense and smooth with small areas of hyper pigmentation which were preferably considered as telangiectasia or spider navi or angioectasias. (Figure1) These hyperpigmented areas measured between 0.5 to 1mm. The hands were positioned in a claw like position.

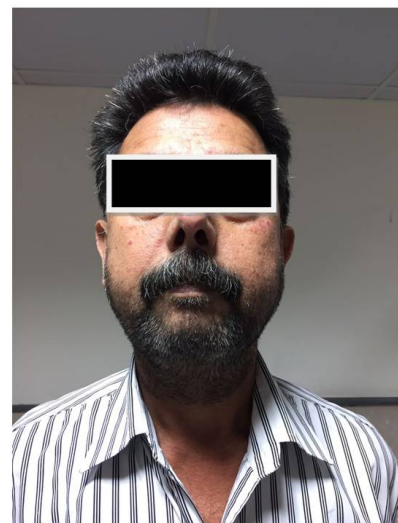

Figure 1 Hyperpigmented areas on the face

*Corresponding author: Mamta Sharma

Department of Oral Medicine & Radiology, Indira Gandhi Govt Dental College, Jammu

(Figure 2 & 3) Intraoral examination revealed full complement of teeth with Angle's class I malocclusion with minor crowding in lower anterior. Yellow stains were present over the teeth and oral mucosa was normal in appearance with no fibrotic changes.

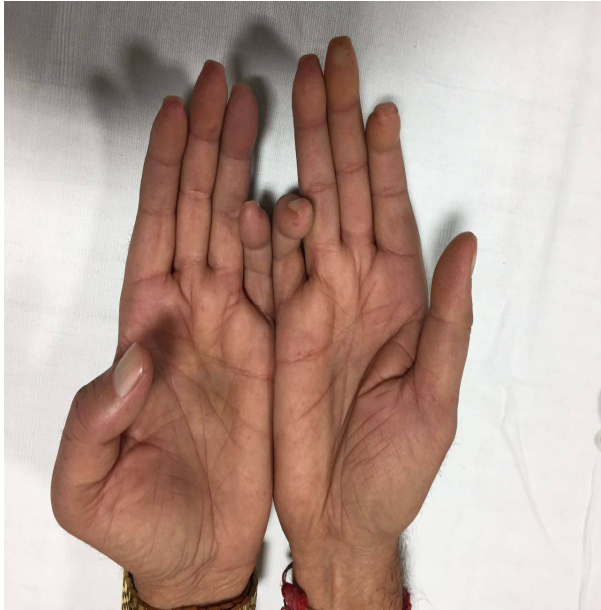


Figure 2 Claw like hands

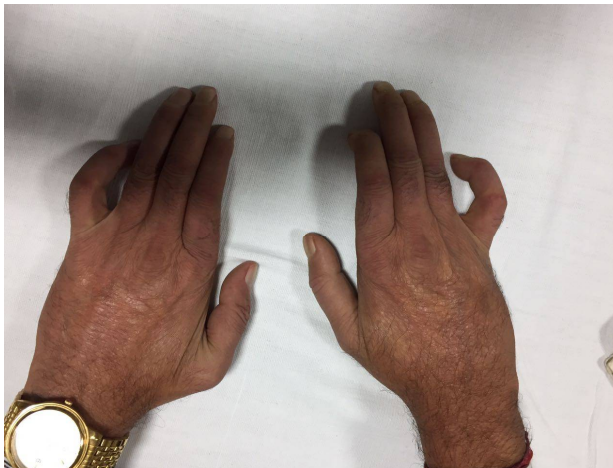

Figure 3 Claw like hands

Mouth opening was normal with normal lip thickness and competency.

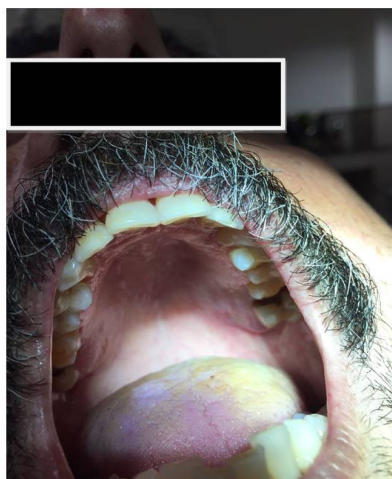

Figure 4 Blanching of the hard palate

Slight blanching was seen on the hard palate.(Figure 4) Orthopantomogram showed normal TMJ joint. Widening of periodontal ligament space was observed in relation to few teeth. (Figure 5)

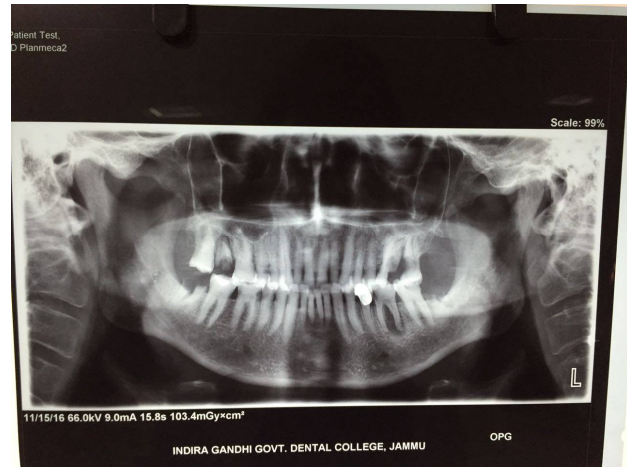


Figure 5 Widening of the periodontal ligament space

Provisional diagnosis of Scleroderma was made on the basis of history, clinical and radiological findings. Further investigations were carried out to confirm the diagnosis.

Investigations

1. ANTI ds DNA Antibody Assay
Result -10.46 IU /L
Normal-LESS THAN 30 IU /L
2. ANTI CCP Serum Assay (Cyclic citrullated peptide)
Result-200 U /ML
Normal-Less THAN 5 U /ML
3. SCL-70(Scleroderma Antibody Serum Assay)
Results-92.34 Units
Normal- Less Than 20 Units
4. Alkaline Phosphatase Level
Results- 148 U /ML
Normal-50-136 U /ML
5. Lactate Dehydrogenase Level
Results- 236
Normal-65-227
6. BUN / Creatinine
Result -18.89
Normal-5-14
7. GGT (Gamma Glutamyl Transferase Level)
Result-127
Normal-15-85
8. Chloride Level
Result-97
Normal -98-107
9. Duplex Doppler Ultrasound Studies

D MODE CHARACTERSTIC- All the major arteries of limbs were having normal intima media thickness and no significant plaque formation was seen. (Figure 6)

Doppler Characteristics-Flow was greatly dampened in distal part of right anterior tibial artery and no demonstrable flow was seen in the right dorsalis pedis artery on color flow and spectral Doppler studies. (Figure 7)

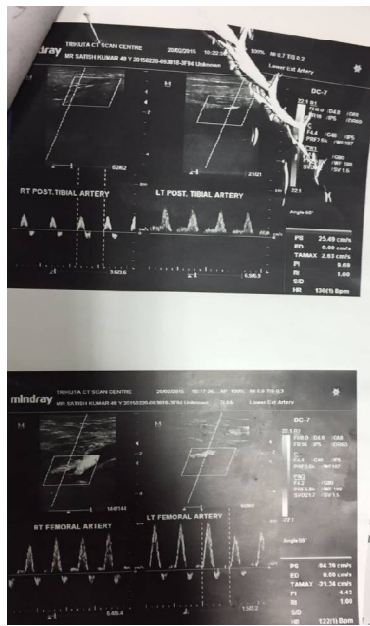


Figure 6 D Mode characteristics

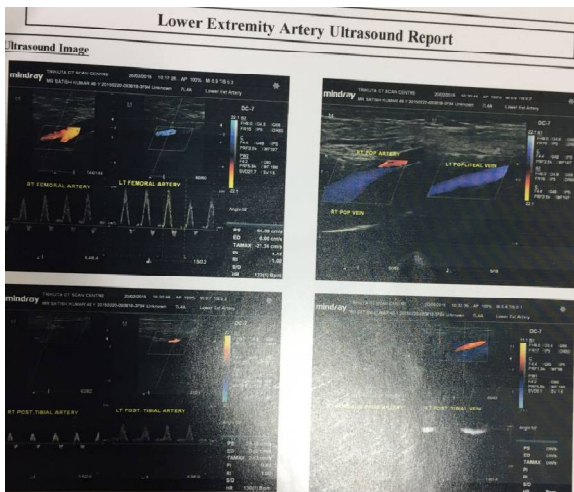


Figure 7 Doppler characteristics

Hence correlating the clinical and radiographic features with the results of various investigations, a final diagnosis of diffuse systemic sclerosis was made.

DISCUSSION

History of scleroderma dates back to 1752 when Carlo Cuzio of Naples wrote about this in his monography. In 1847, Gintrac named it as ‘Sclerodermie’. Later in 1945 Goetz gave the name as ‘Progressive Systemic Sclerosis’ after eliciting the systemic nature of the disease.⁶ Scleroderma is an autoimmune disorder affecting the skin and other parts of the body. Body’s immune system is causing the inflammation and other abnormalities in these tissues. The pathogenesis of scleroderma is not clear but it is mainly characterized by endothelial activation, immune system dysfunction and increased fibroblastic activity. The endothelium is responsible for controlling the contraction and relaxation of vascular smooth muscle cells thus leading to vasospasm and smooth muscle hypertrophy. Eventually obliteration of the lumen of small arteries and capillaries occurs and then causes ischemia. There is also extravasation of inflammatory cells initially

predominated by monocytic lineage and later by lymphocytes.^{7,8}

Scleroderma presents clinically as two major forms: Localised form and Systemic form. Localized form affects the skin without any involvement of internal organs and stimulates fibroblast to produce excessive extracellular matrix which is the hallmark of scleroderma.⁹ Tuffanelli and Winkelmann classified localized scleroderma into three types:

- Circumscribed sclerotic plaques (Morphia)
- Streaks on the skin (Linear)
- Generalize morphia where there is widespread skin involvement with multiple plaque and muscle atrophy.

Systemic scleroderma was classified by Lepoy *et al* as,

- Limited cutaneous systemic scleroderma formally called calcinosis, Raynaud phenomenon, esophageal dysmotility, sclerodactyly and telangiectasia.
- Diffuse systemic scleroderma: Sclerosis of face, trunk, proximal extremities.
- Systemic scleroderma sine scleroderma: No skin thickening only organ fibrosis.

Raynaud’s phenomenon is one of the earliest manifestations of the disease though it may not typical show the typical triphasic color changes in affected individuals when exposed to cold and stress but does present as pallor of the digits. The case presented here also showed features of systemic scleroderma. It is more commonly seen in females between 3rd to 5th decades of life. But our patient was a 48 year old male. The most frequent oral finding to precede involvement of systemic sclerosis appears to be a trigeminal neuropathy followed by widening and enlargement of periodontal ligament space which was also evident in OPG of the case presented. Widening of periodontal ligament space is mainly due to excessive deposition of collagen fibres, oxytalan fibres and subsequent resorption of alveolar crest bone surrounding the root. Posterior teeth are more commonly involved than the anterior teeth. Trigeminal neuropathy is characterized by slow and gradual facial muscles inactivity followed by mild to severe pain and paresthesia. Another significant oral finding is the increased risk of oral carcinoma.^{10,11}

Mask like appearance of the face due to loss of folds around mouth, thinned and rigid lips and tongue rigidity, sunken eyes, parrot beaked nose, stretched, shiny not pinchable skin, fish mouth appearance of lips pursed with radiating furrows, burning sensation, gingival recession, fibrosis and blanching are various other oral and facial manifestation of systemic scleroderma. Rigidity of tongue caused difficulty in speech, mastication and deglutition. Involvement of periarticular tissue of TMJ along with microstomia results in limited mouth opening thus causing pseudoankylosis.¹² Few features were seen in our case mainly slightly tense skin, hyper pigmentation and blanching of palate and claw like hands. Patient can have salivary hypofunction, keratoconjunctivitis sicca or both. Xerostomia can result in increased susceptibility to dental caries, candidal infections and periodontal disease. In the case presented patient periodontal status was moderate with yellow generalized stains on the teeth.

These patients suffer from severe flexion deformities of the fingers and other body joints and thus have reduced manual

dexterity. Claw like hands were clearly evident in the case presented.

Due to various forms and extent of systemic involvement, it is difficult to predict the prognosis of systemic sclerosis. In a study of 237 adult patients over 11 years, the mortality rate was 25.7%. The overall 3, 6, 9 year survival rate were 86%, 76% and 61% respectively. Pulmonary manifestation was the most frequent cause of death. However, adverse prognostic factors include renal, cardiac and pulmonary involvement in decreasing order of importance.¹³ Anti ccp antibody are useful for evaluating patient of rheumatic arthritis, positive results are seen in 60-80% of RA patients depending upon the severity. Antibodies to SCL-70 (DNA topoisomerase 1) are detected in nearly 75% of patients with progressive systemic sclerosis. These are also detected in 20-59% patients of connective tissue disorders and 13% patient with CREST Syndrome.¹⁴ These investigation were performed in our case and were in favor of DSS.

Non-pharmacological methods are useful to prevent or avoid exacerbation. They include the use of gloves; avoidance of cold and stress; avoidance of nicotine, caffeine and sympathomimetic medications. Calcium channel blockers are the first line agents for RP. Nifedipine is most widely recommended, because there are several controlled trials showing its effectiveness in reducing RP as well as digital ulcers. Amlodipine is another agent of choice.¹⁵ Antithrombotic agent e.g. Dipyridamole is used for its anti-platelet and vasodilating effects, however, it was not shown to have major impact on severe Raynaud's Phenomenon (RP). Other vasodilators e.g. hydralazine or angiotensin converting enzyme inhibitors were used when the patient was not responding to calcium channel blockers. In general, disease heterogeneity is an important factor in the treatment plan. With the manifestation of RP calcium channel blockers, angiotensin Type II receptor blocker, surgical sympathectomy will be the treatment of choice.¹⁶ Cases with digital ulcers, skin fibrosis, arthritis, myositis, drugs like immunosuppressive, non steroidal anti-inflammatory drugs, low dose of steroids are given. In severe cases of renal crisis and pulmonary hypertension angiotensin-converting enzyme inhibitors are the recommended treatment modalities.¹⁷ Localised dermatological lesions have been found to improve with UV therapy. Antibiotics are useful in treating skin ulcerations.¹⁸ Maintenance of existing dentition is important because microstomia and tongue rigidity can interfere with prosthetic rehabilitation. As part of prevention proper oral hygiene habits, oral exercise techniques and importance of good permanent restorative dentistry should be stressed to such patients.

CONCLUSION

Scleroderma is a rare generalized autoimmune collagen disorder characterized by diffuse fibrosis of skin, muscles and other internal organs. So it is important for a practicing dentist to recognize scleroderma because of its extensive visceral involvement including heart, lungs and kidney which may complicate the dental procedures.

References

1. Athathya RS, Deepalakshmi D, Emmadi P. Systemic sclerosis. *Indian J. Dent Res* 2007; 18:27-30.
2. Cawson RA, Odell EW. CAWSON Essential of oral pathology and oral medicine. 8 edition 2008 pg 195c.
3. Ngugen C, Berezne A, Bambet T *et al.* Association of gender with clinical exp, qquality of life. *PLOS ONE* 2011; 6(3)17551.
4. Onishi A, Sugiyama D, Kumagai, Morinunum A. Cancer. Incidence in systemic sclerosis. 2013; 65(7):1913-21
5. Hissaria P, Robertz, Thomson PJ, Lister S. Ahem MD, Smith MD, Walker JG, Ciggratte smoking in patient of systemic sclerosis reduces overall survival. *Arthritis rheumat.* 2011; 24:63(6):1758-9.
6. Goetz RH. The pathology of progressive systemic sclerosis with special references to viscera. *Clin Proc.* 1945; 4:337-392.
7. Yamamoto T. Scleroderma - Pathophysiology. *Eur J Dermatol* 2009; 19:14-24.
8. Marmary Y, Glaiss R, Pisanty S. Scleroderma: oral manifestations. *Oral Surg Oral Med Oral Pathol* 1981; 52:32-7.
9. Barnett AJ, Miller M, Littlejohn GO. The diagnosis and classification of scleroderma (systemic sclerosis). *Postgrad Med J* 1988; 64:121-5.
10. Rubin MM, Sanfilippo RJ. Resorption of mandibular angle in progressive systemic sclerosis. *Oral Surg Oral Med Oral Pathol.* 1992; 50:75-77.
11. Nagy G, Kovacs J, Zeher M, Czirjak L. Analysis of oral manifestations of systemic sclerosis. *Oral Surg Oral Med Oral Pathol.* 1994; 77:141-146.
12. Stafne EC, Austin LT. A characteristics dental findings in acrosclerosis and diffuse sclerosis. *Am J Orthod.* 1944; 30:25.
13. Lee P , Langevitz P , Alderdice CA, Aubrey M, Baer PA, Baron M, *et al.* Mortality in Systemic Sclerosis (scleroderma). *Q J Med.* 1992; 82:139-148.
14. Denton CP, Black CM. Scleroderma. Clinical and pathological advances. *Best Prac Res Clin Rheumatol.* 2004; 18:271-90.
15. Thompson AE, Shea B, Welch V, Fenlon D, Pope JE. Calcium channel blockers for Raynaud's phenomenon in systemic sclerosis. *Arthritis Rheum* 2001; 44:1841-7.
16. Naylor WP. Oral management of the scleroderma patient. *J Am Dent Assoc* 1982; 105:814-7.
17. Shah AA, Wigley FM. My approach to the treatment of scleroderma. *Mayo Clin Proc* 2013; 88:377-93.
18. Kreuter A, Breuckmann F, Ulhe A *et al.* Low dose UVA1 phototherapy in systemic sclerosis: Effect on acrosclerosis. *J Am Acad Dermatol.* 2004; 50:740-747.
