



## COMPARISON OF SENSITIVITY OF ELISA FOR DIAGNOSING SINGLE VERSUS MULTIPLE RING LESION IN NEUROCYSTICERCOSIS IN A TERTIARY CARE HOSPITAL IN ALIGARH

Samia Kirmani\*, Haris M Khan and Mohd Khalid

Department of Microbiology, JNMC, AMU, Aligarh, UP, INDIA

### ARTICLE INFO

#### Article History:

Received 15<sup>th</sup> July, 2017

Received in revised form 19<sup>th</sup>

August, 2017 Accepted 25<sup>th</sup> September, 2017

Published online 28<sup>th</sup> October, 2017

#### Key words:

Neurocysticercosis, ELISA, multiple lesion, single lesion.

### ABSTRACT

**Objectives:** 1.To determine the sensitivity of IgG ELISA for diagnosing single lesion neurocysticercosis (NCC) in patients presenting with signs and symptoms of NCC.2.To determine the sensitivity of IgG ELISA for diagnosing multiple lesion NCC in patients presenting with signs and symptoms of NCC.3.To compare sensitivity of ELISA in single vs multiple lesion NCC.

**Material and methods:** The study was conducted in the Department of Microbiology and allied departments of JNMCH, Aligarh from January 2012 to June 2013. Study group comprised of 45 patients presenting with symptoms suggestive of NCC and were found to have single or multiple ring lesions on MRI. 15 controls were also included in the study. NovaTec Taeniasolium IgG ELISA was used to detect antibodies against *Taeniasolium*.

**Results:** Majority of patients 31 (68.9%) were males and the remaining 14 (31.1%) were females. Majority 42 (93.3%) of the patients were found to have a single ring lesion on MRI while only 3 (6.7%) patients had multiple lesions involving more than one lobe. Sensitivity of ELISA was found to be 7.1 % in single lesion compared to 100 % in multiple lesion NCC.

**Conclusion:** single lesion NCC is more common compared to multiple lesion. Young males form the most common risk group. From the current study it is evident that the sensitivity of ELISA for diagnosing multiple lesion NCC is more (100%) as compared to 7.1 % in single lesion NCC.

Copyright©2017 Samia Kirmani et al. This is an open access article distributed under the Creative Commons Attribution License, which permits unrestricted use, distribution, and reproduction in any medium, provided the original work is properly cited.

### INTRODUCTION

Cysticercosis, is a major public health problem, especially in the developing world and Neurocysticercosis (NCC) is one of the most common infections of the nervous system in humans (Peralta *et al.*, 2002). NCC is caused by cysticercoid larvae of *Taeniasolium*, a cestode. *Taeniasolium* is commonly called as Pork tapeworm. The disease is prevalent in developing countries where favourable conditions for the transmission of this parasite like warm climate, severe poverty, and illiteracy are present. Both adults and cysts are pathogenic. But cyst are more pathogenic causing cysticercosis. Cysticerci generally affects adults and rarely children. NCC is responsible for large no of cases of seizures in developing countries. NCC is the leading cause of adult-onset epilepsy. Single lesion neurocysticercosis is more common compared to multiple lesion. Diagnosis of NCC is very difficult because of its pleomorphic presentation and its prevalence is still underestimated because of difficulties in its diagnosis (fleury *et al.*, 2006). For diagnosis, CT and MRI are recommended (Del Brutto *et al.*, 2001). CT is the best radiological method

for the detection of intraparenchymal calcification while MRI is more sensitive for the identification of cysts in the ventricles. Immunodiagnostic tests can be divided in two major groups: the ones that use an antigenic mixture or single antigens to try to find antibodies against them; and the ones that use specific antibodies to find specific antigens in the samples. Thus to supplement the previous studies the present study was conducted to study the sensitivity of ELISA for diagnosing single vs multiple lesion neurocysticercosis in patients presenting with clinical and radiological features suggestive of neurocysticercosis at J. N. Medical College, Hospital.

### MATERIALS AND METHOD

The present study was conducted in the Department of Microbiology, Radiodiagnosis and allied departments of J. N. Medical College Hospital, Aligarh over a period of one and a half years from February, 2012 to September, 2013. A total of 45 patients presenting to Department of Radiodiagnosis with seizures, headache, confusion and other nonspecific symptoms suggestive of neurocysticercosis (NCC) and were found to have radiological features highly suggestive of NCC were included in the study. Apart from study group, 11 age and sex matched patients were included

\*Corresponding author: Samia Kirmani

Department of Microbiology, JNMC, AMU, Aligarh, UP, INDIA

as control. All the cases were subjected to a detailed history and clinical examination. This study was approved by Institutional Ethics Committee of the Faculty of Medicine, A.M.U., Aligarh. Informed consent was obtained from the patients or from parents or guardians of patients less than 18 years of age. 5 ml of venous blood was withdrawn in vacutainer tubes from all patients after obtaining verbal informed consent and observing all sterile precautions. After 30 minutes, the tubes were centrifuged at 2000 rpm for 5 minutes for separation of sera. The sera were aliquoted in labelled vials and stored at -20°C. ELISA was done on serum samples of all patients and IgG antibodies were estimated Kit used: Taeniasolium IgG ELISA (Novatec Immunodiagnostica GmbH, Germany)

**RESULTS**

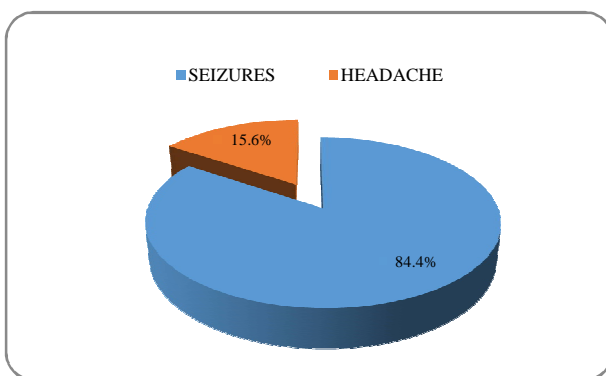
A total of 45 blood samples were collected from patients presenting with symptoms of neurocysticercosis and were found to have radiological features suggestive of NCC. All the samples were subjected to ELISA tests.

Maximum number of patients 22 (48.9%) belonged to age-group 15-29 years Age group 30-44 and age-group 45 and above had least number of patients with 3 (6.7%) patients in each age-group as shown in Table 1. Majority of patients 31 (68.9%) were males and the remaining 14 (31.1%) were females with male:female ratio of 2.2:1.

**Table I** Age and gender distribution of patients (n=45).

Age (years)	Male (%)	Female (%)	Total (%)
Less than 15	10(22.2)	7(15.6)	17(37.8)
15-29	18(40.0)	4(8.9)	22(48.9)
30-44	2(4.4)	1(2.2)	3(6.7)
45 and above	1(2.2)	2(4.4)	3(6.7)
Total	31(68.9)	14(31.1)	45(100)

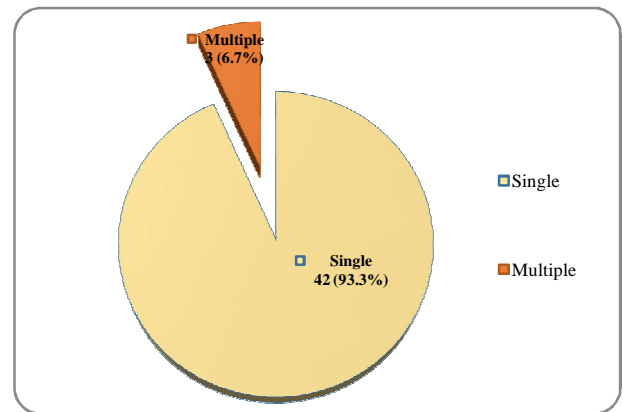
38 (84.4%) patients presented with seizures and only 7 (15.6 %) patients had headache as their chief presenting complaint (Figure -1). However seizure was observed in 41 (91.1%) patients.



**Figure I** Distribution of patients according to their presenting complaints.

Majority 42 (93.3%) of the patients were found to have a single ring lesion on MRI while only 3 (6.7%) patients had multiple lesions involving more than one lobe (Figure-2).

IgG antibodies against *Taeniasolium* were positive in 6 (13.3%) patients by ELISA (Table-2). Sensitivity of ELISA was found to be 7.1% in single lesion as compared to 100% in multiple lesion neurocysticercosis (Table-3).



**Figure II** Distribution of patients according to number of ring lesions.

**Table II** Distribution of patients according to the results observed in IgG ELISA test.

IgG ELISA	Number of patients in study group (n=45)
Positive	6 (13.3)
Negative	36 (80.0)
Grey zone	3 (6.7)
Total	45(100)

**Table III** Distribution of IgG ELISA results with type of ring lesion.

	ELISA	Percentage
Single	positive	3 7.1
	negative	36 85.7
	Grey zone	3 7.1
	total	42 93.3
Multiple	positive	3 100
	negative	0 0
	Grey zone	0 0
	total	3 6.7

**DISCUSSION**

NCC is a highly pleomorphic disease with varied clinical presentations. MRI is helpful in its diagnosis but more reliable diagnostic techniques need to be developed for its accurate diagnosis. We studied the role of ELISA for diagnosis of NCC and compare its sensitivity in single versus multiple lesion neurocysticercosis.

NCC is more common in young males worldwide. Maximum number of patients (48.9%) in this study were noted in the age-group of 15-29 years. Similar age distribution was noted by other authors (Crocker *et al.*, 2012, Patil and Paithankar 2012, Chakraborty *et al.*, 2011, Kotokey *et al.*, 2006).

Males are more commonly affected (68.9%) in present study. This is in corroboration with the findings of other authors. Males comprised 62.1% (Sailaja and Devi 2015), 57.6% (Crocker *et al.*, 2012), 54% (Del Brutto 2012) 67.5% (Patil and Paithankar 2012), 68% (Chakraborty *et al.*, 2011). 60.5% (Gauchan *et al.*, 2011), 51.7% (Fleury *et al.*, 2010).

Seizure was the most common clinical feature observed in 91.1% patients followed by headache in 71.1% patients. Del Brutto (2012) found seizures in 73%, Gauchan *et al* (2011) in 77.9% of patients, Chakraborty *et al* (2011) in, 90% of patients.

In our study, 93.3% of patients had single ring enhancing lesion while only 6.7% patients had multiple ring lesions on MRI. Most of the studies in India deal with single lesion

NCC. Similarly, Patil and Paithankar 2012 found single lesion in 72.5% patients, Gauchan *et al* (2011) in 81.6%, Shukla *et al* (2008) in 72%, Kotokey *et al* (2006) in 66.66%, Rajshekhar *et al* (2006) in 60.88%. Yamasaki (2013) while studying epidemiology of cysticercosis in Japan reported differently with 51.9% of patients having multiple lesions.

The ELISA has been used widely by various authors for the detection of cysticercus antibodies in the serum with variable sensitivities. In the present study IgG antibodies against *Taeniasolium* were detected in 13.3% patients and all controls were negative. Considering all cases diagnosed on MRI as probable cases of NCC, the sensitivity and specificity of the test came out to be 13.3% and 100% respectively. Low seropositivity observed in the present study can be due to inclusion of probable cases and not definitive cases as included in other studies showing higher seropositivity.

Intapan *et al* (2008) while studying IgG antibodies against cysticerci by ELISA observed 21.4% seropositivity with HP6-3 antigen. Verastegui *et al* (2003) noted 20% of cases were seropositive. Mittal *et al* (2001) found a sensitivity of 10.4%.

Out of the 3 patients having multiple ring lesions on MRI, all tested positive for IgG ELISA (100%). Harrington *et al* (2009) also noted higher sensitivity in patients with multiple cysts. This makes serologic testing a less useful diagnostic tool for patients with solitary central nervous system lesions. A low sensitivity was observed in cases with low number of cysts (Proano-Narvaez *et al* 2002).

## CONCLUSION

Single lesion neurocysticercosis is more common compared to multiple lesion. Young males form the most common risk group. From the current study it is evident that the sensitivity of ELISA for diagnosing multiple lesion neurocysticercosis is more (100%) as compared to 7.1 % in single lesion neurocysticercosis. Thus immunological tests are of limited use for the diagnosis of NCC. However ELISA is very useful in diagnosis of patients with multiple cystic lesions where tuberculoma and metastatic lesions cannot be ruled out by imaging studies.

## Acknowledgement

We are thankful to staff of our Microbiology department and Radiology staff for their cooperation.

## References

1. Peralta RHS, Vaz AJ, Pardini A, Macedo HW, Machado LR, De Simone SG *et al*. 2002. Evaluation of an antigen from *Taeniacrassiceps* cysticercus for the serodiagnosis of neurocysticercosis. *Acta Tropica.*, 83 (2): 159-168.
2. Fleury A, Morales J, Bobes RJ, Dumas M, Yanez O, Pina J, *et al*. 2006. An epidemiological study of familial neurocysticercosis in an endemic Mexican community. *Transactions of the Royal Society of Tropical Medicine and Hygiene.*, 100(6):551-558.
3. Del Brutto OH, Rajshekhar V, White AC Jr, Tsang VC, Nash TE, Takayanagui OM *et al*. 2001. Proposed diagnostic criteria for neurocysticercosis. *Neurology.*, 57(2): 177-183.
4. Croker C, Redelings M, Reporter R, Sorvillo F, Mascola L, Wilkins P. 2012. The Impact of neurocysticercosis in California: A review of hospitalized cases. *PLoS Negl Trop Dis.*, 6(1): 1480.
5. Patil TB, Paithankar MM. 2012. Clinico-radiological profile and treatment outcomes in neurocysticercosis: A study of 40 patients. *Ann Trop Med Public Health.*, 5(2): 63-68.
6. Chakraborty A, Panja S, Bhattacharjee I, Chandra G, Hati A. 2011. A longitudinal study of neurocysticercosis through CT scan of the brain. *Asian Pacific Journal of Tropical Disease.*, 206-208.
7. Kotokey RK, Lynrah KG, De A. 2006. A Clinico-serological study of neurocysticercosis in patients with ring enhancing lesions in CT scan of brain. *Journal of the Association of Physicians of India.*, 54; 366-370.
8. Sailaja M and Devi SU. 2015. Detection of Neurocysticercosis by Comparing the Radiological Changes in CT Imaging and ELISA Test using ES Antigen. *International Journal of Current Microbiology and Applied sciences.*, 4 ( 12):513-520.
9. Del Brutto OH. 2012. Neurocysticercosis among international travelers to disease-endemic areas. *J Travel Med.*, 19(2): 112-117.
10. Gauchan E, Malla T, Basnet S, Rao KS. 2011. Variability of presentations and CT-scan findings in children with neurocysticercosis. *Kathmandu Univ Med J.*, 9(34): 17-21.
11. Fleury A, Escobar A, Fragoso G, Scitutto E, Larralde C. 2010. Clinical heterogeneity of human neurocysticercosis results from complex interactions among parasite, host and environmental factors. *Trans R Soc Trop Med Hyg.*, 104: 243-250.
12. Shukla N, Husain N, Jyotsna, Gupta S, Husain M. 2008. Comparisons between scolex and membrane antigens of *Cysticercus fasciolaris* and *Cysticercus cellulosae* larvae for immunodiagnosis of neurocysticercosis. *Journal of Microbiology, Immunology and Infection.*, 41(6): 519-524.
13. Rajshekhar VM, Raghava V, Prabhakaran V, Ommen A, Muliylil J. 2006. Active epilepsy as an index of burden of neurocysticercosis in Vellore district, India. *Neurology.*, 67: 2135-2139.
14. Yamasaki H. 2013. Current status and perspectives of cysticercosis and taeniasis in Japan. *Korean J Parasitol.*, 51(1): 19-29.
15. Intapan PM, Khotsri P, Kanpittaya J, Chotmongkol V, Maleewong W, Morakote N. 2008. Evaluation of IgG4 and total IgG antibodies against cysticerci and peptide antigens for the diagnosis of human neurocysticercosis by ELISA. *Asian Pacific Journal of Allergy and Immunology.*, 26: 237-244.
16. Verastegui M, Gilman RH, Garcia HH, Gonzalez AE, Arana Y, Jeri C *et al*. 2003. Prevalence of antibodies to unique *taeniasolium* monoclonal antigens in taeniasis and human and porcine cysticercosis. *Am J Trop Med Hyg.*, 69(4): 438-444.
17. Mittal V, Singh VK, Ichhapujani RL. 2001. Detection of antibodies to *Taeniasolium* in sera of patient with epilepsy using ELISA. *J Communicat Disor.*, 33: 23-27.

18. Harrington AT, Creutzfeldt CJ, Sengupta DJ, Hoogestraat DR, Zunt JR, Cookson BT. 2009. Diagnosis of neurocysticercosis by detection of *Taeniasolium* DNA using a global DNA screening platform. *Clin Infect Dis.*, 48(1): 86-90.
19. Proano-Narvaez JV, Meza-Lucas A, Mata-Ruiz O, Garcia-Jeronimo RC, Correa D. 2002. Laboratory diagnosis of human neurocysticercosis: Double-blind comparison of enzyme-linked immunosorbent assay and electroimmunotransfer blot assay. *J ClinMicrobiol.*, 40: 2115-2118.

**How to cite this article:**

Samia Kirmani *et al* (2017) 'Comparison of Sensitivity of Elisa for Diagnosing Single Versus Multiple Ring Lesion in Neurocysticercosis in A Tertiary Care Hospital in Aligarh', *International Journal of Current Advanced Research*, 06(10), pp. 6622-6625. DOI: <http://dx.doi.org/10.24327/ijcar.2017.6625.0980>

\*\*\*\*\*