



SANDWICH SILICONE TECHNIQUE FOR SECURING INTRA-ORAL SKIN GRAFTS TO THE BUCCAL MUCOSA DEFECTS

Priyankar Singh*, Sripathi Rao B. H., Joyce P Sequeira., Gunachandra Rai., Jagadish Chandra., Vinaykrishna K., Arvind Rao

Department of Oral and Maxillofacial Surgery, Yenepoya Dental College Mangalore, Karnataka, India

ARTICLE INFO

Article History:

Received 15th July, 2017

Received in revised form 19th

August, 2017 Accepted 25th September, 2017

Published online 28th October, 2017

Key words:

Cheek Defects, Skin Graft, Stent, Silicone Sheet

ABSTRACT

Introduction: The stabilization of skin graft on intra oral surgical defects remains a challenge to many experienced surgeons. Various methods have been tried in past to secure the skin graft intra orally and still there is a constant search for an ideal biocompatible material which can be placed amicably to cover the grafted skin, induce proper stabilization and avoid failure of graft uptake.

Objectives: The chief objective of this pilot study was to evaluate the efficacy of silicone sheets as biocompatible stent to secure intra oral skin grafts to the buccal mucosa surgical defects.

Material and Methods: 9 patients (6 Males & 3 Females) between 20-60 years (mean age of 40.5 years), having benign lesion on their buccal mucosa were included in the study, and were planned for surgical excision of the lesion and reconstruction with split thickness skin graft. A non-reinforced, transparent silicone sheet of size 150x200 mm and thickness of 0.005 inch was used to secure skin graft in a sandwich technique, with one sheet placed intra orally over the skin graft and the other placed extra orally on the cheek, tied together with trans buccal sutures. Post operative findings were assessed based on graft size, capillary test, mouth opening and healing of the graft and surgical defect.

Results: The silicone sheet got displaced from the skin graft and thus gave an uneven capillary test. The skin graft size reduced remarkably due to sloughing and very less graft uptake was seen. The mouth opening improved with every post operative day, and healing of the surgical defect was satisfactory as assessed by Landry Turnbull and Howley index.

Conclusion: The recommendation to use non-reinforced (.005 inch), 150x200mm silicone sheet as an stent for intra oral skin graft in a sandwich technique stands doubtful, but a further study can be done with thicker silicone sheet and proper adaptation of same intra-orally by quilting the sheet properly to the skin graft and cheek mucosa and keeping the cheek immobilized.

Copyright©2017 Priyankar Singh et al. This is an open access article distributed under the Creative Commons Attribution License, which permits unrestricted use, distribution, and reproduction in any medium, provided the original work is properly cited.

INTRODUCTION

The stabilization of skin graft on intra oral surgical defects remains a challenge to many experienced surgeons. Mobilization and improper adherence of the graft to the intra oral defect due to constant mobility of cheek during mastication and speech is a major threat for graft acceptance and survival. Adding to the failure, the salivary secretions tend to accumulate beneath the graft which separates it from its surgical bed. Post surgery, reduced mouth opening is also a matter of concern as the skin graft shrinks due to improper stabilization thus leading to wound contraction and healing with secondary intention. In myriad of available literature, commonly used methods and types of stents have been described for immobilization and bolstering of the skin graft,

varying from simple cotton balls[1], dental resin moulds [2], denture soft liners [3], vinyl polysiloxane[4], graft stabilizing clips [5], polyurethane sponge[6], impression compound[7], foam pads[8] to complex stents such as metal[9]. Still, there is a constant search for an ideal stent for intra oral skin graft, which can be placed amicably to cover the grafted skin, induce proper stabilization and avoid failure of graft uptake.

Among newer materials, one of the most experimental and biocompatible material which can be used in present time is the silicone sheet. It has been extensively used in animal studies and has given encouraging results [10]. Presently silicone sheet is being used in general surgery procedures to cover skin grafts in the human body following burns, open wounds [11] and surgical excisions. Silicone sheets have been successfully used in treatment of discectomy [12], mastoidectomy [13], and for treatment of keloids [14]. The favorable points which drew our attention to use silicone

*Corresponding author: Priyankar Singh


Department of Oral and Maxillofacial Surgery, Yenepoya Dental College Mangalore, Karnataka, India

sheets as stents were that they are made of medical grade, flexible and transparent silicone elastomeric material. The sheets can be easily cut to any size and shape and can be autoclaved. Its removal is facilitated by their low tendency to adhere to the adjacent tissue. They can be customized to adapt to several medical applications and are available in various thicknesses and flexibilities. They have very high tear resistance and dimensional stability due to their double knit polyester fabric structure. Hence, a pilot study was done to evaluate the efficacy of commercially available silicone sheet as a biocompatible stent over split thickness skin graft in buccal mucosa defects following excisions of any benign buccal mucosa lesion.

MATERIAL AND METHODS

This pilot study was done in the department of oral and maxillofacial surgery at Yenepoya Dental College, Mangalore from September 2008 till June 2011.

Those patients who were ASA - Grade I (systemically healthy patients), who required intraoral skin grafting to cover the raw surfaces resulting from wide excision of premalignant lesions or conditions like leukoplakia, lichen planus, oral submucous fibrosis, fibroma, lipoma, irritational growths, mucocele or with any benign lesion planned for surgical excision were included in the study. Patients below 20 years and above 60 years of age, with evidence of systemic or oral infection, uncontrolled systemic disorders i.e., ASA grade II to IV and those who were not willing to quit adverse habits of consumption of tobacco, alcohol and smoking were excluded from the study. Among all those patients who reported to our OPD with a benign buccal mucosa lesion only 9 patients (6 Males & 3 Females) got ready for the study and they also fitted in our inclusion criteria. Their age was between 20-60 years (mean age of 40.5 years). Out of these 9 patients, 6 patients had oral submucous fibrosis, 2 patients had lichen planus and 1 patient had fibroma at buccal mucosa, all with decreased mouth opening (mean mouth opening of 3.978 cms). A clearance was obtained from the ethical committee and written consent was taken from all the patients included in the study. The Silatos Silicone Sheet used for this study purpose was sterile, individually packed, non-reinforced transparent and of size 150x200 mm and thickness of 0.005 inch [Table/Figure 1].



Table/Figure 1 Non-reinforced, transparent Silatos Silicone Sheets and of size 150x200 mm and thickness of 0.005 inch

The surgery was performed under general anesthesia by a single surgeon to reduce inter surgeon errors. After wide

surgical excision of the lesion, the raw wound area was cleaned and haemostasis was achieved [Table/Figure 2 A]. The split thickness skin graft was harvested from inner hairless thigh and small perforations (pie crusting) were made in the graft to allow any collected blood to be evacuated. The split thickness skin graft was then sutured to the raw area with resorbable sutures at periphery and few quilting sutures at center to avoid any dead space [Table/Figure 2 B]. Two silicone sheets were cut designed little larger than the area of the defect to cover the skin graft completely and were applied, one intra-orally over the skin graft in the gingivo-buccal sulcus [Table/Figure 2 C] and the other extra-orally over the cheek opposing the intra oral plate [Table/Figure 2 D]. The two sheets were secured by 4.0 silk sutures that were passed trans-buccally with straight needle, through the two sheets and were sutured both at centre and at the periphery, the knots lay extra-orally resting over a gauze piece. The sheets were left in place for 7 days. Patients were advised for gentle mouth opening exercises from 1st post operative day only and were kept under observation for 10 days for thorough monitoring. All patients were given same drugs and were on Ryle's tube feeding for initial 4-5 post-operative days.

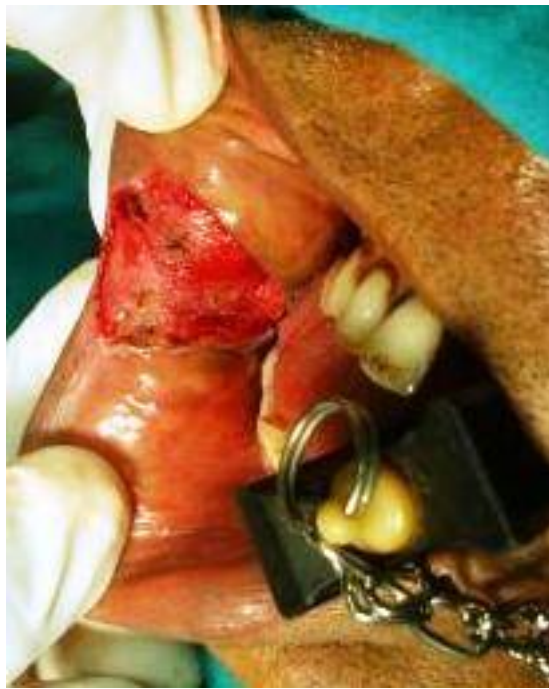All post operative findings were assessed on following criteria as 1.) Stabilization and close contact between silicone sheet and skin graft by capillarity test method. 2.) Stabilization and healing of the skin graft to excised cheek mucosa by healing index for soft tissue by Landry, Turnbull and Howley [15]. 3.) Shrinkage of the graft on recipient bed by objective measured scale. 4.) Amount of mouth opening (pre and post operative) on a measured scale value. Skin graft was evaluated under thin transparent silicone sheets, on subsequent, 1st, 3rd, 5th, 7th and 10th post operative days. Degree of skin graft contracture was assessed by measuring the initial graft size and graft size on subsequent 1st, 3rd, 5th, 7th and 10th post operative days. Degree of mouth opening was assessed by measuring preoperative, and post operative (on subsequent 1st, 3rd, 5th, 7th and 10th post operative days.) inter incisal distance, using calipers and a scale. Efficacy of silicone sheet as a stent was assessed using capillary test and was checked for even and un-even covering of skin graft all along the defect.

RESULTS

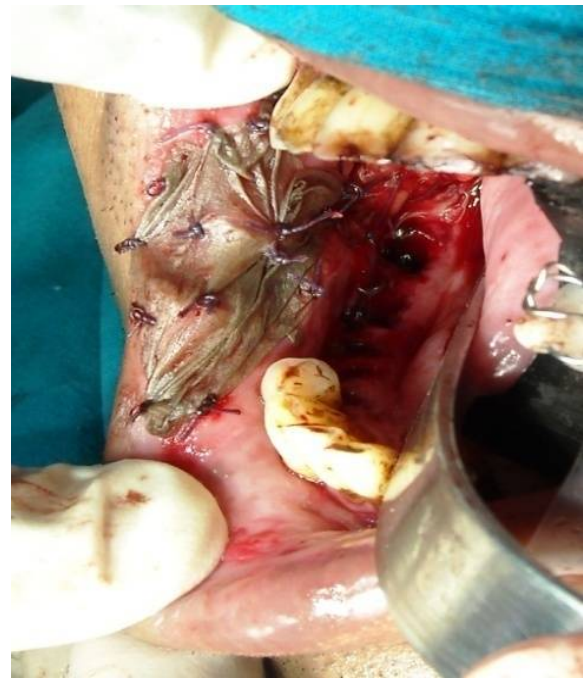A total of 9 patients (6 Males & 3 Females) were included in the study. Their age range was from 20 to 60 years with a mean age of 40.5 years. Out of these 9 patients, 6 patients had oral submucous fibrosis, 2 patients had lichen planus and 1 patient had fibroma at buccal mucosa. All the 9 patients were comfortable with intraoral split thickness skin grafting and silicone sheet as a stent in sandwich technique. There were no dropouts from the study and none of the patients complained about the sensation of foreign body or any bad odor. Allergic reactions both systemic and local to graft material were not seen. The donor site of skin graft site healed uneventfully.

Statistical analysis

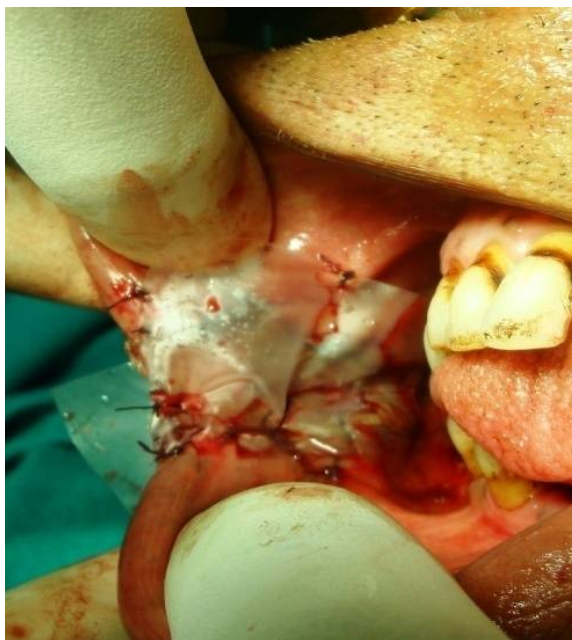
The collected data was statistically analyzed and a paired t test was done to assess the graft size and mouth opening on each post operative day. A Wilcoxon sign rank test was done to assess the healing of recipient site with each post operative day. A p value of <0.05 was considered to be statistically significant



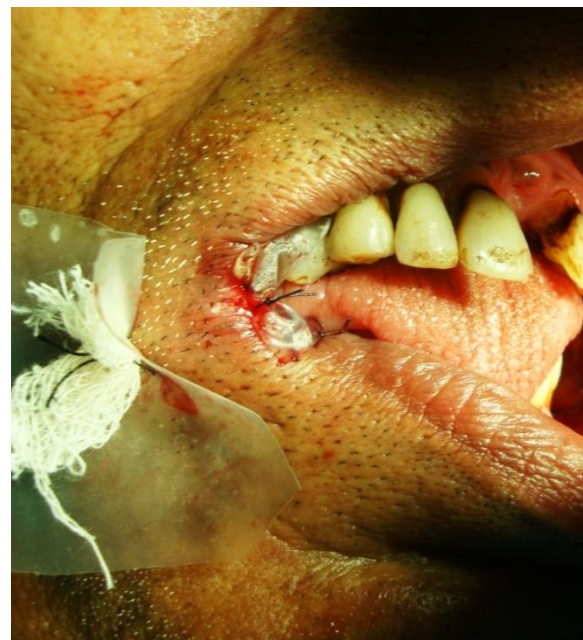A



B



C



D

Table/ Figure 2 A The raw wound after surgical excision of buccal mucosa lesion. B: Adaptation of the skin graft to the surgical defect. C: The silicone sheets placed intraorally over the skin graft in gingivo-buccal sulcus. D: Silicone sheet placed extraorally over the cheek opposing the intra oral plate secured by Trans -buccal sutures

Mouth opening

All the 9 patients had a mean mouth opening of 3.978 cms, which improved with each post operative day and was near normal 5.089 cms by the 10th post operative day. The [Table/ Figure 3] shows a mean of increase in amount of mouth opening with each post operative day though with a little less significant p value, reason to which may find an answer due to a less sample size.

Graft size

The split thickness skin graft significantly decreased in size with each post operative day in both dimensions of height and width of the graft.

Most of the skin graft turned into slough by 7th post operative day as silicone sheet gave a less than expected complete water tight closure to the graft. After 7 days most of the skin graft turned into slough and only 50% of the grafted skin remained. By the end of 7th post operative day silicone sheet was removed and after which the skin graft further underwent lysis thus resulting in a significantly very less skin graft remaining to take up in the raw area. The raw surface with remaining skin graft induced granulation tissue and helped in promoting rapid epithelialization. By the 10th post-operative day the skin graft further sloughed up and reduced in size. [Table/ Figure 4] depicts that how the mean intra operative graft size height of 3.056 cms reduced up to 1.056 cms by the 10th post -

Sandwich Silicone Technique For Securing Intra-Oral Skin Grafts to the Buccal Mucosa Defects

operative day and [Table /Figure 5] shows how the mean intra operative graft size width of 2.833 cms shrunk up to 1.056 cms by the 10th post-operative day.

sheet was removed, the raw surface with remaining skin graft induced granulation tissue and helped in promoting rapid epithelialization, thus leading to a good healing of the soft

Table/ Figure 3 Mean mouth opening from pre-operative to 10th day post operative day

Pair of mean preoperative mouth opening with mean post operative mouth opening on each post operative day	Post Operative Days	Mean mouth opening pre operatively and mean mouth opening on each post operative day (in cms)	Standard Deviation	t	p value
PAIR 1	Pre-operative	3.978	1.7123	1.233	0.253
	1 st Post operative day	3.244	0.8141		
PAIR 2	Pre-operative	3.978	1.7123	0.420	0.686
	3 rd Post operative day	3.733	0.6205		
PAIR 3	Pre-operative	3.978	1.7123	-0.223	0.829
	5 th Post operative day	4.100	0.5408		
PAIR 4	Pre-operative	3.978	1.7123	-1.275	0.238
	7 th Post operative day	4.644	0.4333		
PAIR 5	Pre-operative	3.978	1.7123	-2.068	0.072
	10 th Post operative day	5.089	0.2667		

Table/Figure 4 Mean graft size height from intra operative to 10th post operative day

Pair of mean intra operative graft size height with mean post operative graft size height on each post operative day	Post Operative Days	Mean graft size height intra operatively and mean graft size height on each post operative day (in cms)	Standard Deviation	t	p value
PAIR 1	Intra -operative	3.056	0.3005	7.650	<0.0005
	1 st Post operative day	2.533	0.3674		
PAIR 2	Intra -operative	3.056	0.3005	8.222	<0.0005
	3 rd Post operative day	2.333	0.3536		
PAIR 3	Intra -operative	3.056	0.3005	13.493	<0.0005
	5 th Post operative day	1.967	0.4000		
PAIR 4	Intra -operative	3.056	0.3005	16.000	<0.0005
	7 th Post operative day	1.722	0.4410		
PAIR 5	Intra -operative	3.056	0.3005	13.856	<0.0005
	10 th Post operative day	1.056	0.5270		

Table/Figure 5 Mean graft size width from intra operative to 10th post operative day

Pair of mean intra operative graft size width with mean post operative graft size width on each post operative day	Post Operative Days	Mean graft size width intra operatively and mean graft size width on each post operative day (in cms)	Standard Deviation	t	p value
PAIR 1	Intra -operative	2.833	0.4330	2.828	0.022
	1 st Post operative day	2.500	0.5590		
PAIR 2	Intra -operative	2.833	0.4330	8.222	<0.0005
	3 rd Post operative day	2.111	0.4859		
PAIR 3	Intra -operative	2.833	0.4330	12.095	<0.0005
	5 th Post operative day	1.944	0.3909		
PAIR 4	Intra -operative	2.833	0.4330	11.314	<0.0005
	7 th Post operative day	1.500	0.5000		
PAIR 5	Intra -operative	2.833	0.4330	10.522	<0.0005
	10 th Post operative day	1.506	0.5270		

Capillary test

The silicone sheet though remained moist and supple intraorally, but it couldn't remain in close contact with the underlying skin graft. Its efficacy as a mechanical barrier to stabilize the skin graft was less than expected, as it gave an uneven capillary test. The silicone sheet got dislodged from periphery as the sutures started cutting through the sheet and the silicone sheet started to bunch up in mouth.

Healing of the graft and surgical raw area:

Healing of the excised area, according to Landry Turnbull & Howley Index started on note of a poor tissue healing with less of granulation tissue and bleeding from the raw area. With each post operative day, especially after the silicone

tissue. The tissue was clinically healthy in a week and it was covered by a thin epithelial layer. The granulation tissue was healthy and there was little evidence of scar contracture at the end of 10 days. [Table/Figure 6] & [Table/ Figure 7] depict the significant healing of the recipient site according to Landry Turnbull & Howley Index.

DISCUSSION

The surgical defects of buccal mucosa, like any other raw wound, heals by secondary intention with episodes of granulation and epithelialization, thus causing scarring and contraction, which in turn leads to decreased mouth opening. The risk of infection in oral cavity is quite high due to moist environment compounded by saliva and food which invites microbial contamination.

Table/ Figure 6 Healing of the wound by Landry, Turnbull and Howley index

Type of score	1st day post op	3rd day post op	5th day post op	7th day post op	10th day post op
Median score	2.00	2.00	2.00	3.00	3.00
Inter Quartile Range	1.00	2	2	1	0.50

Table/ Figure 7 Wilcoxon Signed Rank Test for healing at the recipient site

Type of test	3rd day post op - 1st day post op	5th day post op - 1st day post op	7th day post op - 1st day post op	10th day post op - 1st day post op
Z	-1.633	-1.890	-2.714	-2.598
P	.102	.059	.007	.009

It has been well documented by Rastogi S that the chances of contraction and infection is decreased if a wound is dressed rather than left raw, and their study also demonstrated that a good dressing creates a physiological barrier between raw wound surface and the moist oral environment leading to uneventful healing [16]. Split thickness skin graft is most favorable as a dressing in intra oral surgical defects as it curtails infection, prevents hematoma if pie crusted, hastens granulation tissue formation, fastens re-epithelialization, decreases wound contracture and reduces donor site morbidity [17].

Appropriate approximation of the skin graft to the surgical defect and an adequate pressure dressing or a stent which could effectively hold the skin graft until it is taken up is still a matter of quest for surgeons. A plethora of literature is available suggestive of many stents and various techniques to adapt skin graft intra orally. Earlier in 1975, Goshgarian and Miller used a parachute stent technique to secure intraoral skin grafts with trans-cutaneous sutures [18]. Later in 1981, Friedlander and Miller used eye patches and a denture soft liner, to secure the skin graft to the cheek using trans-buccal bolster sutures [3]. Soh and Muthusekhar used split thickness skin grafts and polyethylene stent in 15 patients with oral submucous fibrosis in their study in 2015 and showed excellent graft uptake along with increased mouth opening [19].

Schramm and Myers gave the traditional tie over bolster technique over the skin graft with non absorbable sutures and they also suggested the sandwich technique by an extra orally fixed bolster along with intra oral one for anchorage but they reported bad scarring of the cheek [20]. In a similar study of applying sandwich technique, Salins P and Naganur DV used stents made of dental liner to secure skin graft intra orally and reported good graft uptake with uneventful wound healing and increased mouth opening [21]. Another study with sandwich technique was by Lai S *et al* in 2008 where they used eye patches in a sandwich manner similar to our study to secure intra oral skin graft and proposed it as a better technique for added anchorage by the extra oral stent [22].

Since the beginning of 19th century, silicone sheet is being used as a most promising newer material in many of biological and surgical procedures. It has shown successful results in many surgical procedures to cover the mucosal defects and also as an effective stent to hold the split thickness skin graft. In 1998, Gorgu M *et al* used silicone sheets on 27 patients as a stent to secure skin grafts and

showed favorable results and adequate efficacy of silicone sheets as biocompatible stents [23]. Silicone sheets have been successfully used as an effective stent to secure skin grafts in treatment of diskectomy [12], mastoidectomy [13], and for treatment of keloids [14].

In a similar study by Sawada Y in 1988, sandwich silicone technique was used to secure skin grafts on eyelids and in contrary to our study, he showed an even capillary test and water tight closure which resulted in proper graft uptake [24]. But in all such previous studies the silicone sheet was applied to an immobilized area which resulted in proper adaptation of the silicone sheet, and thus giving favorable results. The only reported study with sandwich technique using silicone sheets intra orally was done by Robiony M *et al* in 2007 which showed good apposition of the graft to exposed soft tissues and depicted a better result than our present study [25]. It showed an even capillary test and better graft uptake which was contrary to our study. Improvement in mouth opening was noticed in both their and our studies post operatively.

Limitations and suggestions for future studies

The only study in literature using intra oral sandwich silicone technique by Robiony M *et al* could not be a better guide to our research as the thickness of silicone sheet was not mentioned by them and also the proper adaptation of silicone sheets was not well highlighted thus leading to lack of much literature support to use the silicone sheet intra orally in present study. In our view mobilization and improper adherence of the graft to the defect due to constant mobility of cheek could be one of the major problems causing the skin graft and the stent to get dislocated from the recipient bed, thus causing the graft failure. So to prevent it, we suggest that the cheek should be kept stretched by keeping the mouth open for first 5-7 days post-operatively either by keeping an acrylic bite block or thick gauge bolus covered with softrautal pack so that the immobilized cheek could give chance for the graft to adapt to the defect. Adding to the failure salivary secretions tend to accumulate beneath the grafts which separate it from its bed. This phenomenon mixed with constant cheek mobility leads to complete dislodgment of the graft from its bed and initial take up of the graft is hindered.

One more important cause which could have caused failure of skin graft uptake in present study could be the thinness and flexibility of silicone sheet. Silicone sheet used in this study was non-reinforced (.005 inch), 150x200mm which was not of suitable strength to hold the skin graft and provide a water tight closure. Hence we suggest using a thicker silicone sheet which has bulk and strength to give support and water tight closure to the skin graft. Though the silicone sheet was well sutured to the skin graft and cheek both in centre and periphery, we also suggest to give some quilting sutures or running sutures at the periphery to provide a better closure and adaptation of silicone sheet.

However, due to the limited sample size and follow-up period of this study, it is difficult to ascertain on the efficacy of silicone sheet on skin graft for intraoral use, as a graft stabilizer. Hence, larger sample sizes with longer follow up periods are mandatory to authenticate the clinical application of silicone sheet on skin graft.

CONCLUSION

In this study of short duration and a smaller sample size, the nature of silicone sheet as a stent on split thickness skin graft was observed and was found to be less promising as an alternative to the other graft stabilizing materials available. So the recommendation to use non-reinforced (.005 inch), 150x200mm silicone sheet as an stent for intra oral skin graft in a sandwich technique stands doubtful due to the results observed in 9 patients. Further study can be done with thicker silicone sheet and proper adaptation of same intra-orally by quilting the sheet properly to the skin graft and cheek mucosa and keeping the cheek immobilized.

References

1. Queraishi S, Chaukar D, D'cruz A.K. Simple technique to secure intra-oral skin graft. *Journal of Surgical Oncology*. Vol 89, Issue 2 ,Feb 2005,102-103.
2. Artopoulou I.I., Lemon JC, Clayman GL, Chambers MS. Stent fabrication for graft immobilization following wide surgical excision of myofibroblastic sarcoma of buccal mucosa: A clinical study; *J Prosthet Dent* 2006; 95:280-5
3. Friedlander AH, Miller J. Stabilization of intraoral skin grafts to the cheek. *J Oral Surg* 1981; 39:63.
4. Jundt JS, Odom KW, Wilson JW. Intraoral split-thickness skin grafts: A new approach using vinyl polysiloxane. *J Oral Maxillofac Surg* 2011; 69:1255-7.
5. Pravinkumar G. Patil, Rambhau D. Parkhedkar. New graft-stabilizing clip as a treatment adjunct for oral sub mucous fibrosis. *J Prosthet Dent*. 2009; 102:191-192.
6. De Gado *et al*. Skin grafting: comparative evaluation of two dressing techniques in selected body areas, in vivo 22: 503-508 (2008).
7. S M Balaji, C. J. Venkatakrishnan. Modified Graft-Stent Vestibuloplasty Approach for Rehabilitation of Loss of Sulcus. *J Maxillofac Oral Surg*. 2010 Jun; 9(2): 155-158.
8. Eppley, Barry L. A Dynamic Method for Stabilizing Intraoral Skin Grafts That Is Simple, Inexpensive, and Effective. *Journal of Craniofacial Surgery*: January 2004 - Volume 15 - Issue 1 - p 22.
9. Huang IY, Wu CF, Shen YS, Yang CF, ShiehTY, Hsu HJ, *et al*. Importance of patient's cooperation in surgical treatment for oral sub mucous fibrosis. *J Oral Maxillofac Surg* 2008; 66:699-703.
10. Y. Sawada, T. Suzuki, I. Hatayama, K. Sone. Silicone gel including antimicrobial agent. *British journal of Plastic Surgery* (1990), 43, 78-82.
11. Bale D, Temporary wound covering with silicone sheet for the soft tissue defect following open fasciotomy , *j cardiovasc surg* , 1998;vol 39 ,587-91.
12. Schliephake H, Long term results of use of silicone sheets after diskectomy in TMJ; *Int J Oral Maxillofac Surg*, 1999; vol 28,323-329.
13. Kyosuke K, Effect of large size silicone sheet upon recovery of mastoid aeration after mastoidectomy, *American academy of otolaryngology*, May 2008; vol 32, 22-30.
14. Takaki S, Effect of silicone sheet on stratum corneum hydration and as a treatment of keloids, *British j of plastic surg*, vol23;234-236, 2008
15. Landry RG, Turnbull RS, Howley T. Effectiveness of benzydamine HCL in treatment of periodontal post surgical patients. *Res Clinic Forums*, 1988; 10: 105-118.
16. Rastogi S, Modi M, Sathian B. The efficacy of collagen membrane as a biodegradable wound dressing material for surgical defects. *Journal of Oral and Maxillofacial Surgery*. 2009; 67:1600-06.
17. Izumi K, Feinberg SE. Skin and Oral Mucosal Substitutes. *Oral Maxillofacial Surg Clin N Am*. 2002; 14:61-71.
18. Goshgarian G, Miller TA. The "parachute" stent. *Am J Surg* 1975; 130: 370.
19. Soh CL, Muthusekhar MR. Treatment of oral submucous fibrosis using split skin graft and a polyethylene stent: a prospective study. *J Maxillofac Oral Surg* 2015; 14:370-3.
20. Schramm VL, Myers EN. Skin grafts in oral cavity reconstruction. *Arch Otolaryngol* 1980; 106: 528-32.
21. Salins P, Nagnur DV. Fixation of skin grafts to the cheek: the sandwich technique. *J Oral Maxillofac Surg* 1996 Aug; 54(8): 1034-5.
22. Lai S, Shen YS, Yang CF, Huang IY, Chen CM. Eye patch sandwich technique for stabilizing the intra oral skin graft to the cheek. *J Craniofac Surg* 2008 Nov; 19(6): 1641-2.
23. Gorgu M, Erdogan B, Akoz T, Kargi E, Deren O, Aslan G. Silicone gel sheetings for stabilization of skin grafts. *Dermatol Surg*. 1998 Oct; 24(10):1073-6.
24. Y. Sawada. Silicone gel sheet tie over for skin graft on the eyelid following release of scar contracture. *British Journal of Plastic Surgery* (1988), Vol 41; 325-326.
25. Robiony M, Forte M, Toro C, Costa F, Politi M. Silicone sandwich technique for securing intraoral skin grafts to the cheek. *Br J Oral Maxillofac Surg* 2007 Mar; 25;45(2): 166-7

How to cite this article:

Priyankar Singh *et al* (2017) 'Sandwich Silicone Technique For Securing Intra-Oral Skin Grafts to the Buccal Mucosa Defects', *International Journal of Current Advanced Research*, 06(10), pp. 6491-6496.
DOI: <http://dx.doi.org/10.24327/ijcar.2017.6496.0953>
