

RETINATED CANINES 13 AND 23, SKELETAL AND DENTAL CLASS 1 IN 17-YEAR-OLD MALE, TREATED WITH MINIMAL INVASIVE ORTHODONTIC AND IMPLANT THERAPY

Anton Plattner*

Private Practice in Brixen / South Tyrol, Brixen, Italy

ARTICLE INFO

Article History:

Received 5th July, 2017

Received in revised form 19th

August, 2017 Accepted 25th September, 2017

Published online 28th October, 2017

Key words:

Retinated canines 13 and 24 in 17-year-old male treated with only niti wires with elastics by PSL brackets multitorque (Damon system) and mini-implant.

ABSTRACT

Introduction: Treatment of patient with retinated canines 13 and 23, skeletal and dental class 1 can be effectively treated with only niti wires by using PSL multi torque brackets, early elastics and mini-implant. Patient would like to correct retinated canines 13 and 23 and straighten teeth.

Objective: 17-year-old male patient (Fig. 1) with straight profile; dental and skeletal class 1, retinated canines 13 and 23 (Fig. 2); treatment lateral adaption in upper arch with only niti wires and initial 2 once elastics using the Damon system.

Material and methods: The treatment was started with multi torque Damon Q brackets upper and lower fixed appliance.

Lateral cephalometric and panoramic radiographs were taken at the beginning. (Fig. 3, 4) The patient was followed for 2 years to document the stability of non-surgical orthodontic and non-maximal invasive expander treatment.

Result: Correction of the retinated canines 13 and 23. (Fig. 8, 9, 10, 11)

Copyright©2017 Anton Plattner. This is an open access article distributed under the Creative Commons Attribution License, which permits unrestricted use, distribution, and reproduction in any medium, provided the original work is properly cited.

INTRODUCTION

Treatment plan

1. PSL multi torque brackets Damon Q brackets:
2. 17-47 standard torque (Fig. 7) Bonding upper and lower smile arc (more gingival), disarticulation 11, 21, 36 and 46, initial elastics 2 once class 2,
3. 0.13 cuniti wire upper and lower for 10 weeks (Fig. 5)
4. Surgically uncover 13 to attach button for regulation and fixed with chain to a mini-implant (located between 15 and 16) to retract 13 from 12
5. 0.16 cuniti wire upper and lower elastics, class 2.
6. 0.14x25 cuniti wire upper and lower elastics 3.5 once right and left. (Fig.6)
7. Take panoramic x-rays and change the position of the brackets.
8. 0.18x25 cuniti upper and lower and finish that case.
9. Retention: Upper: plastic retainer for 6 months 24h, and at night and fixed retainer 15-23. Lower: bonded retainer 33-43 (Hilgers Bond.A.Braid, Reliance Orthodontic roducts).
10. Estimated treatment time: 18-22 months (Fig. 12, 13)



Figure 1 Pre-treatment extra-oral photographs

*Corresponding author: Anton Plattner

Private Practice in Brixen / South Tyrol, Brixen, Italy

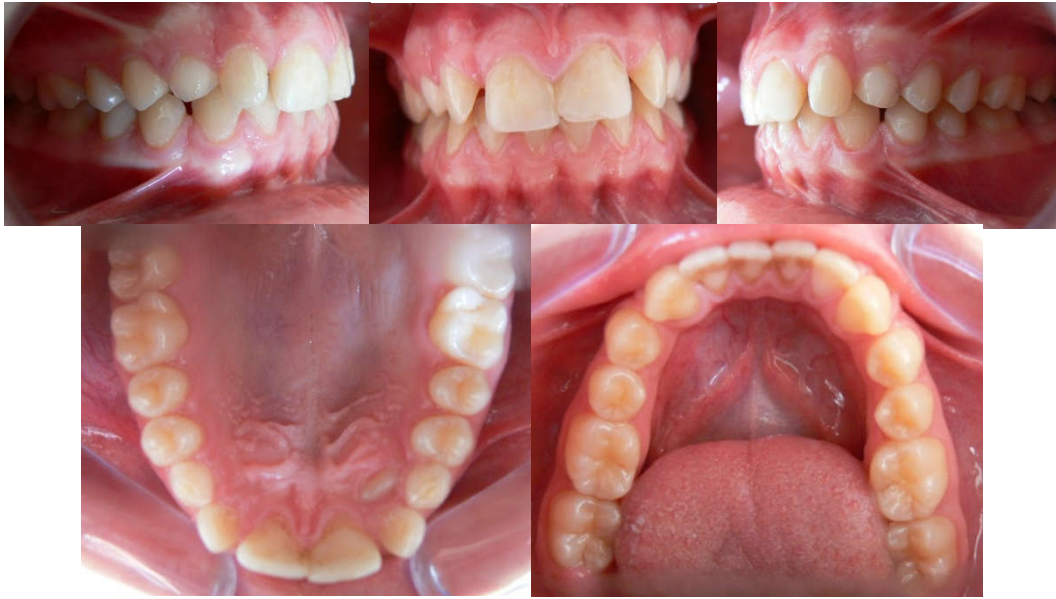

Figure 2 Pre-treatment intra-oral photographs

Start

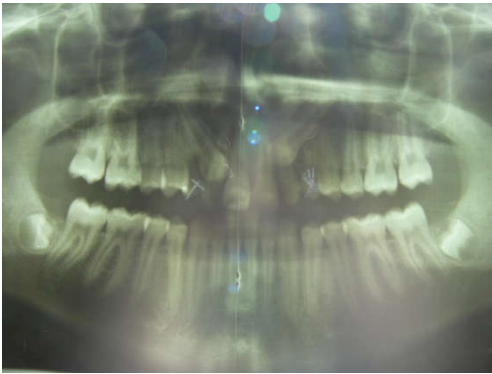


Figure 3 Pre-treatment OPT

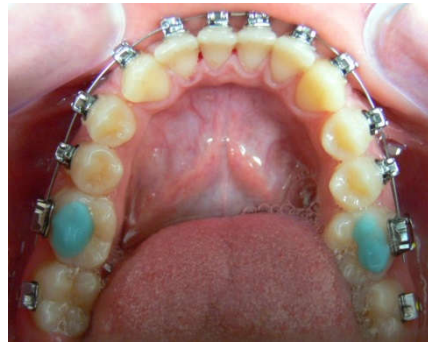

Figure 5 Start month 0: 0.13 cuniti upper and lower, bonding smile arc (more gingival)

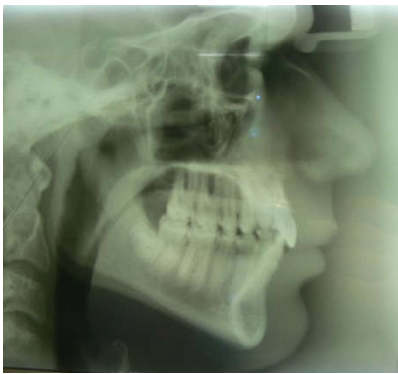


Figure 4 Pre-treatment CEPH

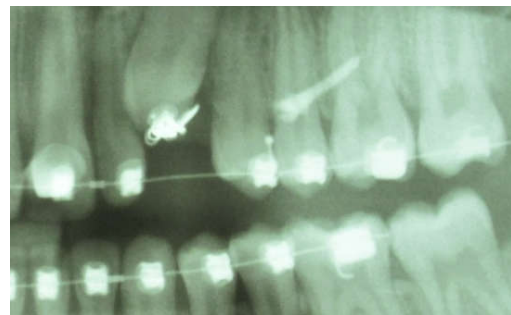
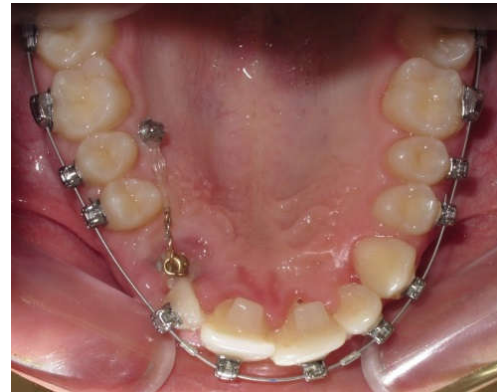

Figure 6 Month 12: 0.14x25 cuniti lower, 0.13 cuniti upper, elastics; 3.5 ounce (Dolphine) right and left

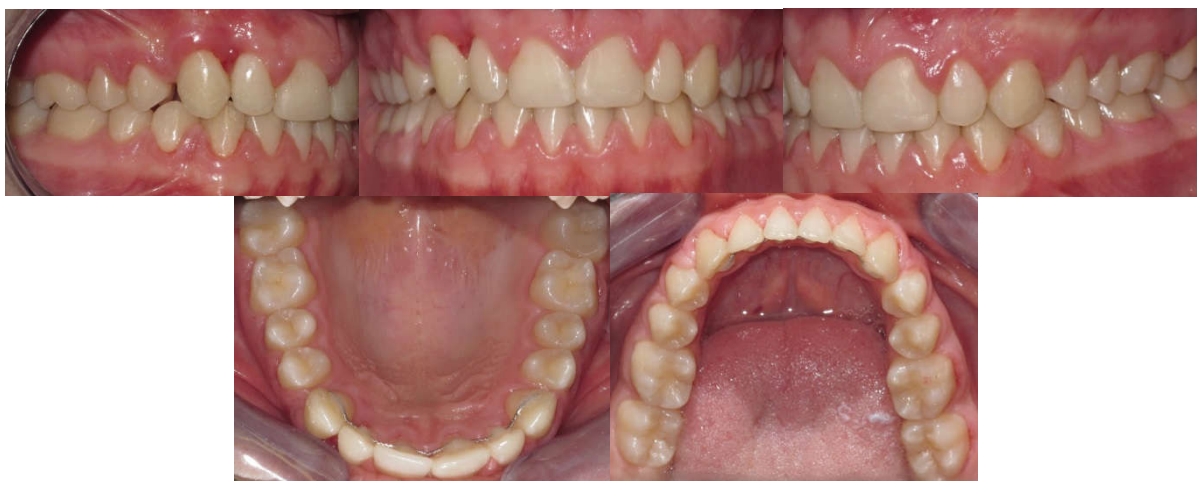

Figure 8 Finish month 20. Post-treatment intraoral photographs after debonding

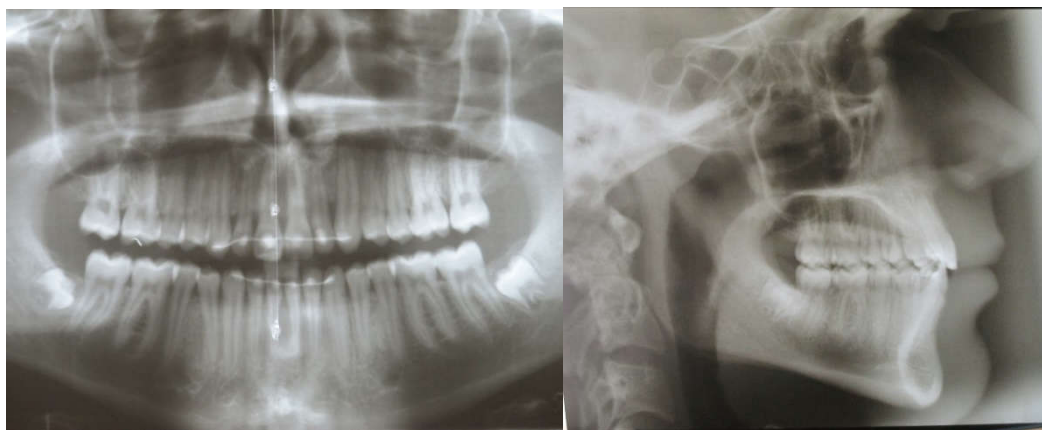


Figure 12 Intraoral photos, after 7 months follow up; patient showed class 1 occlusion; resulting mandibular and maxillar position and an improved balanced profile

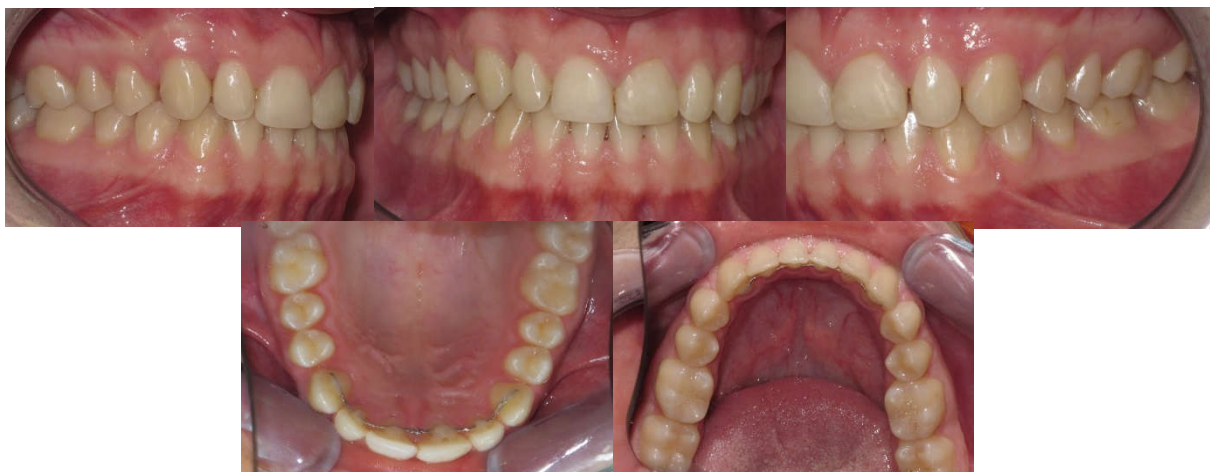

Figure 13 Intraoral photos, after 2 years follow up; patient showed class 1 occlusion; resulting mandibular and maxillar position and an improved balanced profile

Adaptation Upper arch	before	after	difference
Adaptation 13-23:	34	36	+2
Adaptation 14-24:	43	45	+2
Adaptation 16-26:	50	51	+1

Adaptation lower arch:	before	after	difference
Adaptation 33-43:	27	28	+1
Adaptation 34-44:	36	36	0
Adaptation 36-46:	45	45	0

Cephalometric (Fig. 14, 15)

Diagnosis:	PRE-Tx	POST-Tx	DIFF.
	Skeletal class 1	Skeletal class 1	
	SNA 86	SNA 86	0
	SNB 83	SNB 83	0
	ANB 3	ANB 3	0
Skeletal analysis:			0
	Mandibular plane angle (FMA 27)	Mandibular plane angle (FMA 27)	
Dental analysis:	U1 to SN 103°	/	0
	L1 to MP 95°	/	0
Facial analysis:	E-line upper -3	/	0
	E-line lower -2	/	0

DISCUSSION

This 17-year-old patient with skeletal and dental class 1 and retinated canine 13 and 23 is an example of minimal invasive orthodontic and implanttherapy.

Let me demonstrate the simple plan

HG, Loops, TPA, RPE, mini implants, pendulum, ss wires, 8 bands, distalisation are *not necessary!*

Necessary are only passive self ligating brackets (PSL), buildups and niti wires, initial elasticsand mini-implant for retraction of the retinated canines.

CONCLUSION

The patient's compliance remains one of the main factors for a successful outcome. PSL brackets multitorque and niti wires, buildups and the biology of the bone is the key for success.

The wire used: 0.13 cuniti for 10 weeks, then 0.16 cuniti for 10 weeks, 0.14x25 cuniti for 10 weeks and 0.18x 25 cuniti to finish the case.

Correct bonding is very necessary (bonding smile arch: more gingival!).

The result is a happy smile and no buccal corridors.

References

1. Kotzlowky. Honig Damon system mechanics for the ultimate in efficiency and excellence clin Impressions 2008; 16:23-28
2. T. Pitts: begin with the end in mind: bracket placement and early elastics protocols for smile arc protection. *Clin impressions* 2009 17: 4-13
3. Huang S. Dr Tom Pitts's secrets of excellent finishing (2) News and trends in orthodontics 2009 14; 6-23
4. Profit WR, Fields Jr. HW, sarver DM. contemporary orthodontics, 4th ed. ST. Louis: Mosby Elsevier, 2007
5. Chang CH, Roberts WE. Objective assessment of orthodontics clinical outcomes www.iaoi.pro
6. Chang CH. The 2B-3D rule for implant planning, placement and restoration. *Int. J Ortho Implantol* 2012; 27:96-101
7. Lin JJ. Creative Orthodontics Blending the Damon System and Tad's to manage difficult malocclusions 2. Ed Taipei: Jung Chiech; 2010 p.171-186
8. Damon Dwight: The Workbook: Damon Principles, Examples of Interarch Elastics (Damonssystem.com)
9. Chapter 18: treatment of the face with biocompatible Orthodontics (Dwight H. Damon)
10. Graber: vanarsdell.vig (fourth Edition): Orthodontics: current Principles and Technignues
11. Langlade M. Optimization of orthodontic elastics. New York: GAC International; 2000.

How to cite this article:

Anton Plattner (2017) 'Retinated Canines 13 And 23, Skeletal And Dental Class 1in 17-Year-Old Male, Treated With Minimal Invasive Orthodontic And Implant Therapy', *International Journal of Current Advanced Research*, 06(10), pp. 6438-6441. DOI: <http://dx.doi.org/10.24327/ijcar.2017.6441.0943>
