

CASE REPORTING ON HYDROCELE OF CANAL OF NUCK

Kalpesh Chaudhari and Amit Kawale

3/12 old air India colony, Kalina, Santacruz East, India

ARTICLE INFO

Article History:

Received 19th June, 2017

Received in revised form 3rd

July, 2017 Accepted 18th August, 2017

Published online 28th September, 2017

ABSTRACT

The hydrocele of the canal of Nuck is quite a rare condition and results from the failure of obliteration of the distal portion of evaginated parietal peritoneum within the inguinal canal which forms a sac containing fluid. It generally presents with painless inguinal swelling. Ultrasonography plays an important role to differentiate from the other conditions presenting with inguinal swelling. We present the case of 40 year female with hydrocele of canal of nuck.

Key words:

Hydrocele of canal of Nuck, ultrasound

Copyright©2017 Kalpesh Chaudhari and Amit Kawale. This is an open access article distributed under the Creative Commons Attribution License, which permits unrestricted use, distribution, and reproduction in any medium, provided the original work is properly cited.

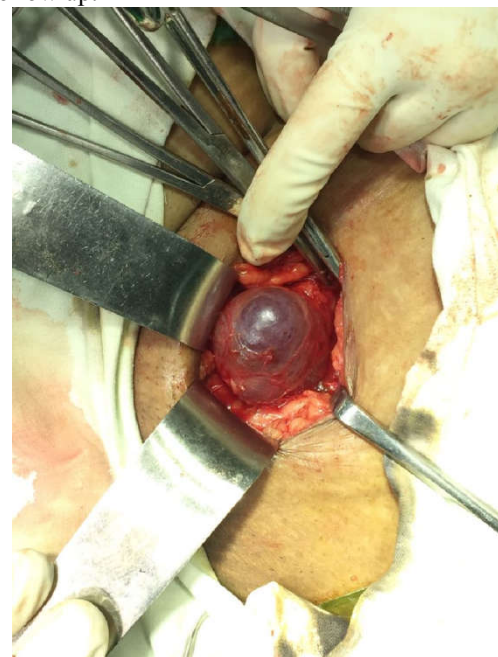
INTRODUCTION

The Hydrocele of canal of Nuck is a small evagination or finger-like protrusion of parietal peritoneum that accompanies the round ligament through the inguinal ring [1]. During the first year of life this protrusion typically obliterates completely, however, if there is limited proximal obliteration, it fills with fluid and forms a hydrocele [2,3,4] or indirect inguinal hernia [3].

CASE REPORT

40 year-old female presented with complaint of pain and swelling in her right inguinal region since 1 yrs. Swelling was insidious in onset, with a slight increase in the size of the swelling since its occurrence. There was no history of vomiting, bowel and bladder dysfunction. On examination, an oval, approximately 3cmx3cm in size, tender and cystic swelling was present in the right inguinal region. Transillumination test was negative. There was no expansible cough impulse, peristaltic activity or abnormal vascularity-associated with the swelling. Signs of inflammation were absent. Lymph nodal examination was normal. Ultrasonography revealed with well-defined 5.3*4.4*2.7 cms cystic swelling in subcutaneous tissue of the right inguinal region- likely to represent a cyst of canal of nuck/lymphangioma. Within the inguinal canal measuring 3x2cm. Patient underwent surgery. Round ligament was identified along with the hydrocele of the canal of Nuck. Cyst of canal of Nuck was separated from the round ligament and

excision of the cyst of canal of Nuck was carried out. Post-operative period was uneventful and patient recovered satisfactorily. Histopathologic examination confirmed it as Hydrocoele of canal of Nuck. Patient is asymptomatic on follow up.



DISCUSSION

There are three types of a hydrocele of canal of Nuck. The most common type is one with no communication with peritoneal cavity forming an encysted hydrocele along the tract of descent, from the inguinal ring to the vulva. Second

*Corresponding author: **Kalpesh Chaudhari**

3/12 old air India colony, Kalina, Santacruz East, India

type results when there is a persistent communication with the peritoneal cavity. A third type is a combination of the two as a result of the inguinal ring constricting the hydrocele like a belt so that part is communicating and part is enclosed, giving this the name of hour glass type. However, any of these types of hydroceles are extremely rare in females.[5] Over secretion or the under absorption of the peritoneal fluid by the secretory lining of the processus vaginalis may lead to the formation of the cystic swelling. The aetiological factors responsible for such cystic swelling are mostly idiopathic and other causes are inflammation, trauma, impairment of lymphatic drainage and meconium hydrocele.(6) The usual differential diagnosis of inguino-labial swelling in a female patients are indirect inguinal hernia or femoral hernia; buboes; Bartholin's cyst; post-traumatic hematoma; hydrocele of canal of nuck; lipoma; vascular aneurysms and rarely cystic lymphangioma, neuroblastoma metastasis in groin; ganglion; leiomyoma; sarcoma; endometriosis of round ligament or epidermal cyst [7,8].

CONCLUSIONS

This report may assist surgeons in providing the patient with an accurate clinical diagnosis and appropriate surgical intervention

References

1. Caviezel A, Montet X, Schwartz J, *et al.* Female hydrocele: the cyst of Nuck. *Urol Int* 2009; 82:242e5.
2. Khanna PC, Ponsky T, Zagol B, *et al.* Sonographic appearance of canal of Nuck hydrocele. *Pediatr Radiol* 2007; 37:603e6.
3. Anderson CC, Broadie TA, Mackey JE, *et al.* Hydrocele of the canal of Nuck: ultrasound appearance. *Am Surg* 1995; 61: 959e61.
4. Miklos JR, Karram MM, Silver E, *et al.* Ultrasound and hookwire needle placement for localization of a hydrocele of the canal of Nuck. *Obstet Gynecol* 1995; 85:884e6.
5. Counseller VS, Black BM. Hydrocele of the Canal of Nuck: Report of Seventeen Cases. *Ann Surg* 1941; 113:625-30.
6. Stickel WH, Manner M. Female hydrocele (cyst of the canal of nuck) sonographic appearance of rare and little-known disorder. *J Ultrasound Med* 2004; 23:429-432.
7. Poenaru D, Jacobs DA, Kamal I. Unusual findings in the inguinal canal: A report [12] of four cases. *Pediatr Surg Int.* 1999; 15:515-16.
8. Pandit SK, Rattan KN, Budhiraja S, Solanki RS. Cystic lymphangioma with [13] special reference to rare sites. *Indian J Pediatr.* 2000; 67:339-41.

How to cite this article:

Kalpesh Chaudhari and Amit Kawale (2017) 'Case Reporting on Hydrocele of Canal of Nuck', *International Journal of Current Advanced Research*, 06(09), pp. 6217-6218. DOI: <http://dx.doi.org/10.24327/ijcar.2017.6218.0896>
