

COMPLEX ODONTOME OF IMPACTED MAXILLARY PERMANENT LATERAL INCISOR AND CANINE WITH CONGENITALLY MISSING CENTRAL INCISOR - A RARE CASE REPORT

Arul Pari M., Joyson Moses., Paavai Arul Pari., Vignesh K C and Jaiganesh I

Department of Pedodontics and Preventive Dentistry Thai Moogambigai Dental College and Hospital
Dr M G R Educational and Research Institute University Mugappair, Chennai - 600107

ARTICLE INFO

Article History:

Received 18th April, 2017

Received in revised form 14th May, 2017

Accepted 20th June, 2017

Published online 28th July, 2017

Key words:

Complex odontome, Impacted lateral incisor, Retained primary incisors, Delayed tooth eruption, Impacted canine, Congenitally missing central incisor.

ABSTRACT

Odontomas are considered to be most common odontogenic tumors of the oral cavity. Most of the odontomes are asymptomatic and are discovered during routine radiographic investigations. The exact etiology of odontomes is still not known. Generally, it may cause disturbance with the eruption of the teeth, most commonly delayed eruption or deflection. The purpose of this case report is to present and discuss the case of a nine year old child with complex odontome, obstructing the eruption of permanent maxillary right lateral incisor and canine with congenitally missing central incisor. Radiopaque calcified masses were revealed in the radiograph between the primary maxillary incisors and the masses were surgically removed to facilitate the eruption of the tooth.

Copyright©2017 **Arul Pari M et al.** This is an open access article distributed under the Creative Commons Attribution License, which permits unrestricted use, distribution, and reproduction in any medium, provided the original work is properly cited.

INTRODUCTION

Odontoma is a term coined by Paul Broca in 1867 and was employed as a generalized term that referred to all types of odontogenic tumors (1). He defined odontoma as “tumors formed by the overgrowth of transient or complete dental tissues” (2). These type of lesions mostly occur within the bone though instances where earlier literature reveals that it has been localized in the gingiva have also been reported (3). World Health Organisation (WHO) (2005) classified odontomas into two types : (a) Compound odontoma - which consist of miniature tooth - like denticles, (b) Complex odontoma - which consist of an irregular mass of hard and soft tissue (1,4). Based on their location, it is also classified into intraosseous and extraosseous odontomas (5).

Complex odontoma constitutes for 22-67% of all maxillary tumors (6) with higher prevalence in children and adolescents (7, 8). This type of odontogenic tumors can be found anywhere in the dental arches. The majority of odontomas which are located in the anterior region of the maxilla are compound, while the great majority of odontomas located in the posterior areas, especially in the mandible, are complex odontomas (9,10,11) The etiology of the odontoma is unknown (12).

***Corresponding author: Arul Pari M**

Department of Pedodontics and Preventive Dentistry Thai Moogambigai Dental College and Hospital
Dr M G R Educational and Research Institute University Mugappair, Chennai - 600107

However, it has been suggested that trauma and infection at the place of the lesion can offer ideal conditions for its appearance (12,13). Most number of odontomes are asymptomatic and seldom cause swelling, pain, suppuration, bony expansion and displacement of teeth (14, 15). These type of lesions are commonly small although, sporadically it can be larger than a tooth. Generally, in dental treatment odontomes are discovered through routine radiographic examination. Essentially, an odontome is a benign lesion, but often causes disturbances in the eruption of its associated permanent unerupted tooth or retained primary tooth (16, 17, 8). Significantly, all types of odontomas are encountered during the first two decades of life (8). The gender predilection is controversial as some authors report an equal distribution among both genders (18) while one group reported male predominance (19) whereas another group reported female predominance (20). The problems associated with odontomes are interference in the tooth eruption, slowing or preventing the process and causing an ectopic eruption in some cases (21-23). Few potential sequelae of reported cases of odontoma are displacement and malformation of neighboring teeth, diastema, anodontia, and the pressure exerted by odontoma can cause pain, devitalization, and dental resorption. Therefore, it is recommended that, if odontoma is detected, it should be removed surgically (24). This report discusses a case of unerupted right permanent maxillary lateral incisor and canine associated with congenitally missing central incisor due to presence of complex odontome in a young patient.

Case Report

A 9- year old female patient reported to the department of pedodontics and preventive dentistry, with a chief complaint of pain and unerupted permanent tooth in the upper front tooth region. Past family history was not relevant. General medical history was noncontributory and it was child's first dental visit. Extraoral examination showed no asymmetry and was within normal limits. Clinical intraoral examination revealed a mixed dentition with mild bony swelling measures of 1×1 cm in size, round in shape (Fig 1). The color was the same as that of the normal attached gingiva without normal stippling, and the surface was regular and smooth. Palpatory findings revealed non-tender, non-pulsatile swelling of bony hard consistency and fluctuancy and compressibility were absent in relation to unerupted right maxillary permanent central and lateral incisor with retained primary central and lateral incisor.

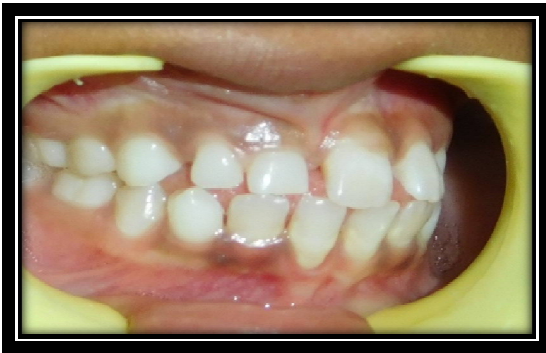

Fig 1 shows unerupted right maxillary permanent central incisor with a mild bony swelling in the labial region

Intraoral periapical, panoramic and occlusal radiographs (figure 2,3,4) revealed radiopaque structures were present obstructing the eruption of right maxillary permanent lateral incisor, canine and congenitally missing central incisor. Based on the clinical and radiographic findings, provisional diagnosis was made as complex odontome. Treatment planned was conservative surgical removal of the odontome in accordance with its size. Informed consent was obtained from the parent before starting the procedure.

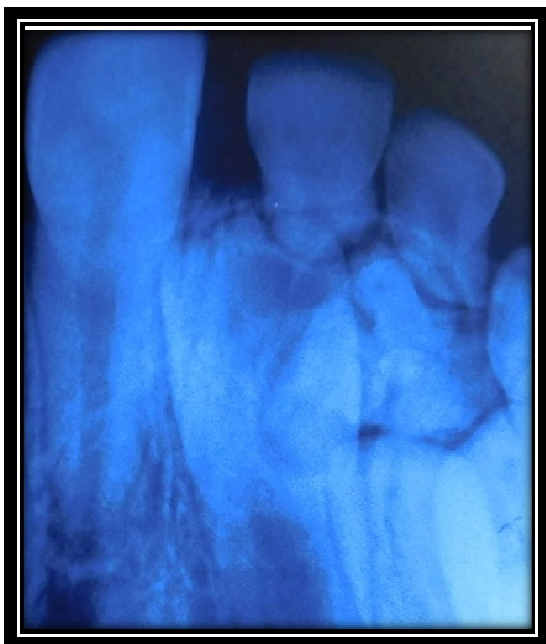

Figure 2

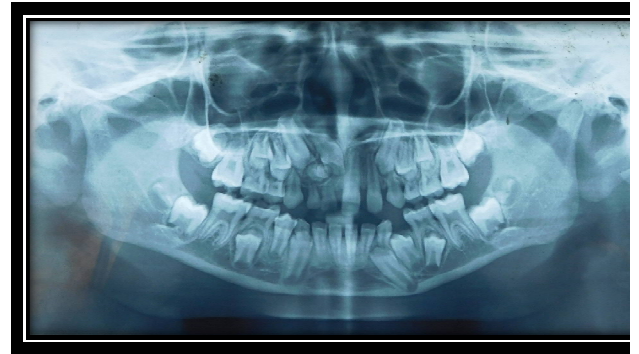


Figure 3

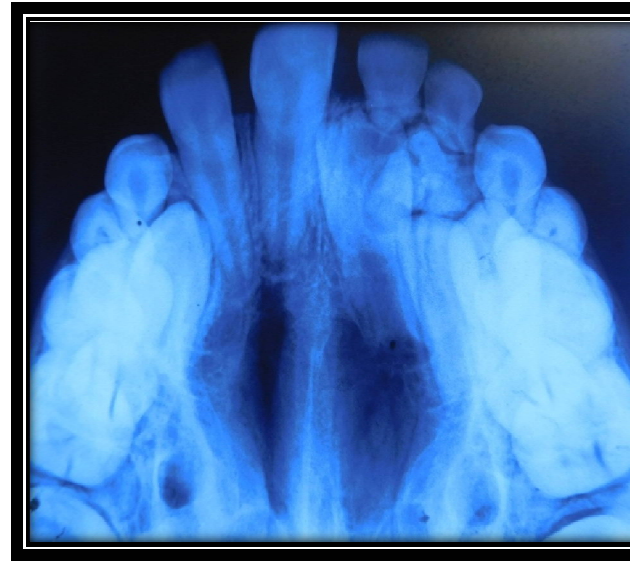


Fig 2,3,4 shows radiopaque structures obstructing the eruption of maxillary permanent lateral and congenitally missing central incisor

The patient was subjected to surgical removal of odontome under local anesthesia. Extraction of primary maxillary central and lateral incisor was done following which a full thickness mucoperiosteal flap was reflected from the labial surface of the right maxillary permanent central and lateral incisor. A layer of bone overlying the mass was removed. Then, calcified irregular masses were exposed and removed without disturbing the underlying permanent tooth bud (figure 5&6). The sample was sent for histopathological examination.

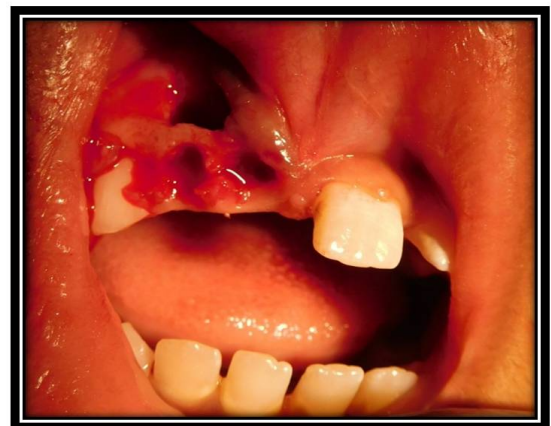

Fig 5 shows extraction of 51,52 done and odontome removed under local anesthesia and mucoperiosteal flap reflected in relation to 51,52

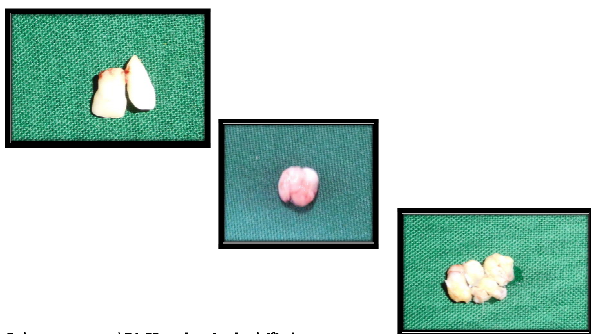


Fig 6 shows extracted 51,52 and excised calcified masses

Figure 6

Curettage was done and the area was irrigated with povidineiodine solution and normal saline (0.9%). Flap was repositioned and sutured (Fig 7). Immediate post operative intra oral periapical radiograph was taken and the absence of radiopaque masses in relation to the permanent maxillary lateral incisor and canine was confirmed to verify complete removal of the odontome (Fig 8).

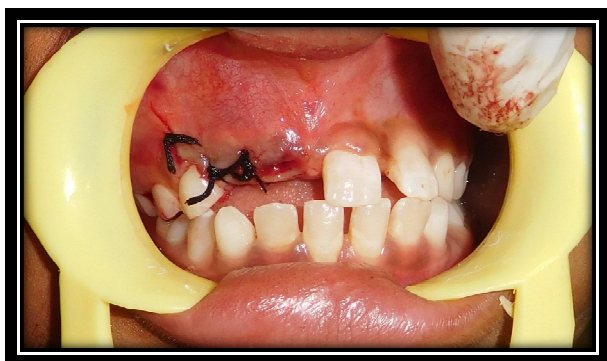

Fig 7 shows suturing done (After removal of odontome)

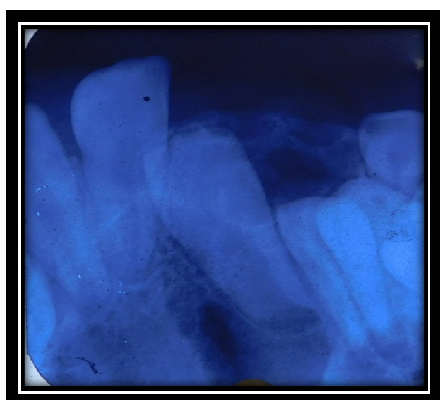


Fig 8 shows complete removal of odontome

Histopathologically, hard tissue section (figure 9) showed multiple bits of tissue exhibiting mature tubular dentin and dentin mass shows cleft - like spaces representing enamel which was removed during decalcification. Microscopically, hematoxylin and eosin-stained (H&E) section of soft tissue (figure 10) showed normal connective tissue exhibiting collagen fibers and foci of mild chronic inflammatory cell infiltrate.

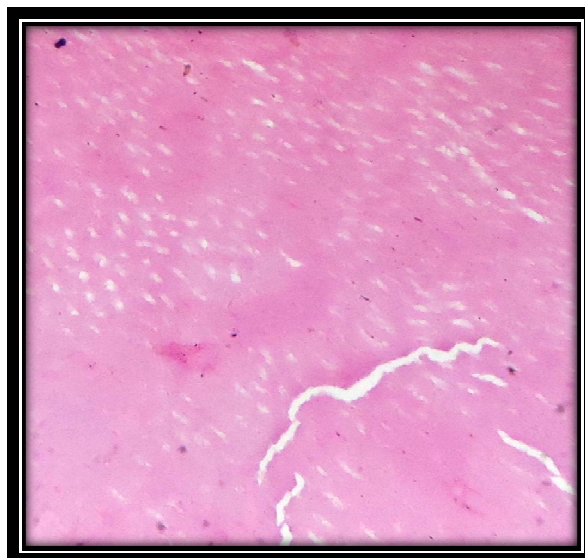


Fig 9 shows multiple bits of tissue exhibiting mature tubular dentin and dentin mass shows cleft-like spaces representing enamel which was removed during decalcification. (Hemotoxylin and Eosin, 20X)

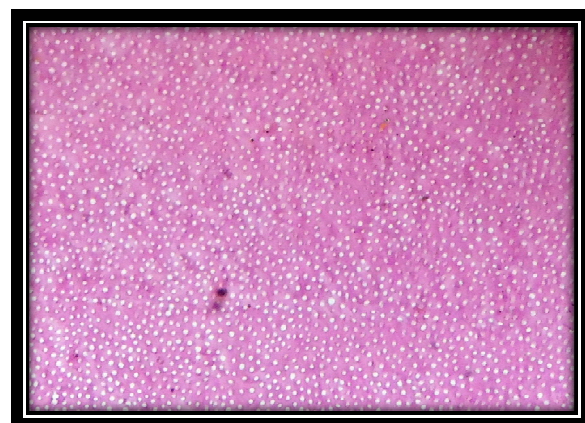


Fig 10 shows hematoxylin and eosin-stained (H&E) section of soft tissue showed normal connective tissue exhibiting collagen fibers and foci of mild chronic inflammatory cell infiltrate.

One week of post operative intraoral periapical radiograph revealed the absence of radiopaque masses confirming the successful removal of complex odontome which obstructed the eruption of right maxillary permanent lateral incisor (figure 11).

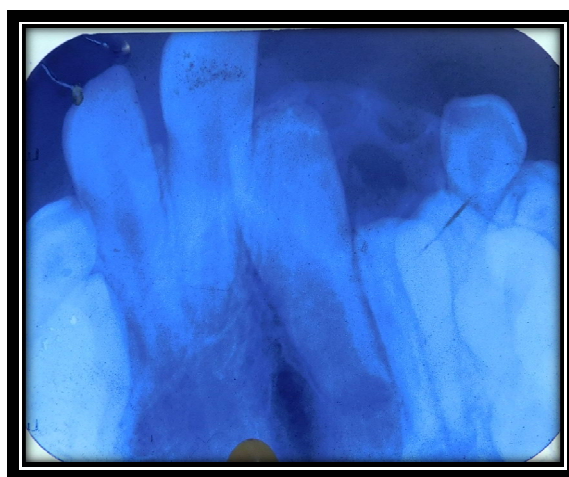


Fig 11 One week post operative view of intra oral periapical radiograph revealing the absence of radiopaque masses.

DISCUSSION

In clinical setting, dentists often encounter the problem of tooth impaction, which has been defined as a situation where a tooth fails to erupt into a normal functional position by the expected time.(25) Numerous local etiologic factors had been described for tooth impaction. It includes of odontomes, odontogenic tumors, ankylosis, trauma and dentigerous cysts.(26-28) Among these factors, odontoma is the most common etiological factor.(29)

The term 'odontoma' exactly means tumour of odontogenic origin, but it is used for a specific entity having epithelial and mesenchymal origin, with distinctive clinical and histological features.(30) From earlier literature, odontomas were considered as hard tissue tumours of odontogenic origin.(31) whereas now it is widely accepted that these represent hamartomatous malformations rather than a neoplasms.(30)

Erupted odontomas are rare entities and the types of odontomas, can be intraosseous or extraosseous, thus extending the list of types of odontomas. The exact etiology of this pathological entity is not known but it has been suggested that genetic basis, infections, inflammatory factors, trauma or even hyperactivity of odontoblasts may play a role in the development of odontomas.(32,33) Apart from these factors, it is the persistence of a part of dental lamina which has been thought to play a vital role in the development of odontomas.(4)

Majorly, reported cases of compound odontomes are found at the anterior region of the maxilla, whereas complex odontoms are found in the posterior region of mandible. (34,35) To the best of author's knowledge, this case report (Complex Odontome) is a rare one which occurred in the anterior region of the maxilla.

Ide *et al* (36) have supported this theory by assuming that the gingival rests of serre retain their capacity of epithelial-mesenchymal interactions which can lead to the formation of odontomas. Later, Pindborg (37) had suggested that occurrence rate of odontomas, if left untreated it can erupt into the oral cavity.

Total incidence rate of this pathology has been reported varying from 22% to 67% of all odontogenic neoplasms, and compound odontomas had been reported to be more common than the complex ones.(38,39) Earlier reports states that its incidence as a hamartoma were not found. The relative incidence of erupting odontomas is very low. As per the analysis performed by Cuesta *et al* (39), reported that odontomas have a predilection of occurring at maxillary incisor and canine region. In this current case, the affected site was the maxillary anterior region.

Hitchin suggested that odontomes are inherited or due to a mutagene or interference, possibly postnatal, with the genetic control of tooth development. (40) Mostly, the etiology of odontome result from extraneous odontogenic epithelial cells. When these buds are divided into several particles they may develop individually to become numerous, closely positioned malformed teeth or tooth-like structures. When the buds develop without such uncommon division and consists of haphazard conglomerates of dental tissues, they may develop into complex odontomes. However, the transition from one type to another is commonly associated with varying degrees

of morphodifferentiation or histodifferentiation or both, and it is often difficult to differentiate between both the types.(41) The management of odontomes (complex and compound) in both primary and permanent dentition is surgical removal. If odontomes are extirpated earlier without disturbing the underlying tooth germ, the eruption of the impacted teeth can then be expected spontaneously or after orthodontic traction. (14,25,26)

Sometimes, underlying impacted teeth may required extraction in association with the removal of odontome. (42) If the impacted tooth root is still developing, the tooth may erupt into the oral cavity normally (43). In this case, the complex odontomes were surgically removed and the impacted central incisor had been kept under observation to monitor its eruption during the follow ups.

Hisatomi *et al* (44) reported that, the impacted tooth tends to erupt regardless of the degree of root formation after extirpation of the odontoma interfering with tooth eruption, although some teeth showed infraversion and/or crowding. In this present case, root formation of the impacted incisor was not complete. Therefore, it is anticipated that impacted right maxillary permanent lateral incisor may erupt spontaneously. However, there are few reports about orthodontic therapy to bring the impacted permanent tooth to a satisfactory postoperative occlusion. If the eruption of the impacted tooth does not favourably occur within two to three months, orthodontic traction had to be done by using ligature wire hook on the bonded bracket. Still, if the tooth does not erupt, suspended ligature wire hook will be used for orthodontic traction with no necessity for repeated flap reflection.

CONCLUSION

Odontomas are commonly occurring benign entities, but rarely they erupt into the oral cavity. Evidence from the dental literature and clinical experience suggest that radiographic examination should be performed for any pediatric patient who presents with clinical evidence of delayed permanent tooth eruption or temporary tooth displacement or retained deciduous teeth with or without a history of previous dental trauma. Despite their benign nature, early diagnosis of odontomas in primary dentition allows adoption of a less complex and expensive treatment, latter complications (such as impaction) and also ensures a better prognosis.

Conflict of Interest

The authors declare that there is no conflict of interest regarding the publication of this paper.

References

1. R. Baldawa, K. Khante, J. Kalburge, and V. Kasat. Orthodontic management of an impacted maxillary incisor due to odontoma. *Contem Clin Dent.* 2011; 2(1): 37-40.
2. P. Batra, R. Duggal, O. P. Kharbanda, and H. Parkash. Orthodontic treatment of impacted anterior teeth due to odontomas: a report of two cases. *J Clin Pediatr Dent.* 2004. 28(4): 289-294.
3. H. Salgado and P. Mesquita. Compound odontoma-case report. *Revista Portuguesa de Estomatologia, Medicina Dent-aria e Cirurgia Maxilofacial.* 2013; 54(3): 164-165.

4. Vengal M, Arora H, Ghosh S, Pai KM. Large erupting complex odontoma: a case report. *J Can Dent Assoc.* 2007; 73: 169-73.
5. L. Junquera, J. C. de Vicente, P. Roig, S. Olay, and O. Rodriguez- Recio,. Intraosseus odontoma erupted into the oral cavity: an unusual pathology. *Medicina Oral, Patologia Oral y Cirugia Bucal.* 2005; 10(3): 248-251.
6. G. Serra-Serra, L. Berini-Aytés, and C. Gay-Escoda. Erupted odontomas: a report of three cases and review of the literature. *Medicina Oral, Patologia Oral y Cirugia Bucal* 2009; 14 (6):e299-e303.
7. R. Cawson, W. Binnie, P. Speight, A. Barrett, and J. Wright. *Luca's Pathology of Tumors in Oral Tissues*, Churchill Livingstone, London, UK, 5th edition, 1998.
8. B. L. Nelson and L. D. R. Thompson. Compound odontoma. *Head and Neck Pathology.* 2010; 4(4): pp. 290-291.
9. Neville BW, Damm DD, Allen CM, Bouquot JE: *Oral and Maxillofacial Pathology.* Philadelphia: Saunders; 1995: 531-33.
10. Bengston AL, Bengston NG, Benassi, LRDC: Odontomas em pacientes pediátricos. *Revista de Odontopediatria.* 1993; 2:25- 33.
11. Budnick SD: Compound and complex odontomas. *Oral Surg Oral Med Oral Path.* 1976; 42:501-506.
12. Shafer WG, Hine MK, Levy BM: *A Textbook of Oral Pathology*, 4th Ed. Philadelphia: Saunders; 1983: 308-11.
13. Areal-López L, Silvestre DF, Gil LJ: Compound odontoma erupting in the mouth: 4 year follow-up of a clinical case. *J Oral Pathol.* 1992; 21:285-88.
14. Kaugars GE, Miller ME, Abbey LM. Odontomas. *Oral Surg Oral Med Oral Pathol.* 1989; 67(2):172-176.
15. Stajcic ZZ. Odontoma associated with a primary tooth. *J Pedodont.* 1998; 12(4):415-420.
16. Hitchen AD. The impacted maxillary incisor. *Dent Pract Dent Rec.* 1970; 20: 423-433.
17. Morning P. Impacted teeth in relation to odontomas. *Int J Oral Surg* 1980; 9(2):81-91.
18. de Oliveira BH, Campos V, and Marçal S. Compound odontoma-diagnosis and treatment: three case reports. *Pediatr Dent.* 2001; 23(2): 151-7.
19. Garcia-Consuegra L, Gutierrez LMJ, Castro JMA, and Recio OR. Odontomas. A clinical-histological and retrospective epidemiological study of 46 cases. *Medicina Oral.* 2000; 5(5): 367-372.
20. Iatrou I, Vardas E, Theologie-Lygidakis N, and Leventis M. A retrospective analysis of the characteristics, treatment and follow-up of 26 odontomas in Greek children. *J Oral Sci.* 2010; 52(3): 439-447
21. Luo HY, Li TJ. Odontogenic tumors: A study of 1309 cases in a Chinese population. *Oral Oncol.* 2009; 45: 706-11.
22. Osterne RL, Brito RG, Alves AP, Cavalcante RB, Sousa FB. Odontogenic tumors: A 5-year retrospective study in a Brazilian population and analysis of 3406 cases reported in the literature. *Oral Surg Oral Med Oral Pathol Oral Radiol Endod* 2011; 111:474-81.
23. Mehra P, Singh H. Complex composite odontoma associated with impacted tooth: A case report. *N Y State Dent J.* 2007; 73: 38-40.
24. Tawfik MA, Zyada MM. Odontogenic tumors in Dakahlia, Egypt: analysis of 82 cases. *Oral Surg Oral Med Oral Pathol Oral Radiol Endod.* 2010; 109: e67-73.
25. Motokawa W, Braham RL, Morris ME, Tanaka M. Surgical exposure and orthodontic alignment of an unerupted primary maxillary second molar impacted by an odontoma and a dentigerous cyst: A case report. *Quintessence Int.* 1990; 21(2): 159-162.
26. Cozza P, Gatto R, Marino A, Mucedero M. Case report: Two nasal floor compound odontomas associated with impacted maxillary incisor. *Eur J Paediatr Dent* 2003; 4(2):99-102.
27. Oliver RG, Hodges CG. Delayed eruption of a maxillary central incisor associated with an odontome: Report of case. *ASDC J Dent Child.* 1988; 55(5):368-371.
28. Lukinmaa PL, Heitanen J, Laitinen JM, Malmström M. Mandibular dentinoma. *J Oral Maxillofac Surg* 1987; 45:60-64.
29. Raghavendra M Shetty, Sangamesh Halawar, Hanumanth Reddy, Sujata Rath, Sunaina Shetty, and Anushka Deoghare. Complex Odontome associated with Maxillary Impacted Permanent Central Incisor: A Case Report. *Int J Clin Pediatr Dent.* 2013; 6(1): 58-61.
30. Junquera L, de Vicente JC, Roig P, et al. Intraosseous odontoma erupted into the oral cavity: an unusual pathology. *Med Oral Patol Oral Cir Bucal* 2005; 10:248-51.
31. Rumel A, de Freitas A, Birman EG, et al. Erupted complex odontoma. Report of a case. *Dentomaxillofac Radiol.* 1980; 9:5-9.
32. Levy BA. Effects of experimental trauma on developing first molar teeth in rats. *J Dent Res.* 1968; 47:323-7.
33. Gomel M, Seçkin T. An erupted odontoma: case report. *J Oral Maxillofac Surg* 1989; 47:999-1000.
34. Waldron AC. Odontogenic cysts and tumours. In: Neville BW, editor. *Oral and Maxillofacial Pathology.* 2nd ed. Philadelphia: WB Saunders Company; 2002.. 631-2.
35. de Oliveira BH, Campos V, Marçal S. Compound odontoma-Diagnosis and treatment: Three case reports. *Pediatr Dent.* 2001; 23: 151-7.
36. Ide F, Obara K, Mishima K, Saito I, Horie N, Shimoyama T, Kusama K.. Peripheral odontogenic tumor: a clinicopathologic study of 30 cases. General features and hamartomatous lesions. *J Oral Pathol Med.* 2005; 34:552-7.
37. Pindborg JJ. *Pathology of dental hard tissues.* 1st edn. Philadelphia, London & Toronto: WB Saunders Company; 1970:393-401.
38. Rajendran R, Sivapathasundharam B. Shafer's textbook of oral pathology. 7th edn New Delhi: Elsevier, a division of Reed Elsevier India Pvt. Ltd, 2012:259-316.
39. Amado Cuesta S, Gargallo Albiol J, Berini Aytés L, Gay Escoda C. Review of 61 cases of odontoma. Presentation of an erupted complex odontoma. *Med Oral* 2003; 8:366-73.

40. Hitchin AD. The etiology of the calcified composite odontomes. *Br Dent J* 1971; 130(11):475-482.
41. Piattelli A, Perfetti G, Carrano A. Complex odontoma as a periapical and interradicular radiopacity in a primary molar. *J Endod* 1996; 22(10):561-563.
42. Torreti EF, Carrel R. Compound odontoma in a 12-year-old girl. *ASDC J Dent Child* 1983; 50:376-378.
43. Kokich VG, Mathews DP. Surgical and orthodontic management of impacted teeth. *Dent Clin North Am* 1993; 37(2):181-204.
44. Hisatomi M, Asaumi JI, Konouchi H, Honda Y, Wakasa T, Kishi K. A case of complex odontoma associated with an impacted lower deciduous second molar and analysis of the 107 odontomas. *Oral Dis* 2002; 8(2):100-105.

How to cite this article:

Arul Pari M *et al* (2017) 'Complex Odontome Of Impacted Maxillary Permanent Lateral Incisor And Canine With Congenitally Missing Central Incisor - A Rare Case Report', *International Journal of Current Advanced Research*, 06(07), pp. 4786-4791. DOI: <http://dx.doi.org/10.24327/ijcar.2017.4791.0584>
