

TRANSORBITAL - ORBITOCRANIAL PENETRATING INJURY BY PROTRUDING IRON RODS FROM A MOVING TRUCK: A CASE REPORT

Senthil KR and Bansal YS*

Department of Forensic Medicine, PGIMER, Chandigarh, India

ARTICLE INFO

Article History:

Received 11th April, 2017

Received in revised form 10th May, 2017

Accepted 4th June, 2017

Published online 28th July, 2017

Key words:

Transorbitalorbitocranial penetrating injuries, pillion rider, protruding rods, roadside accident, central motor vehicle act

ABSTRACT

Penetrating injuries to skull and brain account for 0.4% of the total head injuries, and among them, transorbital - orbitocranial penetrating injuries (TOPIs) are very rare representing only 0.04 % of total head injuries. In this article, we report a case of 20-year-old male presented to our Trauma centre with through and through perforated injury to the skull sustained during a roadside accident involving moving truck laden with protruding rods and deceased pillion riding a motorbike, just behind the truck. Such kind of penetration of the skull from the orbital cavity in an accidental case is uncommon and rarely reported. Recent laws of central motor vehicle act, India prohibits vehicles to carry rods/poles or any protruding material beyond the body frame. However, due to the unscrupulous practices with the due collusion of law enforcement officials and transporters, these rules are openly flouted, and such vehicles are seldom impounded, fully knowing that they pose an imminent danger to others on the road. This paper stresses the need for strict implementation of laws and also discusses the mechanism of such injuries.

Copyright©2017 Senthil KR and Bansal YS. This is an open access article distributed under the Creative Commons Attribution License, which permits unrestricted use, distribution, and reproduction in any medium, provided the original work is properly cited.

INTRODUCTION

Brain, a vital organ in the human body is well protected from penetrating injuries by skull bones. However, it is still vulnerable as this shield has some anatomical weak points like orbital cavities.¹ A sharp pointed object can penetrate orbital cavity and cause injury to the brain which is fatal most of the time. While some lesions are an innocent external injury of orbit with underlying unmanifested fracture or injury to the brain, many injuries are immediately life threatening in nature.²⁻⁵ Various causes of TOPIs are accidents at the workplace, road traffic accidents, fall over sharp objects, assault and also suicide. Various objects like pencils, ball point pen, umbrella, screw, metallic knife, iron rod and cycle break bar causing TOPIs are reported in the literature.⁶⁻⁹ Most of these injuries penetrated orbit and ended in the cranial cavity. With the best of our knowledge perforating injuries are not reported in the literature. Here we are reporting a very rare case of TOPI by iron rods in a road traffic accident and also discusses the mechanism of the same.

CASE REPORT

A 20-year-old young male presented to Trauma emergency in unconscious state with an alleged history of roadside accident. At the time of admission it was told that the deceased was a pillion rider in a bike which was hit by a truck from the side. Lacerated wound of left cheek and eye with protrusion of

eyeball and lacerated wounds over the parietal region of the scalp were noted. CT scan head showed fracture of left frontal bone and parietal bone with multiple contusions in the brain with intracerebral and intraventricular haemorrhage. The patient was under conservative treatment for three days as his vitals were unstable and finally succumbed to his injuries. At the time of post-mortem the Investigating Officer informed that the deceased was travelling on a bike as a pillion rider and sustained a penetrating injury to the left eye when the driver was trying to overtake a truck loaded with iron rods. The rods were projecting outside the truck from the rear end. He was first taken to a local government hospital and then referred to the higher centre.

Autopsy findings

On examination, a lacerated wound measuring 8 cm x 5 cm was noted on the left side face involving cheek and eye with protrusion of eyeball. Two lacerated wounds (3 cm x 2.5 cm, 3 cm x 1.5 cm) present over the right and left parietal region separated by 1.5 cm distance. On exploration, the eyeball was protruding outside the orbital cavity and was severely swollen and bruised. On opening the scalp, two round defects of diameter 2.5 cm each in the parietal bone with two bone chips in situ were noted. Dura matter underlying the fractured bone was found lacerated and brain matter was oozing out of the defects. On removing the dura matter subdural and subarachnoid haemorrhage was noted over both parietal lobes. Brain was oedematous and lacerated at left frontal and parietal lobe. Lateral ventricles were filled with blood. The wound

*Corresponding author: **Bansal YS**

Department of Forensic Medicine, PGIMER, Chandigarh, India

track was traced by introducing a probe. It was found that two rods had penetrated the orbital cavity through the roof of the orbit and fractured basi-frontal bone & ethmoid bone and entered into the base of the left frontal lobe. The rods have lacerated the left frontal and parietal lobes and emerged from the parietal bones by making two separate holes. The cause of death was given as craniocerebral damage consequent to transorbital orbitocranial penetrating injury by pointed blunt objects.

is the major concern in the South-east Asian region also. The overall road traffic fatality rate is 17 per 100,000 population, and in India, it is 16.6.¹⁰ In developing countries like India to cut the cost of transportation, truckers are frequently flouting the rules and causing fatal accidents. The truck carrying rods projecting outside the body frame is common in India. At many places of India, during the day time, there is no restriction for the trucks carrying iron rods, and it poses a grave danger to the public.

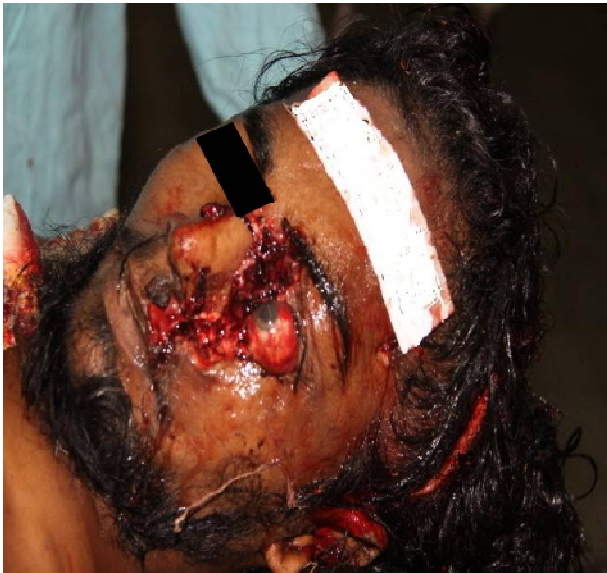

Figure 1 Lacerated wound on left cheek and orbit with protrusion of eyeball

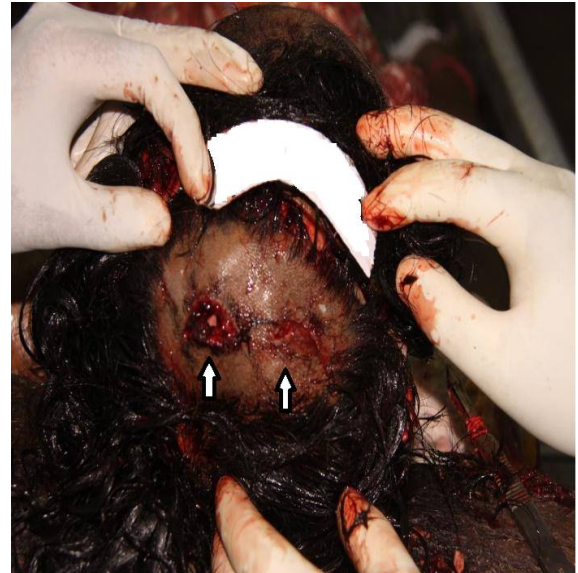

Figure 3 Fracture of right and left parietal bone with displacement of bony chips (shown by white arrows)

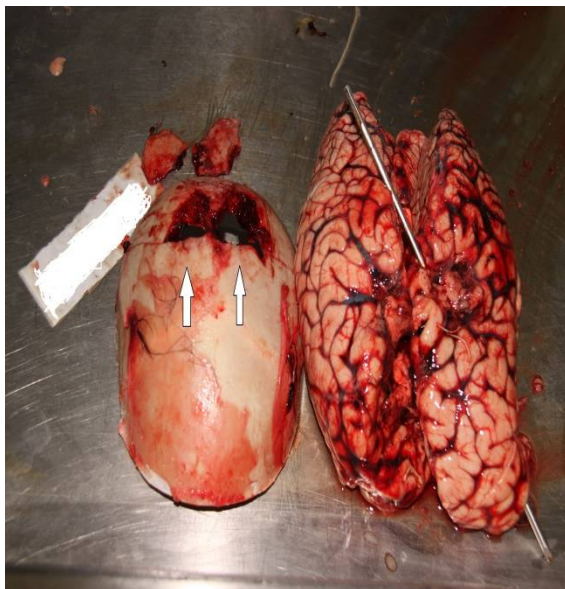


Figure 2 Fracture of right and left parietal bone with displacement of bony chips (shown by white arrows)

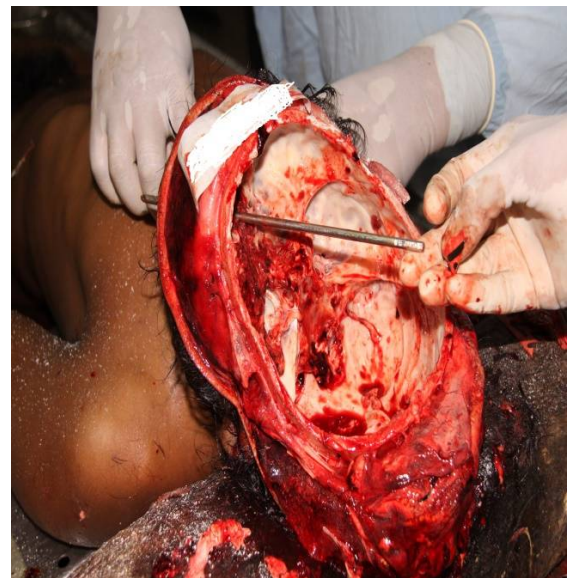

Figure 4 Probing showed that the rod penetrated the skull through theorbital cavity by fracturing the roof of orbit.

DISCUSSION

According to the recent report from WHO, each year about 1.25 million roadside fatalities are reported worldwide particularly among young people, aged 15-29 years. Ninety percent of these fatalities are among the low and middle-income countries, and half of the victims are pedestrians, cyclists, and motorcyclists. Road traffic accident

At night time it is still more dangerous as highways are devoid of lights.¹¹ As per the current Indian law, iron rods can not protrude from the truck. But previously the central motor vehicle rules (CMVR), India, 1989 section 93 allowed vehicles to carry iron rods or poles projecting not more than one meter and with a red signal at the rear end to warn motorists. But after 2015 the government has deleted that

section and completely banned vehicles from carrying any steel, iron rods and pipes projecting beyond the body frame.¹² Still, it is not uncommon to see the overloaded vehicles plying with metal rods protruding from the rear end without any precautions on Indian roads, which of course is not possible without the undue cooperation from the law enforcement agencies.

Penetrating injury to head in road traffic accident is very rare as the skull bone is hard to penetrate and usually such kind of force cause skull bone to fracture.¹³ However, as orbit especially the roof and the medial wall is the weak point of the skull, penetration can occur through this easily and can be fatal.¹⁴ Pencil, Stick, Umbrella, Knitting Needle, Knife, Metal rod, Arrow, Chopstick, Foil, Screwdriver, Pipestem, and Nail are the various objects reported in the literature as the reason for penetrating injury to orbit.⁶⁻⁹

Stab wounds caused by blunt objects or sharp weapons having a broad surface are different from the stab wounds caused by pointed thin objects. Pointed objects need minimum force to penetrate the orbit and produce less damage. Blunt object requires more force and produces a penetrating wound with a larger diameter than the object itself and damages eyeball and intracranial structures. The velocity of the wound also influences the outcome of injury. High-velocity injury (HVI) most often causes perforating injury whereas low-velocity injury (LVI) causes penetrating injury. An HVI produces more serious damage not only to the track of the projectile but also to the remote areas. This is due to the formation of a temporary cavity and shock waves. But in LVI, the damage is restricted to the path of the penetrating object as a local zone of hemorrhagic necrosis.¹⁵

In our case, we found a large laceration involving medial side of the left orbit and cheek with protrusion of eyeball. Two tracks were traced running nearby with the slightly divergent path. Both tracks penetrated the roof of orbit, the base of left frontal lobe, lateral ventricle and left parietal lobe. One track emerged from the left parietal lobe and fractured left parietal bone with displacing a bone chip and lacerated the left parietal region of the scalp. Another track crossed the midline by damaging corpus callosum and penetrated right paracentral lobule and fractured the right parietal bone with displacing a bone chip and lacerated right parietal region of the scalp just 1.5 cm away from injury on the left side. Such type of penetrating injury can be caused by high velocity pointed blunt object like iron rod as alleged by police in this case. The large lacerated wound of orbit and cheek shows the involvement of blunt force and the intracranial penetration of such extent shows the high velocity of the rod. When a person travelling on a bike with a considerable speed hit with an iron rod, high velocity is created, and the rod can penetrate the brain if it enters through the medial canthus of the eye. It also shows that the person was not wearing a helmet at the time of the accident which may deflect the impact and he would have escaped from this fatal penetration.

In 1895, an experiment was conducted by De Nobele to study about TOPIs. He used metal rods on a cadaver, and he observed less effort was needed to reach Superior Orbital Fissure (SOF). When he inserted the rod through the medial aspect of lower eyelid some what diagonally, it penetrated as far as the occipital bone, 15.5 cm deep. And many other experiments found, as medial wall and roof of the orbit is

made of thin bones; it is easy to penetrate whereas lateral wall, primarily made of Ala major and zygomatic bone, is not easily penetrable and also it deflects the approaching object towards the medial wall.¹⁶ In the present case also the penetration occurred through the roof of the orbit. Penetration through medial side of eye and roof of the orbitis most commonly reported in the literature. And in forensic perspective in all cases of TOPIs, there is always a suspicion of homicide in the absence of exact history especially in spot death cases.

CONCLUSION

As traffic rules in India are not properly followed and also due to the careless attitudes of traffic cops, such kind of accidents will continue unless offenders are severely punished. Traffic police should impose heavy fines on vehicles that ply without adequate safety measures. As per the recent laws of CMVR, 1989, the cops should act strictly to ban the vehicles carrying iron rods protruding from the rear end. A motorcyclist can prevent such kind of dangerous injuries to the head by simply wearing a helmet.

Declaration of Conflicting Interests

The authors declared no potential conflicts of interest with respect to the research, authorship and/or publication of this article.

Funding

This case report received no specific grant from any funding agency

References

1. Huelke DF. An Overview of Anatomical Considerations of Infants and Children in the Adult World of Automobile Safety Design. Annual Proceedings / Association for the Advancement of Automotive Medicine. 1998; 42:93-113.
2. Turbin RE, Maxwell DN, Langer PD, *et al.* Patterns of transorbitalintracranial injury: a review and comparison of occult and non-occultcases. *SurvOphthalmol.* 2006; 51(5):449-460.
3. Turbin RE, Levin F, Maxwell DN. Recognition of transorbitalintracranial injury. *ClinOphthalmol.* 2007; 1(1):85-89.
4. Yano H, Nishimura G, Sakamoto K, *et al.* An intracranial woodenforeign body without neurological findings: case report. *J Trauma.* 1995;38(5):830-832
5. Paiva WS, Saad F, Carvalhal ES, *et al.* Transorbital stab penetratingbrain injury. Report of a case. *Ann ItalChir.* 2009; 80(6):463-465.
6. Fisher SB, Clifton MS, Bhatia AM. Pencils and pens: anunder-recognized source of penetrating injuries in children. *Am Surg.* 2011; 77(8):1076-1080.
7. Tewari VK, Dubey RS, Dubey GC. Trans-orbital orbitocranial penetrating injury by pointed iron rod. *Journal of neurosciences in rural practice.* 2015 Apr; 6(2):231.
8. Gioia S, Bacci M, Lancia M, Carlini L, Suadoni F. Instantaneous death due to transorbital reverse penetration of a screw in an accidental fall: unusual autopsy case report and review of the literature. *The American journal of forensic medicine and pathology.* 2014 Mar 1; 35(1):15-9.

9. Huiszoon WB, Noë PN, Manten A. Fatal transorbital penetrating intracranial injury caused by a bicycle hand brake. *International journal of emergency medicine*. 2012 Dec 1; 5(1):34.
10. Road traffic injuries [Internet] 2016 May [cited 2016 Jun 21]. Available from: <http://www.who.int/mediacentre/factsheets/fs358/en/>.
11. Cops fail to rein in trucks with overhanging rods. The Times of India [Internet] 2013 Jul 19 [cited 2016 Jun 22]. Available from: <http://timesofindia.indiatimes.com/city/noida/Copsfailtoreinintruckswithoverhangingrods/articleshowprint/21154038.cms?null>.
12. Dipak Kumar Dashi. Govt bans trucks from carrying protruding rods. The Times of India, New Delhi [Internet]. 2014 Mar 8 [cited 2016 Jun 21]. Available from: <http://timesofindia.indiatimes.com/india/Govt-bans-trucks-from-carrying-protruding-rods/articleshow/31630728.cms>.
13. Gennarelli TA, Champion HR, Sacco WJ, *et al*. Mortality of patients with head injury and extracranial injury treated in trauma centers. *J Trauma*. 1989; 29(9):1193-1201.
14. Orszagh M, Zentner J, Pollak S. Transorbital intracranial impalement injuries by wooden foreign bodies: clinical, radiological and forensic aspects. *Forensic Sci Int*. 2009; 193(1Y3):47-55.
15. Kataria R, Singh D, Chopra S, Sinha VD. Low velocity penetrating head injury with impacted foreign bodies in situ. *Asian journal of neurosurgery*. 2011 Jan; 6(1):39.
16. Tate A. A theory for the deceleration of long rods after impact. *Journal of the Mechanics and Physics of Solids*. 1967 Nov 1; 15(6):387-99.

How to cite this article:

Senthil KR and Bansal YS (2017) 'Transorbital - Orbitocranial Penetrating Injury By Protruding Iron Rods From A Moving Truck: A Case Report', *International Journal of Current Advanced Research*, 06(07), pp. 4564-4567.
DOI: <http://dx.doi.org/10.24327/ijcar.2017.4567.0538>
