

CLINICAL APPROACH FOR EVALUATION AND MANAGEMENT OF DISORDERS OF SEX DEVELOPMENT

Najya A. Attia*

King Abdulaziz Medical City, Pediatric Department, Endocrine Unite King Saud bin Abdulaziz University for Health Sciences/King Abdullah International Medical Research Center Jeddah, Saudi Arabia

ARTICLE INFO

Article History:

Received 16th April, 2017

Received in revised form 12th May, 2017

Accepted 6th June, 2017

Published online 28th July, 2017

Key words:

Genitalia; disorders of sex development; sex assignment.

ABSTRACT

"It's a boy" and "It's a girl" are words that are heard every second of every day all around the world. However, it is very distressing when the birth attendants are unable to make such a pronouncement because of disorders of sex development (DSD). DSD are congenital conditions associated with an atypical development of chromosomal, gonadal or anatomical sex. Normal sex development progresses in steps from conception to the complete development of the fetal external genitalia; any disturbance in any of these steps can lead to DSD. Ambiguous genitalia are the most common type of DSD and it is a challenging clinical diagnosis for the pediatric endocrinologist. A newborn baby with ambiguous genitalia is often a surprise for both the medical team and the parents, frequently described as an emergency. The condition needs a special approach in terms of counseling the parents appropriately, evaluation and management. The Chicago Conference (2006) recommended new nomenclature and a classification for DSD, as the old nomenclature was confusing for doctors and parents, and sometimes pejorative. The new classification is based on karyotyping and gonadal structure, improving understanding of the underlying pathogenic mechanisms. The rapid progression of genetic diagnosis of DSD using advanced techniques such as next-generation sequencing (NGS) allows more appropriate diagnosis and genetic counseling for families.

The focus of the article is a review of normal sex development, DSD classification, clinical approach, genetic assessment, sex assignment, surgical management and risk of germ cell tumor development.

Copyright©2017 **Najya A. Attia**. This is an open access article distributed under the Creative Commons Attribution License, which permits unrestricted use, distribution, and reproduction in any medium, provided the original work is properly cited.

INTRODUCTION

Normal sex development and differentiation

Sex differentiation is a complex phenomenon that follows five steps: 1-Genetic sex, the conjugation of a sperm and the ovum gives rise to the fertilized egg, which has either a 46, XY or 46,XX chromosome (1). 2-Formation of undifferentiated structures, during the first six weeks of gestation the male and female fetus develops similar sex elements, which consist of the following potential structures: I) The gonadal ridge which develops in the testis or ovary. II) Germ cells, which eventually develop into spermatocytes or oocytes. III) Two sets of internal sex ducts (Wolffian ducts in males and Mullerian ducts in females). IV) External genitalia including the genital tubercle, urethral folds, labioscrotal folds and urogenital sinus. 3-Gonadal differentiation, the bipotential gonad develops into testis in the presence of a Y chromosome, which carries the SRY gene (Sex-determining Region Y) responsible for testicular formation. In the absence

of a Y chromosome or SRY gene, the gonad develops into an ovary (2). 4-Gonadal hormones, at 7 weeks of gestation the testis secrete two hormones, testosterone and anti-Müllerian hormone (AMH). The testosterone is produced by the Leydig cells of the fetal testes and plays an essential role in the differentiation of Wolffian ducts to the epididymis, vas deferens and seminal vesicle. The AMH, on the other hand, is secreted by the Sertoli cells of the fetal testes and is responsible for the regression of Müllerian ducts. In females, the Müllerian ducts develop spontaneously into fallopian tubes, uterus and upper third of the vagina and the Wolffian ducts disappear (3). 5-Phenotypic sex differentiation, the cells of the external genitalia of the male fetus has the ability to metabolize testosterone to dihydrotestosterone (DHT), which is more potent than testosterone and induces masculinization of external genitalia at about 9-12 weeks gestation. In a male fetus, the genital tubercle lengthens and thickens to form the penis, the urethral folds grow to become the penile urethra and the genital swellings enlarge to form the scrotal swelling which fuses in the midline to form the scrotum (4). In female fetuses, the absence of circulating testosterone allows the genital tubercle to develop into the clitoris, the urethral folds

*Corresponding author: **Najya A. Attia**

King Abdulaziz Medical City, Pediatric Department,
Endocrine Unite King Saud bin Abdulaziz University for
Health Sciences /King Abdullah International Medical
Research Center Jeddah, Saudi Arabia

into the labia minora and the genital swelling into the labia majora

Nomenclature and classification of DSD

Table 1 Revised nomenclature

Previous	Current
Intersex	Disorders of sex development
Female pseudohermaphrodite	46XX DSD
Male pseudohermaphrodite	46XY DSD
True hermaphrodite	Ovotesticular DSD
XX male	Testicular DSD
XY sex reversal	46XY completegonadal dysgenesis

The Previous nomenclature of DSD (Table1) such as intersex, sex reversal, pseudohermaphroditism and hermaphroditism was pejorative and confusing to parents, patients and doctors. As a consequence, a re-examination of DSD nomenclature and different classifications took place. In 2006, international experts in pediatric endocrinology met at the Chicago Conference under the auspices of the European Society for Pediatric Endocrinology and the Pediatric Endocrine Society and recommended new nomenclature (Table1) for DSD, which was defined as “congenital conditions in which the development of chromosomal, gonadal, or anatomic sex is atypical” (5,6). This definition is wide and includes any disorder that results in abnormal sex differentiation.

The current nomenclature and classifications (Table1) are clear, understandable for physicians, patients and their

families, and provide information regarding the patient’s chromosome and gonadal structure, but is not very specific regarding etiology and depend on the physician’s approach and facilities for diagnosis.

DSD clinical approach

Multidisciplinary team

The best way to approach DSD is through a multidisciplinary team, which includes a neonatologist, endocrinologist, pediatric surgeon, psychologist and other ad hoc members (7). The first step is to counsel the shocked parents, as the birth of a baby with ambiguous genitalia is unexpected for both parents and the medical team. Parents need support and usually have many questions. The team leader should meet with them and provide initial information and support including offering the family the opportunity to have a supportive family member or a close friend to join them. Also, the role of the leader is to advise the parents to delay the registration of the birth, discuss with them the diagnosis, initial treatment plan, findings relevant to sex assignment, the team’s recommendations and options, and to provide information and current evidence regarding gender identity outcomes in similar cases.

History

A complete detailed history from the parents is essential for an appropriate diagnosis (5, 8) including unexplained sudden infant death, ambiguity, infertility, precocious puberty, amenorrhea, hirsutism, maternal exposure to hormones (particularly progestagens and steroids), (9,10) or

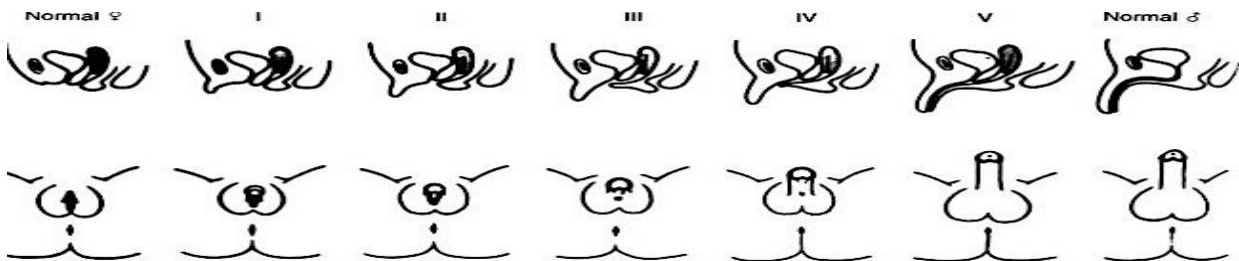


Fig.1 The degree of virilization of external genitalia of females as proposed by Prader. In Prader 1 the only abnormality is mild clitoromegaly with separate openings for urethra and vagina. Praders 2 through 4 demonstrates the progression of virilization from mild to severe. Prader 5 is a markedly enlarged phallus with penile urethra.

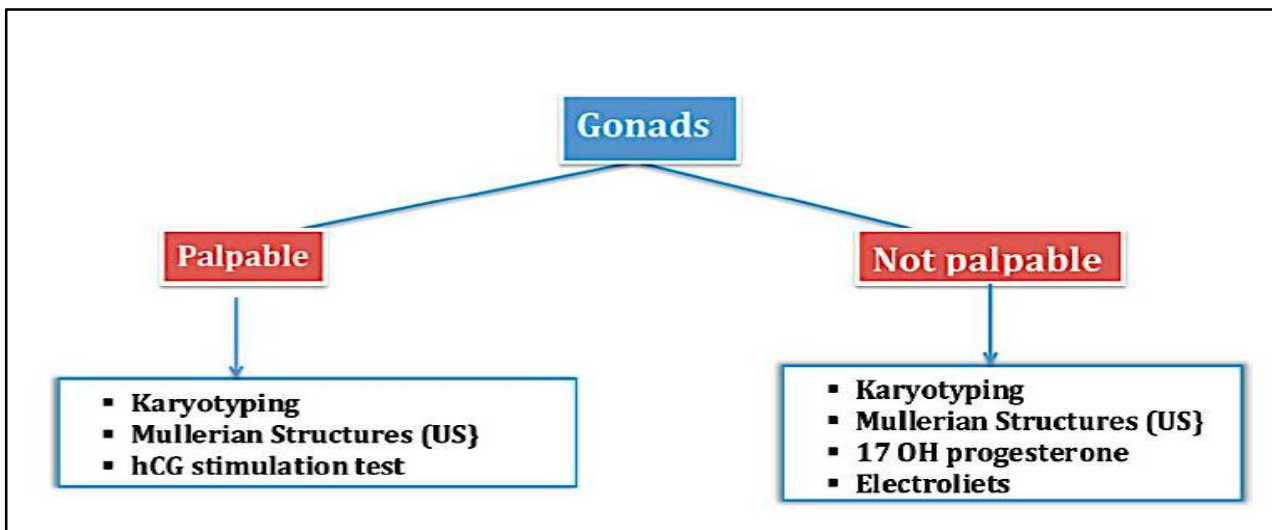


Fig 2 Algorithm for basic investigation for patient with DSD based on gonadal palpation. Abbreviations: DSD, disorder of sex development; hCG, human chorionic gonadotropin.

consanguinity. The possibility of aromatase deficiency or maternal androgen secreting tumors with a history of maternal virilization during pregnancy should be considered (5,11,12).

Physical examination

Parents should be informed in advance about the method of examination and it should be demonstrated to them. In a warm place, with the baby in the frog leg position, a general inspection is performed focusing on the genital anatomy (5,8). After inspection, palpate for the gonads within the inguinal canal, scrotum, and labioscrotal folds, using the appropriate technique. The gonads are sometimes not palpable. A palpable gonad is most likely testis or rarely an ovotestis because a streak gonad and ovaries are rarely descend. Measure an abnormal phallic width and stretched length, examine for fused labia or bifid scrotum and determine the position of urethral opening and other orifices in the perineum. The Prader classification (Fig.1) provides a useful guide to classify the degree of female virilization. The findings range from 1 (mild clitoromegaly) to 5 (complete virilization with urethral opening up at the tip of enlarged phallus) (13). The patient is classified according to the palpable or nonpalpable gonads approach (Fig.2) for differential diagnosis and investigation purposes.

XX DSD (female pseudohermaphroditism)

Patients in this category have a normal female karyotype and Mullerian structures but variable degrees of virilization of external genitalia with nonpalpable gonads. An elevated serum 17-OHP indicates the presence of CAH, the frequent cause of 46XX DSD (14,15,16,17,18) due to 21-alpha hydroxylase-CYP21 deficiency, which leads to the accumulation of 17-OHP and excessive production of androgens (Fig. 5). Most patients have the salt-wasting form, which can present with a life-threatening adrenal crisis in the second or third week of life (19). If the levels of 17-OHP are normal, other types of CAH should be investigated. For example, an enzymatic defect in the adrenal cortisol synthesis pathway 11β-Hydroxysteroid (11β-OH) or 3β-hydroxysteroid dehydrogenase (3β-HSD), can lead to the excessive production of androgens and the accumulation of their precursors (Fig. 5). Other rare causes of 46XX DSD include medication, tumors (adrenal or ovarian) and aromatase deficiency. The identification of such causes can be accomplished through a complete history, physical examination and the demonstration of a high androgen level.

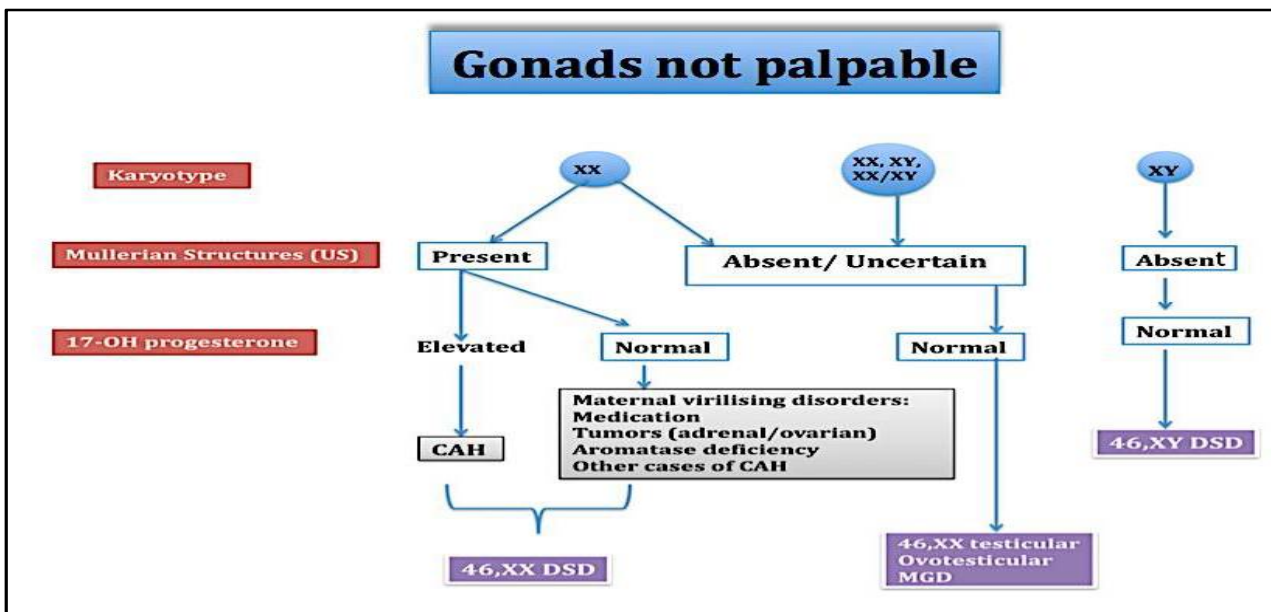


Fig 3 Algorithm for diagnosing DSD in patients with impalpable gonads by incorporating findings from karyotyping, imaging studies and other laboratory analyses. Abbreviations: CAH, congenital adrenal hyperplasia; DSD, disorder of sex development; MGD, mixed gonadal dysgenesis.

Basic Investigation

The basic diagnostic tests for all patients are karyotyping and pelvic ultrasound to evaluate the presence of Mullerian structures. Other tests that should be done are, for example, the measurement of serum levels of sodium, potassium and 17-hydroxyprogesterone (17-OHP) on the third day of life or later for patients with nonpalpable gonads. This is important because congenital adrenal hyperplasia (CAH), the most common DSD, may result in a life-threatening salt-losing crisis. In addition, a patient with palpable gonads should undergo a human chorionic gonadotropin (hCG) stimulation test to assess the gonadal production of androgens.

Possible diagnosis and further investigation depend on the results of the initial investigations (Fig. 3, 4).

XY DSD (male pseudohermaphroditism)

Patients in this category have a normal male karyotype and absence of Mullerian structures but with variable degrees of undervirilization of external genitalia with palpable gonads in most of cases. Fig. 6. Illustrates the mechanism of virilization of the male external genitalia and the main causes of undervirilization. An hCG stimulation test is a reliable test to determine the gonadal function and it assists in diagnosing the most common causes of 46XY DSD [partial androgen insensitivity syndrome (PAIS) and 5-alpha reductase deficiency (5-ARD)]. In PAIS, testosterone (T) and dihydrotestosterone (DHT) levels are high while in 5-ARD, the ratio of T to DHT is high, unresponsive testosterone indicates gonadal failure due to either structural or hormonal

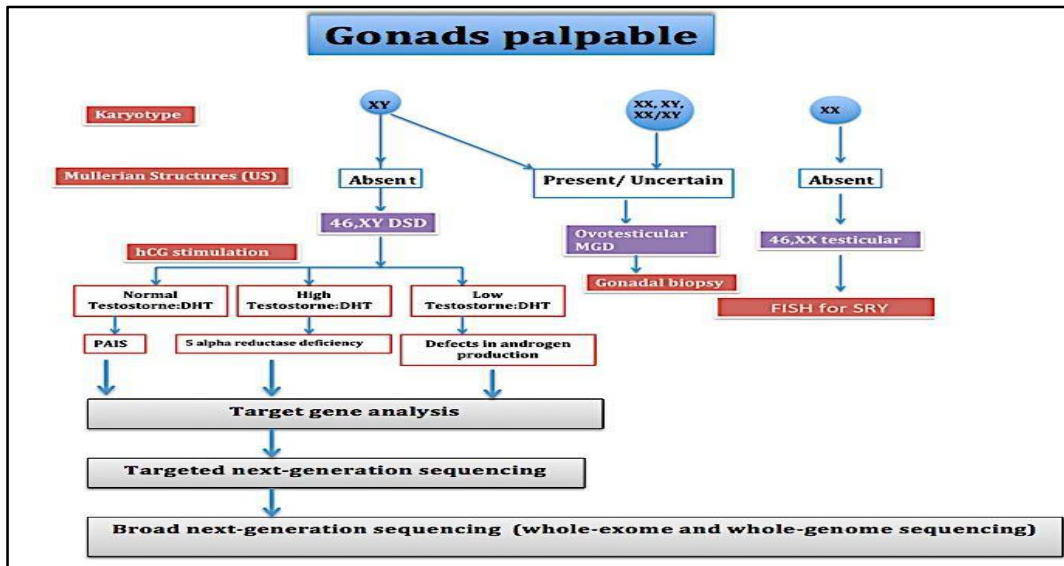


Fig 4 Algorithm for diagnosing DSD in patients with palpable gonads by incorporating findings from karyotyping, imaging studies and other laboratory analyses. Either targeted gene analysis or targeted next-generation sequencing is preferable for accurate diagnosis of known gene disorder before anuntargeted analysis is performed. Abbreviations: DSD, disorder of sex development; MGD, mixed gonadal dysgenesis; FISH, fluorescent *in situ* hybridization; hCG, human chorionic gonadotropin; SRY, sex-determining region Y protein.

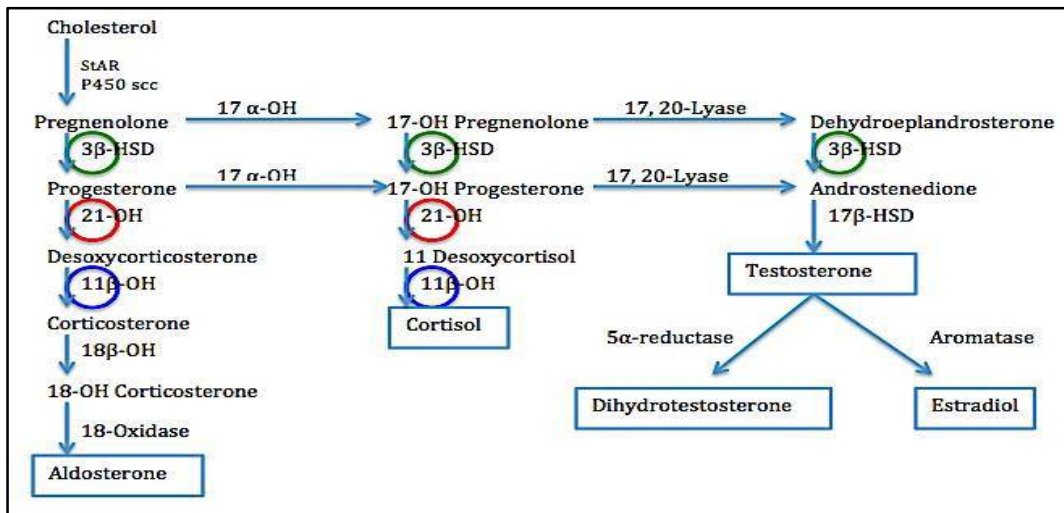


Fig 5 The androgen pathway and the mechanism of virilization caused by the most Common form of CAH (21-OH deficiency, 3β-OH deficiency and 11β-OH deficiency). Note that accumulation of precursors above the enzymatic defect lead to virilization by excessive production of androgen. Abbreviations: StAR, steroidogenic Acute Regulatory protein; 3β-HSD, 3β-Hydroxysteroid; 21-OH, 21-hydroxylase; 11β-OH, 11β-Hydroxysteroid dehydrogenase; 17β-HSD, 17β-Hydroxysteroid dehydrogenase; 18β-OH, 8β-hydroxylase.

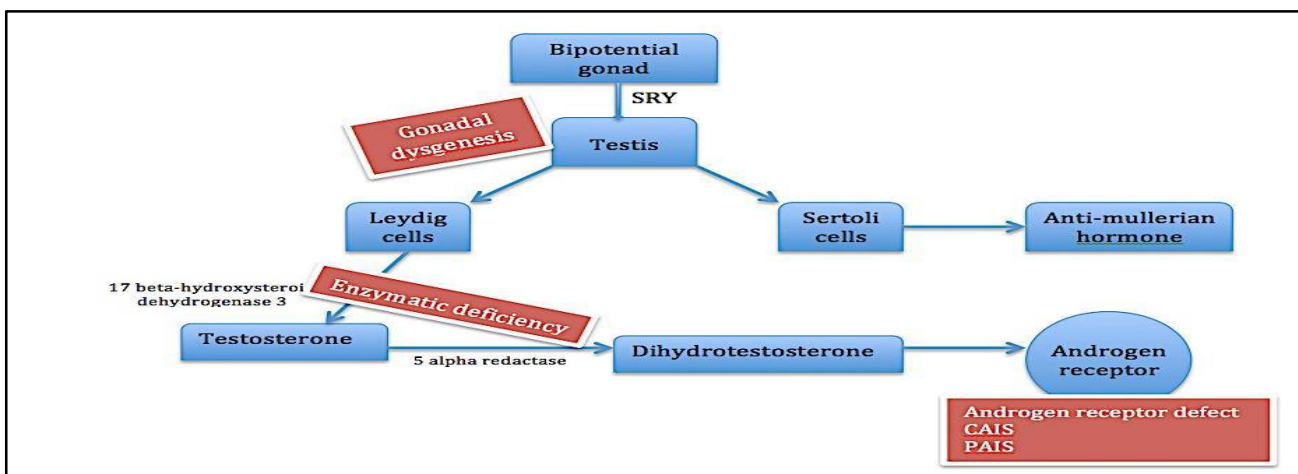


Fig 6 Mechanism of virilization of the male external genitalia. Triangular shaped boxes demonstrate the main causes of undervirilization. Abbreviations: PAIS, partial androgen insensitivity syndrome; CAIS, complete I androgen insensitivity syndrome

synthesis defects and elevated testosterone precursors may indicate a defect of testicular testosterone synthesis (Fig. 6). There is no consensus about the way how an hCG stimulation test should be conducted, but the protocol we used is daily intramuscular hCG 1000–1500 units for three consecutive days, and measuring basal serum dehydroepiandrosterone sulfate, androstenedione, T and DHT 24 hours after the last injection (20). Another protocol, twice-weekly injections for 3 weeks, can also be used but it takes much longer. In case of normal hCG results, an adrenocorticotropic hormone (ACTH) stimulation test demonstrates a specific defect in adrenal testosterone syntheses such as 17 α -hydroxylase and 17,20-lyase. An objective of the rapid advances in genetic studies for DSD in recent years was to make a definitive diagnosis and provide genetic counseling for families. The 46XY DSD mutation, in particular, has been identified in the androgen receptors in about 50% of PAIS and in the 5-alpha reductase gene (SRD5A2). Although genetic testing is an excellent tool that can aid in the diagnosis, it is expensive, not widely available and cannot replace the clinical approach.

Ovotesticular disorder of sexual development (true hermaphroditism)

It is a rare disorder of sex differentiation with geographic variations in the incidence and karyotyping (21). It constitutes about 3-10% of all DSD (6,22,23). However, in Southern Africa, this condition occurs in 51% of DSD patients (21). It is characterized by the presence of gonads of ovotestis or a combination of testis on one side and an ovary or ovotestis on the other side. The main clinical presentation is ambiguous genitalia and a unilateral palpable gonad, which can be either be an ovotestis or testis, usually located in the right side (24,25,26). Karyotyping is variable. 46XX is the most frequent and constitutes about 60% of cases (27-30), followed by mosaicism 46XX/46XY (25-30%) and 46XY (10-15%) (30,31). Internal sex duct development usually corresponds with the adjacent gonad. Wolffian duct structures typically develop on the gonadal side that contain testicular tissue whereas Müllerian duct structures tend to be observed on the gonadal side that do not contain testicular tissue (32). The patients with ovotesticular DSD could be found in both the palpable and nonpalpable gonads groups (Fig.3, 4) but 46XX DSD with a palpable gonad should raise a strong suspicion of ovotesticular DSD. An uncertain Müllerian duct structure is identified with ultrasound and the androgen concentration could be normal for the male range if testicular tissue is predominant. A diagnosis of ovotesticular DSD is dependent solely on the gonadal biopsy results, which should show the presence of ovarian follicles and testicular seminiferous tubules (27).

46XX testicular DSD

It is a rare disorder with an estimated prevalence of 1/20,000 males. The nomenclature indicates that patients with 46XX testicular DSD have a 46XX karyotype and testes. The appearance of external genitalia depends on the presence of the SRY-gene. Approximately 80-90% of patients is SRY-gene positive (33) and has normal male external genitalia. They usually present with infertility, delayed puberty, gynecomastia and a short stature (34). Endocrine tests show hypergonadotropic hypogonadism due to testicular failure (35,32). On the other hand, patients who are SRY-gene negative (10-20%), usually have ambiguous genitalia

presenting at birth or infancy (36,37). Clinically patients will be in the palpable gonads group (Fig.4). Patients with 46 XX karyotype and absent normal female internal ducts should raise the suspicion of 46 XX testicular DSD diagnosis, which could be confirmed by identifying the SRY-gene using fluorescence in situ hybridization (FISH) or chromosomal microarray (CMA).

46XY complete gonadal dysgenesis (CGD)

Patients with 46XY CGD are phenotypically females; they have normal female internal ducts (fallopian tubes, uterus and vagina) and external female genitalia. The patient cannot be identified at birth or childhood and is only diagnosed in adolescence or adulthood when they present with primary amenorrhea, delayed puberty but with a normal stature and the absence of dysmorphic features. This disorder is also referred to as Swyer syndrome, named after Swyer and colleagues who initially described the female appearance of a patient with negative X-chromatin, normal stature and having streak gonads (38). The majority of cases of XY CGD are of unknown etiology; SRY mutations and deletions have been identified in about 10-20% of the cases (39,40). Other deletions that were described include NR5A1 (9q33) (41,42,1), CBX2 (17q25) (54), DMRT1(9p24.3) (43,44), and a heterozygous mutation in MAP3K1 (5q11.2) (45). Patients at pubertal age have high levels of follicle-stimulating hormone (FSH), luteinizing hormone (LH) and low estrogens, which indicate gonadal failure. FISH for SRY and comparative genomic hybridization (CGH) are recommended to identify the etiology (43). The treatment consists of hormone replacement therapy and surgical removal of any streak gonads, if present, because of the high potential for malignancy (gonadoblastoma or dysgerminoma) 20-30% (46,47).

Sex assignment

At birth or infancy sex assignment depends on the following factors: 1) Potential for sexual activity. 2) Potential for fertility. 3) The feasibility of constructive surgery. 4) The type of DSD. 5) Prenatal androgen exposure. 6) Family culture (19,48). For 46 XX CAH, the most frequent condition of DSD, the consensus is to raise individuals as female because 90% of patients have a female gender identity, however, about 5% of patients have gender dysphoria (49). Most patients with 46 XX CAH have the potential for normal sexual function and fertility. However, some publications recommend male gender assignment for markedly virilized patients (Prader 5 and some Prader 4) (13). The topic is controversial, but currently, the recommendation is to raise all patients with 46XX CAH as females whatever the stage of virilization (23). The recommendation for patients with 46XY complete androgen insensitivity (CAIS) or complete gonadal dysgenesis is to be raised as females as they are accepting themselves as female, haven't been exposed in utero to an effective androgen that may affect their identity [48,50], are phenotypically females and have an adjusted sexual life. However, some of these individuals have been reported as having a male gender identity. Patients with 46XY 5 α reductase or 17 β hydroxysteroid dehydrogenase3 deficiency are usually recommended to be raised as males even with severe undervirilization (51). The recommendations reflect the potential for virilization at puberty (33) and the possibility for fertility (52, 53) and are supported by literature, reporting

that more than 60% of 5 α -reductase-deficient patients and 50% of 17 β -hydroxysteroid dehydrogenase-3 deficiency patients, who are assigned as female in infancy, ultimately change their gender role (54). However, there are some case reports about patients with 17 β hydroxysteroid dehydrogenase-3 deficiency that were assigned females (41). For patients with incomplete gonadal dysgenesis, PAIS and androgen biosynthetic defects, there is still no consensus or recommendations regarding sex assignment, about 25% of individuals are dissatisfied with the sex of rearing whether they are raised as a boy or a girl (55). The decision of sex assignment in patients with ovotesticular DSD depends on the degree of gonadal function and its effect on genital development, the possibility of fertility and normal sexual activity. The same should be considering for patients with mixed gonadal dysgenesis (MGD). Individuals with cloacal exstrophy are usually raised as females (65%) but there is variability in gender identity outcomes (19).

Surgical management

The time for repair with feminizing genitoplasty, which include clitoroplasty, labioplasty and vaginoplasty is not well defined; most surgeons prefer early surgery in infancy and in a specialized center for patients with significant virilization (Prader 3 or higher) (19,56,7). Studies reported that early surgery may improve the relationship between children and their parents and relieve parental distress (57-59). It also assists in avoiding complications from the connection between the peritoneum and the urinary tract and benefits from the estrogen effect on tissue in early infancy (56). Several surveys demonstrated that surgery early in life for patients with CAH does not affect their physical and mental quality of life more than other surgical and nonsurgical chronic medical conditions (60, 61). Most women with CAH favor surgery before adolescence (21,22) although some studies show poor functional and cosmetic results of genitoplasty done in infancy (59, 60) with a high rate of re-intervention in adulthood (62). Other surgeons prefer deferring at least vaginoplasty until puberty, as most of the patients require vaginal dilatation at that time (63-65) if the surgery is done early. The evidence for either approach is limited. Vaginal dilatation should be avoided before puberty. There is no systematic evidence for prophylactic removal of asymptomatic discordant structures, such as a Mullerian remnants or utriculus. The testes should be removed at the time of diagnosis for patients with CAIS (26), PAIS raised female and androgen biosynthetic defects raised female to prevent malignancy in adulthood, associated hernia and psychological problems with the presence of testes. The streak gonads are also at risk of malignancy and the current recommendations are that they have to be removed in early childhood for patients with MGD raised male (66) and females with gonadal dysgenesis and Y chromosome (64). A scrotal testis is at increased risk for developing into a malignancy in patients with gonadal dysgenesis and testicular biopsy is recommended at puberty for early diagnosis of premalignant lesion (67). In patients with bilateral ovotestes, separation of ovarian and testicular tissue is performed early in life, as patients are potentially fertile from functional ovarian tissue (66, 68).

Genetics

In the near future, genetic diagnosis of DSD will become the

primary and most accurate approach for diagnosis. The rapid progression of genetic techniques enables diagnosis of complex diseases such as DSD through next-generation sequencing (NGS), which includes: 1) chromosomal microarray, which allows the detection of copy number variants (CNVs) microduplications and microdeletions as small as 50 kb (69, 70). In two studies examining a large number of patients with DSD (116 and 23, respectively), CNVs were identified in 13% to 21.5% of the cases (71, 72). 2) Coding regions of the genome (whole-exome sequencing) represent 1%-2% of the entire genome, but contain around 85% of the mutations that cause known genetic disorders (73, 74) and identify significant variants in novel DSD genes (75). 3) Targeted gene sequencing (TGS) is an accurate and fast way to diagnose DSD if the causative gene is known. The coding sequences of 35 known genes involved in sex determination have been developed (76). The best example of advanced progress in genetic diagnosis of DSD is the ability to diagnose the fetal CAH as early as 5 weeks 6 days of gestation by targeted massively parallel sequencing (MPS) of DNA in maternal plasma (77).

Risk of gonadal malignancy

Patients with DSD are at increased risk for gonadal malignancies especially germ cell tumors such as dysgerminomas, seminomas and nonseminomas. The risk in general depends on: 1) the presence of a Y chromosome with undervirilization particularly gonadal dysgenesis and ovotestis (78). 2) The location of the gonad(s). The risk of malignancy is 20%-30% for patients with complete gonadal dysgenesis and 15%-20% for those with mixed gonadal dysgenesis (45, 79). Gonadoblastomas are the most common gonadal tumors and they develop within the first to second decade of life and a gonadectomy is the current management (80). Abdominal or pelvic testis is also at increased risk of tumor development and should be either removed in patients raised as females or descended into the scrotum if raised as males. The scrotal testis is at risk of malignancy in patients with gonadal dysgenesis, and a biopsy is required at the time of puberty to diagnose the tumor early (81). Patients with ovotestis or CAIS have the lowest risk (0.5%) of developing malignancies (40, 48).

CONCLUSION

Much progress has been made in the knowledge and diagnosis of individuals with DSD. DSD conditions are complex and need a multidisciplinary team with knowledgeable and skillful experts in the management of DSD and specialized centers with the best facilities for diagnosis and management. Parents and patients should be informed in detail about each step in the management, diagnosis and given enough time to ask questions. A clinical algorithm facilitates making the final diagnosis and avoids unnecessary investigation and reserve resources. The goal of DSD management in infancy should be to maintain stable gender identity, preserve potential sexual function and fertility and provide cosmetic and functioning external genitalia. Management includes different but important components such as diagnosis, family support, sex assignment and the risk of malignancy. Each component needs accuracy and cautious decision-making. Future studies are essential to be able to determine the cause and the most appropriate management for each individual patient.

Declaration of interest

The authors declare that they have no conflict of interest.

Funding

This research did not receive any specific grant from any funding agency in the public, commercial or not-for-profit sector.

References

1. Mukherjee AB, Parsa NZ. Determination of sex chromosomal constitution and chromosomal origin of drumsticks, drumstick-like and other nuclear bodies in human blood cells at interphase by fluorescence in situ hybridization. *Chromosoma* 99: C432-C435, 1990.
2. Rey R, Josso N, Racine C. Sexual Differentiation. [Updated 2016 Jun 12]. In: De Groot LJ, Chrousos, Dungan K, Feingold KR, Grossman A, Hershman JM, Koch C, Korbonits M, McLachlan R, New M, Purnell J, Rebar R, Singer F, Vinik A, editors. Endotext [Internet]. South Dartmouth (MA): MDText.com, Inc.; 2000-.2016 Jun 12.
3. Fauci AS, Barunwald E, Kasper D, Hauser S, Longo D, Jameson JL, Loscalzo J. Harrison's principles of internal medicine (17th ed.). New York: McGraw-Hill Medical. 2339-2346, 2008.
4. Hughes IA. Minireview: Sex Differentiation. *Endocrinology* 142: C3281-3287, 2001.
5. Lee PA, Houk CP, Ahmed SF, Hughes IA, International Consensus Conference on Intersex organized by the Lawson Wilkins Pediatric Endocrine Society and the European Society for Paediatric Endocrinology: Consensus Statement on Management of Intersex Disorders. International Consensus Conference on Intersex. *Pediatrics* 118:E488-E500, 2006.
6. Hughes IA, Houk C, Ahmed SF, Lee PA. Lawson Wilkins Pediatric Endocrine Society/European Society for Paediatric Endocrinology Consensus Group. Consensus statement on management of intersex disorders. *J Pediatr Urol*. 2: C148-C162, 2006.
7. Schaeffer TL, Tryggestad JB, Mallappa A, Hanna AE, Krishnan S, Chernaused SD, Chalmers LJ, Reiner WG, Kropp BP, Wisniewski AB. An evidence-based model of multidisciplinary care for patients and families affected by classical congenital adrenal hyperplasia due to 21-Hydroxylase Deficiency. *Int J Pediatr Endocrinol* 2010: C692439, 2010.
8. Clayton PE, Miller WL, Oberfield SE, Ritzén EM, Sippell WG, Speiser PW, ESPE/LWPES CAH Working Group. Consensus statement on 21-hydroxylase deficiency from the European Society for Paediatric Endocrinology and the Lawson Wilkins Pediatric Endocrine Society. *Horm Res* 58: C188-C195, 2002.
9. Cohen-Bendahan CC, van de Beek C, Berenbaum SA. Prenatal sex hormone effects on child and adult sex-typed behavior: methods and findings. *Neurosci Biobehav Rev* 29: C353-C384, 2005.
10. Wallen K. Nature needs nurture: the interaction of hormonal and social influences on the development of behavioral sex differences in rhesus monkeys. *Horm Behav* 30: C364-C378, 1996.
11. Ahmed SF, Rodie M. Investigation and initial management of ambiguous genitalia. *Best Pract Res Clin Endocrinol Metab* 24: C197-C218, 2010.
12. Spitzer RF, Wherrett D, Chitayat D, Colgan T, Dodge JE, Salle JL, Allen L. Maternal luteoma of pregnancy presenting with virilization of the female infant. *J Obstet Gynaecol Can* 29: C835-C840, 2007.
13. Prader A. Der genitalbefund beim pseudohermaphroditismus femininus der kengenitalen adrenogenitalen syndroms. *Helv Paediatr Acta* 9: C231-C248, 1954.
14. Hughes IA. Disorders of sex development: a new definition and classification. *Best Pract Res Clin Endocrinol Metab* 22: C119-C134, 2008.
15. Parisi MA, Ramsdell LA, Burns MW, et al. A gender assessment team: experience with 250 patients over a period of 25 years. *Genet Med* 9: C348-C357, 2007
16. Göllü G, Yildiz RV, Bingol-Kologlu M, Yagmurlu A, Senyücel MF, Aktug T, Gökcora IH, Dindar H. Ambiguous genitalia: an overview of 17 years' experience. *J Pediatr Surg* 42: 840-844, 2007.
17. Ocal G, Berbero_glu M, Siklar Z, Bilir P, Uslu R, Yağmurlu A, Tükün A, Akar N, Soygür T, Gültan S, Gedik VT. Disorders of sexual development: an overview of 18 years experience in the pediatric endocrinology department of Ankara University. *J Pediatr Endocrinol Metab* 23: C1123-C1132, 2010.
18. Meyer-Bahlburg HF. Gender and sexuality in classic congenital adrenal hyperplasia. *Endocrinol Metab Clin North Am* 30:155-71, 2001.
19. Speiser PW, Azziz R, Baskin LS, Ghizzoni L, Hensle TW, Merke DP, Meyer-Bahlburg HF, Miller WL, Montori VM, Oberfield SE, Ritzen M, White PC; Endocrine Society. Congenital adrenal hyperplasia due to steroid 21-hydroxylase deficiency: an Endocrine Society clinical practice guideline. *J Clin Endocrinol Metab* 95: C4133-C4160, 2010.
20. Ahmed, S.F., Achermann, J.C., Arlt, W. et al. UK guidance on the initial evaluation of an infant or an adolescent with a suspected disorder of sex development. *Clinical Endocrinology*, 75, 12–26, 2011.
21. Ozsu E, Mutlu GY, Cizmecioglu FM, Ekingen G, Muezzinoglu B, Hatun S. Ovotesticular disorder of sexual development and a rare 46, XX/47, XXY karyotype. *J Pediatr Endocrinol Metab* 26: C789-C791, 2013.
22. Wettasinghe KT, Sirisena ND, Andraweera PH, Jayasekara RW, Dissanayake VH. A case series of five Sri Lankan patients with ovotesticular disorder of sex development. *Clin Pediatr Endocrinol* 21: C69-C73, 2012.
23. Wiersma R, Ramdial PK. The gonads of 111 South African patients with OvoTesticular Disorder of Sex Differentiation. *J Pediatr Surg* 44: C556-C560, 2011.
24. Luy SC, Ho F. A rare case of true hermaphrodite with features of Klinefelter syndrome. *Philipp J Intern Med* 51: 1-9, 2013.
25. Sircili MH, Denes FT, Costa EM, Machado MG, Inacio M, Silva RB, Srougi M, Mendonca BB, Domenice S. Long-term followup of a large cohort of patients with ovotesticular disorder of sex development. *J Urol* 191: C1532-C1536, 2013.

26. Van Niekerk WA, Retief AE. The gonads of human true hermaphrodites. *Hum. Genet* 58: C117-C122, 1981.
27. Krob G, Braun A, Kuhnle U. True hermaphroditism: geographical distribution, clinical findings, chromosomes and gonadal histology. *Eur J Pediatr* 153: C2-C10, 1994.
28. Walker AM, Walker JL, Adams S, Shi E, McGlynn M, Verge CF. True hermaphroditism. *J Paediatr Child Health* 36: C69-C73, 2000.
29. Achermann JC, Hughes IA. Disorders of sex development. In: William's Textbook of Endocrinology, 12th edn. Melmed S, Polonsky KS, Larsen PR, Kronenberg HM (eds). Saunders, Philadelphia, pp 887-891, (2012).
30. Matsui F, Shimada K, Matsumoto F, Itesako T, Nara K, Ida S, Nakayama M. Long-term outcome of ovotesticular disorder of sex development: a single center experience. *Int J Urol* 18: 231-236, 2011.
31. Sperling MA. Pediatric endocrinology. Philadelphia: Saunders, 2008, p. 138.
32. McElreavey K, Vilain E, Abbas N, Herskowitz I, Fellous M. A regulatory cascade hypothesis for mammalian sex determination: SRY represses a negative regulator of male development. *Proc Natl Acad Sci U S A* 90: 3368-3372, 1993.
33. De la Chapelle A. Analytic review: nature and origin of males with XX sex chromosomes. *Am J Hum Genet* 24: C71-C105, 1972.
34. Pérez-Palacios G, Medina M, Ullao-Aguirre A, Chávez BA, Villareal G, Dutrem MT, Cahill LT, Wachtel S. Gonadotropin dynamics in XX males. *J Clin Endocrinol Metab* 53: C254-C257, 1981.
35. Zenteno-Ruiz JC, Kofman-Alfaro S, Méndez JP. 46,XX sex reversal. *Arch Med Res* 32: C559-C566, 2001.
36. Grigorescu-Sido A, Heinrich U, Grigorescu-Sido P, Jauch A, Hager HD, Vogt PH, Duncea I, Bettendorf M. Three new 46,XX male patients: a clinical, cytogenetic and molecular analysis. *J Pediatr Endocrinol Metab* 18: C197-C203, 2005.
37. Swyer GI. Male pseudohermaphroditism: a hitherto undescribed form. *Brittish Medical Journal* 2: C709-C712, 1995.
38. Michala L, Creighton SM. The XY female. *Best Pract Res Clin Obstet Gynaecol* 24: 139-148, 2010.
39. Rocha VB, Guerra-Junior G, Marques-de-Faria AP. Complete gonadal dysgenesis in clinical practice: the 46,XY karyotype accounts for more than one third of cases. *Fertil Steril* 96: C1431-C1434, 2011.
40. Cools M, Van Aerde K, Kersemaekers AM, Boter M, Drop SL, Wolffenbittel KP, Steyerberg EW, Oosterhuis JW, Looijenga LH. Morphological and immunohistochemical differences between gonadal maturation delay and early germ cell neoplasia in patients with undervirilization syndromes. *J Clin Endocrinol Metab* 90: C5295-C5303, 2005.
41. Migeon CJ, Wisniewski AB, Gearhart JP, Meyer-Bahlburg HF, Rock JA, Brown TR, Casella SJ, Maret A, Ngai KM, Money J, Berkovitz GD. Ambiguous genitalia with perineoscrotal hypospadias in 46,XY individuals: long-term medical, surgical, and psychosexual outcome. *Pediatrics* 110: Ce31, 2002.
42. Moore CL. The role of maternal stimulation in the development of sexual behavior and its neural basis. *Ann N Y Acad Sci* 662: 160-77, 1992.
43. Muroya K, Okuyama T, Goishi K. Sex-determining gene(s) on distal 9p: clinical and molecular studies in six cases. *J Clin Endocrinol Metab* 2000 85: 3094-3100, 2000.
44. Pearlman A, Loke J, Le Caignec C. Mutations in MAP3K1 cause 46,XY disorders of sex development and implicate a common signal transduction pathway in human testis determination. *Am J Hum Genet* 87: C898-C899, 2010.
45. Looijenga LHJ, Hersmus R, Oosterhuis JW, Cools M, Drop SL, Wolffenbittel KP. Tumor risk in disorders of sex development (DSD). *Best Pract Res Clin Endocrinol Metab* 21: 480-495, 2007.
46. Simpson JL, Photopulos G. The relationship of neoplasia to disorders of abnormal sexual differentiation. *Birth Defects Orig Artic Ser* 12: C15-C50, 1976.
47. Byne W. Developmental endocrine influences on gender identity: implications for management of disorders of sex development. *MtSinai J Med* 73: C950-C959.
48. Dessens AB, Slijper FM, Drop SL. Gender dysphoria and gender change in chromosomal females with congenital adrenal hyperplasia. *Arch Sex Behav* 34: C389-C397, 2005.
49. Houk CP, Lee PA. Approach to assigning gender in 46, XX congenital adrenal hyperplasia with male external genitalia: replacing dogmatism with pragmatism. *J Clin Endocrinol Metab* 95: C4501-C4508, 2010.
50. Bertelloni S, Balsamo A, Giordani R, Fischetto R, Russo M, Delvecchio M, Genarri M, Nicoletti A, Maggio MC, Concolino D, Cavallo L, Cicognani A, Chiumello G, Hiort O, Baroncelli GI, Faienza MF. 17 β -Hydroxysteroid dehydrogenase-3 deficiency: from pregnancy to adolescence. *J Endocrinol Invest* 32: 666-670, 2009.
51. Werner R, Kulle A, Sommerfeld I, Riepe FG, Wudy S, Hartman MF, Merz H, Döhnert U, Bertelloni S, Holterhus PM, Hiort O. Testosterone synthesis in patients with 17 β -hydroxysteroid dehydrogenase 3 deficiency. *Sex Dev* 6: C161-C168, 2012.
52. T'Sjoen G, De Cuypere G, Monstrey S, Hoebeke P, Freedman FK, Appari M, Holterhus PM, Van Borsel J, Cools M. Male gender identity in complete androgen insensitivity syndrome. *Archives of sexual behavior*. 2011 Jun 1; 40(3):635-8.
53. Kang HJ, Imperato-McGinley J, Zhu YS, Rosenwaks Z. The effect of 5 α -reductase-2 deficiency on human fertility. *Fertil Steril* 101: 310-316, 2014.
54. Cohen-Kettenis PT. Gender change in 46,XY persons with 5-alpha-reductase-2 deficiency and 17-beta-hydroxysteroid dehydrogenase-3 deficiency. *Arch Sex Behav* 34: C399- C410, 2005.
55. M, Hampel E, Hiort O, Thyen U. "Any decision is better than none" decision-making about sex of rearing for siblings with 17 β -hydroxysteroid-dehydrogenase-3 deficiency. *Arch Sex Behav* 35: C359-C371, 2006.
56. -Bahlburg HF. Gender identity outcome in female-raised 46,XY persons with penile agenesis, cloacal exstrophy of the bladder, or penile ablation. *Arch Sex*

- Behav* 34: 423-438, 2005.
57. Warne G, Grover S, Hutson J, Sinclair A, Metcalfe S, Northam E, Freeman J, Murdoch Childrens Research Institute Sex Study Group. A long-term outcome study of intersex conditions. *J Pediatr Endocrinol Metab* 18: C555-C567, 2005.
 58. Farkas A, Chertin B, Hadas-Halpren I. 1-Stage feminizing genitoplasty: 8 years of experience with 49 cases. *J Urol* 165: C2341-2346, 2001.
 59. Crouch NS, Minto CL, Laio LM, Wooshouse CR, Creighton SM. Genital sensation after feminizing genitoplasty for congenital adrenal hyperplasia: a pilot study. *BJU Int* 93: C135-C138, 2004.
 60. American Academy of Pediatrics. Timing of elective surgery on the genitalia of male children with particular reference to the risks, benefits, and psychological effects of surgery and anesthesia. *Pediatrics* 97: C590-C594, 1996.
 61. Stikkelbroeck NM, Beerendonk CC, Willemsen WNP, Schreuders-Bais CA, Feitz WF, Rieu PN, Hermus AR, Otten BJ. The long-term outcome of feminizing genital surgery for congenital adrenal hyperplasia: anatomical, functional and cosmetic outcomes, psychosexual development, and satisfaction in adult female patients. *J Pediatr Adolesc Gynecol* 16: C289-C296, 2003.
 62. Creighton SM, Minto CL, Steele SJ. Objective cosmetic and anatomical outcomes at adolescence of feminising surgery for ambiguous genitalia done in childhood. *Lancet* 358: 124-125, 2001.
 63. Eroglu E, Tekant G, Gundogdu G, Emir H, Ercan O, Söylet Y, Danişmend N. Feminizing surgical management of intersex patients. *Pediatr Surg Int* 20: C543-C547, 2004.
 64. Alizai NK, Thomas DF, Lilford RJ, Batchelor AG, Johnson N. Feminizing genitoplasty for congenital adrenal hyperplasia: what happens at puberty? *J Urol* 161: C1588-C1591, 1999.
 65. MM, Gearhart JP, Migeon C, Rock J. Vaginal reconstruction after initial construction of the external genitalia in girls with salt wasting adrenal hyperplasia. *J Urol* 148: C680-C684, 1992.
 66. Williams RH, Larsen PR. Disorders of sex differentiation. In: Williams textbook of endocrinology, edited by P. Reed Larsen. Philadelphia: WB Saunders, 2003, p. 842-1002.
 67. Rangecroft L. Surgical management of ambiguous genitalia. *Arch Dis Child* 88: C799-C801, 2003.
 68. Nihoul-Fekete C. The Isabel Forshall Lecture. Surgical management of the intersex patient: an overview in 2003. *J Pediatr Surg* 39: C144-C145, 2004.
 69. Ostrer H. Changing the game with whole exome sequencing. *Clin Genet*. 80: C101-C103, 2011.
 70. Wheeler DA, Srinivasan M, Egholm M, Shen Y, Chen L, McGuire A, He W, Chen YJ, Makhijani V, Roth GT, Gomes X, Tartaro K, Niazi F, Turcotte CL, Irzyk GP, Lupski JR, Chinault C, Song XZ, Liu Y, Yuan Y, Nazareth L, Qin X, Muzny DM, Margulies M, Weinstock GM, Gibbs RA, Rothberg JM. The complete genome of an individual by massively parallel DNA sequencing. *Nature* 452: C872-C876, 2008.
 71. Tannour-Louet M, Han S, Corbett ST, Louet JF, Yatsenko S, Meyers L, Shaw CA, Kang SH, Cheung SW, Lamb DJ. Identification of de novo copy number variants associated with human disorders of sexual development. *PLoS One* 5: e15392, 2010.
 72. S, Ohnesorg T, Notini A, Roeszler K, Hewitt J, Daggag H, Smith C, Turbitt E, Gustin S, van den Bergen J, Miles D, Western P, Arboleda V, Schumacher V, Gordon L, Bell K, Bengtsson H, Speed T, Hutson J, Warne G, Harley V, Koopman P, Vilain E, Sinclair A. Copy number variation in patients with disorders of sex development due to 46, XY gonadal dysgenesis. *PLoS One* 6: Ce17793, 2011.
 73. SB, Buckingham KJ, Lee C, Biggam AW, Tabor HK, Dent KM, Huff CD, Shannon PT, Jabs EW, Nickerson DA, Shendure J, Bamshad MJ. Exome sequencing identifies the cause of a mendelian disorder. *Nat Genet* 42: C30-C35, 2010.
 74. Shendure J, Porreca GJ, Reppas NB, Lin X, McCutcheon JP, Rosenbaum AM, Wang MD, Zhang K, Mitra RD, Church GM. Accurate multiplex polony sequencing of an evolved bacterial genome. *Science* 309: C1728-C1732, 2005.
 75. Cooper DN, Krawczak M. The mutational spectrum of single basepair substitutions causing human genetic disease: patterns and predictions. *Hum Genet* 85: C55-C74, 1990.
 76. Arboleda VA, Lee H, Sánchez FJ, Délot EC, Sandberg DE, Grody WW, Nelson SF, Vilain E. Targeted massively parallel sequencing provides comprehensive genetic diagnosis for patients with disorders of sex development. *Clin Genet* 83: C35-C43, 2013.
 77. MI, Tong YK, Yuen T, Jiang P, Pina C, Chan KC, Khattab A, Liao GJ, Yau M, Kim SM, Chiu RW, Sun L, Zaidi M, Lo YM. Non-invasive prenatal diagnosis of congenital adrenal hyperplasia using cell-free fetal DNA in maternal plasma. *J Clin Endocrinol Metab* 99: Ce1022-C1030, 2014.
 78. Looijenga LHJ, Hersmus R, de Leeuw BH, et al. Gonadal tumours and DSD. *Best Pract Res Clin Endocrinol Metab* 24: 291-310, 2010.
 79. GB, Parra DA, Oudjhane K, Miller SF, Babyn PS, Pippi Salle FL. Imaging of ambiguous genitalia: classification and diagnostic approach. *RadioGraphics*. 28: C1891-C1904, 2008.
 80. Papaioannou G, Sebire NJ, McHugh K. Imaging of the unusual pediatric 'blastomas.' *Cancer Imaging* 9: C1-C11, 2009.
 81. M, Meyts RE, Andersson L, Dieckmann KP, Fosså SD, Grigor KM, Hendry, Herr HW, Looijenga LHJ, Oosterhuis JW, Skakkebaek NE. Carcinoma in situ in the testis. *Scand J Urol Nephrol Suppl* 205: C166-C186, 2000.
 82. Ramani P, Yeung CK, Habeebu SS. Testicular intratubular germ cell neoplasia in children and adults with intersex. *Am J Surg Pathol* 17: C1124-C1133, 1993.
