



**ORAL SUBMUCOUS FIBROSIS-ETIOPATHOLOGY
A REVIEW ARTICLE**

Manya.Suresh^{1*} and Preetha S²

¹Saveetha Dental College, India

²Department of Physiology, Saveetha Dental College, India

ARTICLE INFO

Article History:

Received 29th January, 2017

Received in revised form 19th February, 2017

Accepted 22nd March, 2017

Published online 28th April, 2017

Key words:

Areca nut, Betel quid, Habits,
oral sub mucous fibrosis.

ABSTRACT

Oral submucous fibrosis is a chronic, complex, premalignant lesion of the oral cavity, characterized by juxta-epithelial inflammatory reaction and progressive fibrosis of the submucosal tissues (the lamina propria and deeper connective tissues). As the disease progresses, the jaws become rigid to the point that the person is unable to open the mouth. The condition is remotely linked to oral cancers and is associated with areca nut or betel quid chewing, a habit similar to tobacco chewing, is practiced predominantly in Southeast Asia and India, dating back thousands of years. This is a highly potent and chronic pre-cancerous condition that affects various portions of the oral cavity as well as the pharynx. This review is done to create awareness about oral submucous fibrosis.

Copyright©2017 Manya.Suresh and Preetha S. This is an open access article distributed under the Creative Commons Attribution License, which permits unrestricted use, distribution, and reproduction in any medium, provided the original work is properly cited.

INTRODUCTION

Oral Submucous fibrosis (OSMF) is a chronic, complex, premalignant lesion of oral cavity characterized by inflammation and progressive fibrosis of lamina propria and deeper connective tissues, followed by stiffening of an otherwise yielding mucosa resulting in difficulty in opening the mouth.^[1,2] It is generally accepted today that areca nut quid plays a major role in the etiology of the disease.^[3] The disease occurs mostly in India and in South East Asia but the cases have been reported world wide like Kenya, China, UK, Saudi Arabia and other part of the world where Asians are migrating.^[4,5] In 1952, Schwartz introduced the term "atrophic acidopathica mucosa oris" to describe an oral fibrosing disease he discovered in 5 Indian women from Kenya.^[6] Joshi subsequently termed it as oral submucous fibrosis (OSMF) in 1953.^[7] Stringent measures are needed to bring this epidemic of Oral submucous fibrosis under control. The current review aims to refresh our knowledge regarding Oralsubmucous fibrosis and make a few suggestions to fill the lacunae in this field.

A few reasons proposed for the increased incidence of OSMF

- The low cost, easy availability, attractive packaging, and aggressive marketing have led to a substantial increase in the number of people initiating this habit and getting addicted to it

- Advertisements portray consumption of these products as confidence boosters or a status symbol giving it a midas touch
- Advertisements also portray these products as breath fresheners thereby attracting a larger audience
- A lack of proper demarcation between the various products such as gutka, pan masala, and their contents
- As smoking is considered a taboo in certain areas of the country, majority of the women take in to tobacco/betel quid chewing
- In India areca nut is deeply rooted in the cultural/religious beliefs of the people, it is considered sacred so is distributed to people during occasions like marriages, etc., and hence people chewing it is not uncommon nor is it objectionable
- There could be a lower reporting of the incidence of OSMF due to minimal symptoms in the early stages and a lack of awareness regarding the same
- Multiple pregnancies combined with poor nutritional status can act as a promoting factor in the presence of habits.^[8]

Classification of Osmf

Oral submucous fibrosis is clinically divided into three stages.^[9]

- Stage 1: Stomatitis
- Stage 2: Fibrosis
- a- Early lesions, blanching of the oral mucosa

**Corresponding author: Manya.Suresh*
Saveetha Dental College, India

- b- Older lesions, vertical and circular palpable fibrous bands in and around the mouth or lips, resulting in a mottled, marble-like appearance of the buccal mucosa
- Stage 3: Sequelae of oral submucous fibrosis
 1. Leukoplakia
 2. Speech and hearing deficits

Khanna and Andrade in 1995 developed a group classification system for the surgical management of trismus:^[10]

- Group I: Earliest stage without mouth opening limitations with an interincisal distance of greater than 35 mm.
- Group II: Patients with an interincisal distance of 26–35 mm.
- Group III: Moderately advanced cases with an interincisal distance of 15-26 mm. Fibrotic bands are visible at the soft palate, and pterygomandibular raphe and anterior pillars of fauces are present.
- Group IVA: Trismus is severe, with an interincisal distance of less than 15 mm and extensive fibrosis of all the oral mucosa.
- Group IVB: Disease is most advanced, with premalignant and malignant changes throughout the mucosa.

Quid

Quid is a mixture of substances which is placed in the mouth, where it is sucked or is actively chewed over an extended period of time. It usually contains either tobacco or areca-nut or both, in raw or in any manufactured or processed form which are considered to be the basic ingredients. Betel quid is also known as paan, which varies in its composition, from community to community and between individuals, although the major constituents are areca-nut and slaked lime (from limestone or coral), tobacco and is wrapped within a betel leaf. The paan is placed between the teeth and the Buccal mucosa, and is either chewed or sucked for several hours. It produces a feeling of euphoria and well-being. The mechanism behind this is the release of an alkaloid from the areca-nut. Some other substances may also be added such as grated coconut or spices like aniseed, peppermint, cardamom and cloves, based on the local preference. Tobacco which is a basic ingredient, is associated with an increased risk of oral.^[23] cancer. The lime releases reactive oxygen species from extracts of areca-nut which might be the contributing factor for cytogenetic damage involved in oral cancer. A synergistic increase in risk of oral cancer has been demonstrated among those people who consume alcohol, smoke and chew quid. Paan has variants which use areca-nut alone along with certain sweeteners, to make it attractive to younger children.

Very early (stage I)	Early (stage II)	Moderately advanced (stage III)	Advanced (stage IV)
A finely fibrillar collagen, dispersed with marked edema	The juxta-epithelial area shows early hyalinization	The collagen is moderately hyalinized	The collagen is completely hyalinized
The fibroblastic response is strong	Plump young fibroblasts are present in moderate numbers	The fibroblastic response is less marked, the cells present being mostly adult fibrocytes	The hyalinized areas are devoid of fibroblasts
The blood vessels are sometimes normal, but more often they are dilated and congested	The blood vessels are dilated and congested	Blood vessels are normal or constricted	Blood vessels are completely obliterated or narrowed
Inflammatory cells, mainly polymorphonuclear leukocytes with an occasional eosinophil, are present	Inflammatory cells are mostly mononuclear lymphocytes, eosinophils, and an occasional plasma cell	Inflammatory exudates consist of lymphocytes and plasma cells, although an occasional eosinophil is seen	Inflammatory cells are lymphocytes and plasma cells

Etiopathology

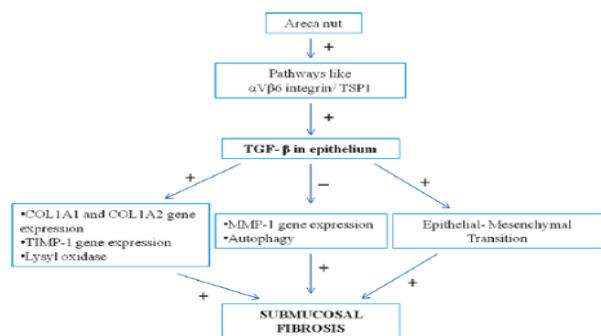
In spite of all the research work done on the etiological factors of oral submucous fibrosis over the years, a single factor cannot be established rather several factors have been proposed. The most common factors include areca nut chewing, ingestion of chilies, genetic and immunologic processes, nutritional deficiencies, and other factors among which betel quid (BQ) chewing has been recognized as the most important risk factor.^[11,12]

Tobacco & Lime: Pan Masala, Gutka and Mawa (areca, tobacco and lime) are commercially freeze dried products with high concentrates of areca nut per chew. They act as local irritants and cause OSMF more rapidly than by self-prepared conventional betel quid which contain smaller amounts of areca nut.

It is sold under various names such as sweet supari, gua, mistee, mawa. Some other variants are kiwam, zarda, mitha pan which includes tobacco and a variety of other substances.

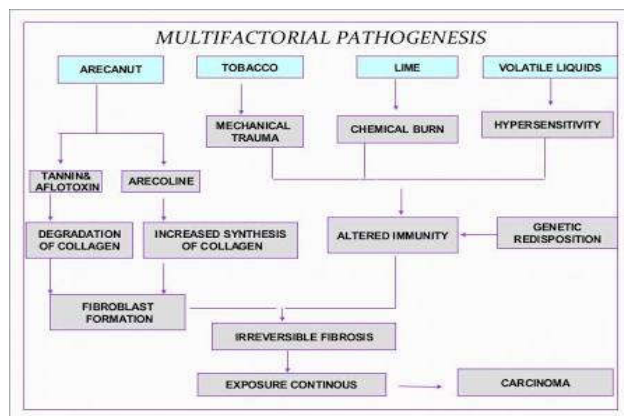
Areca Nut: Areca nut is strongly associated with OSMF. It contains many alkaloids such as arecoline, arecaine, guvacine & guvacoline, of which arecoline is the main agent. Arecoline is the active metabolite in fibroblast stimulation as it not only stimulates fibroblastic proliferation and collagen synthesis but also decreases its breakdown. It exerts this action by upregulating copper-dependent extracellular enzyme lysyl oxidase by fibroblasts leading to excessive cross linking and accumulation of collagen. It also acts by generating free radicals and causing immunosuppression. Commercially available sachets of gutka, paan contains areca nut cut in to small pieces coated with various chemicals. The incorporation of copper into the areca nut is through the Bordeaux mixture

which is sprayed as a fungicide on areca plantations in regions with scheduled monsoons and of which copper sulfate is an important constituent. There is evidence to suggest that the metal matrix binding of copper in plants is associated with lectins and glycoproteins.^[21] This copper incorporated in the nut and leaves is again absorbed by the plant as the leaves and nut shed off and get decomposed and absorbed within the soil. The copper content of various constituents of quid are red areca (18.3ppm), white areca (14.9 ppm), betel leaf (18.5 ppm), gutkha (13.2 ppm), flavoredareca (12.2 ppm), tobacco (6.3 ppm). The above data shows that betel leaf contains highest amount of copper.^[20] The processed form of betel nut ie the freeze-dried products (panmasala, gutkha, mawa) contain higher concentration of copper as compared to raw form, this may be because of the copper which is added to it as a preservative. Thus, it is emphasized that further research is required to validate the incorporation of copper into areca nut through Bordeaux mixture. Also the water level of the areca plantations should be assessed for the copper concentration to correlate the present notion of spraying of Bordeaux mixture and increased copper in areca plantations grown in the monsoon terrains.^[22]



Chillies

Chillies act as irritant to oral mucosa. Their continued use and use of other spices cause continued irritation of the mucosa and chronic inflammation which leads to fibrosis. Capsaicin, which is vanillylamide of 8-methyl-6-nonenic acid, is the active ingredient of chillies, play a key role in OSMF. Hence chillies have indirect effect on the pathogenesis of OSMF as hypersensitivity to chillies is often explained as a common factor in the development of OSMF.



Nutritional Deficiency: Subclinical vitamin B complex deficiency is seen in many cases of OSMF with vesiculations and ulcerations of oral cavity which is probably precipitated by the effect of defective nutrition due to impaired food intake

in advanced cases and may be the effect, rather than the cause of the disease. High prevalence of OSMF in low socioeconomic groups may be due to poor quality of food, low vitamins and iron, use of more spices and chillies to make the food tasty, coupled with lack of health consciousness. Combined effect of vitamin and iron deficiency along with malnourished state of the host leads to deranged inflammatory reparative response of the lamina propria with resultant defective healing and scar formation which ultimately leads to OSMF.

Immunological disorders: Raised immunoglobulin levels of IgA, IgG and IgM in OSMF are indirect indicators of immunological problems associated with OSMF.^[13]

Role of Infection

An important link between OSF and decreased immune response may be the suggested viral origin of the disease. Human papillomavirus DNA, herpes simplex virus DNA and Epstein-Barr virus DNA were detected from some patients with OSF. Viral lesions show similar immune derangements such as abnormal CD4/CD8 cell ratio as seen in OSF. Furthermore, viral antigen can elicit specific suppressor T-cell response. The resulting immunosuppression allows the spread of viral antigen and associated transformation of epithelium. A defect in target cell or viral cell lysis is seen by natural killer NK cells in OSF.^[19]

Symptoms

Early OSMF presents with a burning sensation in oral cavity aggravated by spicy food (42%), followed by either hyper salivation or dryness of the mouth [25%].^[14] It presents with blisters especially on the palate, ulcerations or recurrent generalized inflammation of the oral mucosa.^[15] Common initial symptoms are:

- Intolerance/Burning sensation in the mouth on consuming hot and spicy food
- Trismus
- Blanching, i.e., marble-like appearance of the oral mucosa and stiffness of oral mucosa
- Reduced mobility of the soft palate and tongue
- Hypersalivation
- Defective gustatory sensation and dryness of the mouth
- Blisters on the palate, ulcerations or recurrent generalized inflammation of the oral mucosa
- Mild hearing loss due to blockade of Eustachian tube

In advanced OSMF, oral mucosa becomes blanched and slightly opaque with appearance of white fibrous bands on buccal mucosa, lips, soft palate, faucial pillars and tongue. With progressive fibrosis, stiffening of certain areas of mucosa occur which results in difficulty in opening of the mouth, difficulty in swallowing and inability to whistle or blow air.^[14] In severe cases, the patient cannot protrude the tongue beyond the incisor teeth and there is a progressive closure of the oral opening. The oral mucosa is involved symmetrically and the fibrous bands in the buccal mucosa run in a vertical direction.^[14,16]

The density of the fibrous deposit varies from a slight whitish area on the soft palate causing no symptoms to a dense fibrosis causing fixation and shortening or even deviation of the uvula and soft palate.^[17] Depending on the habit of chewing or swallowing tobacco, areca nuts and its related

products, the fibrotic changes can be seen in the mucosa of the oral cavity or esophagus.^[18,12] Laterality of OSMF depends on the fact that which side of the oral mucosa is more exposed to tobacco products. This is usually noted during examination that one side of the buccal mucosa is fibrosed whereas other side is completely normal.

CONCLUSION

Oral submucous fibrosis is a chronic inflammatory disease affecting the oral mucosa and has a high risk of malignant transformation. Though the exact etiology is not known, it can be said that there is a further scope for research to elicit the etiopathogenesis and subsequent management of this condition, so that we can provide a better standard of living to our patients suffering from this potentially malignant condition. From a study done by This review was done to create awareness among the people about the harmful effects of all the factors.

References

1. Pindborg JJ, Barmes D, Reed-Peterson B. Epidemiology and histology of oral leukoplakia and leukoedema among Papuans and New Guineans. *Cancer* 1968; 22:379-84.
2. WHO. Meeting report. Control of oral cancer in developing countries. *WHO Bull* 1984; 62:617.
3. Babu S, Bhat RV, Kumar PU, Sesikaran B, Raokv, Aruna P, et al. A comparative clinico-pathological study of oral submucous fibrosis in habitual chewers of panmasala and betel quid. *Clintoxicol* 1996; 34:317-22.
4. Tang JG, Jian XF, Gao ML, Ling TY, Zhang KH. Epidemiological survey of oral submucous fibrosis in Xiangtan city, Hunan province, China. *Commun Dentist Oral Epidemiol* 1997; 25:177-80. [pubmed]
5. Shah B, Lewis MA, Bedi R. Oral submucous fibrosis in 11 year-old Bangladeshi girl living in United Kingdom. *Br Dent J* 2001; 191:130-2. [pubmed] [fulltext]
6. Schwartz J. Atrophialidiodiopathica (tropical) mucosa oris. Demonstrated at the 11th International Dental Congress, London 1952.
7. Joshi SG. Submucous fibrosis of the palate and pillars. *Indian J Otolaryngol*. 1953; 4:1-4.
8. Hebbar P B, Sheshaprasad R, Gurudath S, Pai A, Sujatha D. Oral submucous fibrosis in India: Are we progressing??. *Indian J Cancer* 2014; 51:222-6
9. Pindborg, JJ (1989). "Oral submucous fibrosis: a review". *Annals of the Academy of Medicine, Singapore*. 18 (5): 603-7. PMID 2694917.
10. Khanna, J.N.; Andrade, N.N. (1995). "Oral submucous fibrosis: a new concept in surgical management". *International Journal of Oral and Maxillofacial Surgery*. 24 (6): 433-9. doi:10.1016/S0901-5027(05)80473-4. PMID 8636640.
11. Angadi PV, Rekha K. Oral submucous fibrosis: a clinicopathologic review of 205 cases in Indians. *Oral and Maxillofacial Surgery* 2011; 15(1):15-9.
12. Tilakaratne WM, Klinikowski MF, Saku T, Peters TJ, Warnakulasuriya S. Oral submucous fibrosis: Review on aetiology and pathogenesis. *Oral Oncol* 2006; 42:561-8.
13. Samdariya S, Kumar D, Kumar A, Porwal P, Pareek P. Oral submucous fibrosis-A short review. *Int J Med Sci Public Health* 2014; 3:1308-1312.
14. Pai SA. Gutkha banned in Indian states. *Lancet Oncol* 2002; 3:521. [PUBMED]
15. Times News Network. Maharashtra bans sale of pan masala. Bangalore: The Times of India; 2012. p. 12.
16. Goldenberg D, Lee J, Koch WM, Kim MM, Trink B, Sidransky D, et al. Habitual risk factors for head and neck cancer. *Otolaryngol Head Neck Surg* 2004; 131:986-93.
17. Rajendran R, Vijayakumar T, Vasudevan DM. An alternative pathogenetic pathway for oral submucous fibrosis (OSMF). *Med Hypotheses* 1989; 30:35-7.
18. Rajalalitha P, Vali S. Molecular pathogenesis of oral submucous fibrosis: A collagen metabolic disorder. *J Oral Pathol Med* 2005; 34:321-8.
19. Ratheesh AV, Kumar B, Mehta H, Sujatha GP, Shankarmurthy SP. Etiopathogenesis of oral submucous fibrosis. *J Med Radiol Pathol Surg* 2015; 1:16-21.
20. Shrijana S, Ongole R, Sumanth KN. Copper content of various constituents of betel quid. *Indian J Dent Res* 2009; 20:4.
21. Trivedy C, Baldwin D, Warnakulasuriya S, Johnson NW, Peters JJ. Copper content in Areca catechu (betel nut) products and OSMF. *Lancet* 1997; 349:1447.
22. Khan S, Chatra L, Prashanth SK, Veena K M, Rao PK. Pathogenesis of oral submucous fibrosis. *J Can Res Ther* 2012; 8:199-203
23. M.P. Santhosh Kumar et al / J. Pharm. Sci. & Res. Vol. 8(5), 2016, 355-359; "Awareness of Quid Associated Oral Lesions among Dental Students"; *ijpsr*.

How to cite this article:

Manya Suresh and Preetha S (2017) 'Oral Submucous fibrosis-Etiopathology A Review Article', *International Journal of Current Advanced Research*, 06(04), pp. 3084-3087.
DOI: <http://dx.doi.org/10.24327/ijcar.2017.3087.0188>
