



## Research article

## A COMPARATIVE STUDY TO EVALUATE EFFICACY OF INTRALESIONAL 5-FLUOROURACIL VERSUS VITAMIN D3 IN MANAGEMENT OF CUTANEOUS WARTS

\*Shruti Gupta, Yatendra Singh Chahar, Karamvir Singh and Akshara Kharabanda

S.N. Medical College, Moti katra, MG Road, Agra 282001

### ARTICLE INFO

#### Article History:

Received 10<sup>th</sup> February, 2023

Received in revised form 22<sup>nd</sup> February, 2024

Accepted 16<sup>th</sup> March, 2024

Published online 28<sup>th</sup> March, 2024

#### Key words:

warts, intralesional, 5-fluorouracil, vitamin D3

### ABSTRACT

**Context:** Warts are caused by Human papilloma virus. Various treatment modalities are present such as electrocautery, chemical cautery and cryotherapy. Immunotherapy is emerging as new treatment option which acts by enhancing the cell-mediated immunity against HPV. **Aims:** To compare the therapeutic efficacy and safety of intralesional 5-Fluorouracil (5-FU) versus intralesional Vitamin D3 in cutaneous warts. **Settings and Design:** Hospital-based interventional prospective study. **Methods and material:** We selected 176 patients with cutaneous warts and randomly divided into two groups of 88 patients each. Group A were treated with intralesional 5-Fluorouracil (50mg/ml) and Group B were treated with intralesional Vitamin D3 (6lac units 15mg/ml). The procedure was repeated at 2 weeks interval up to 5 times or till clearance of lesion. The side effects were noted. **Statistical analysis used:** Statistical Package for Social Sciences (SPSS) software version 25.0. The results were analysed using Chi-Square test and Student's t test. p value of <0.05 was considered significant. **Results:** At the end of therapy, complete cure rates obtained were 82% (72/88) in 5-FU treated patients (Group A) and 64% (56/88) in Vitamin D3 treated patients (group B). **Conclusion:** Intralesional 5-fluorouracil is worth considering as a therapeutic option for the treatment of viral wart is safe, cost-effective, efficacious and lacks serious side-effects.

Copyright© The author(s) 2024. This is an open access article distributed under the Creative Commons Attribution License, which permits unrestricted use, distribution, and reproduction in any medium, provided the original work is properly cited.

### INTRODUCTION

Infection of epidermal cells with the human papillomavirus (HPV) results in cell proliferation and a thickened, warty papule on the skin which cause moderate to extreme discomfort is reported in 51.7% of patients.<sup>1</sup> Current verruca vulgaris research is focusing on immune-manipulation methods to determine their effectiveness. These include 5-fluorouracil,<sup>2</sup> bleomycin,<sup>3</sup> interferons,<sup>4</sup> vitamin D3.<sup>5</sup> 5-Fluorouracil (5-FU) is a fluorinated pyrimidine anti-metabolite, an anti-neoplastic agent that acts by blocking DNA synthesis and produces growth arrest at any stage of the cell cycle.<sup>2</sup> Vitamin D3 is another emerging modality to investigate in the treatment of warts.<sup>5</sup>

### SUBJECTS AND METHODS

#### Study design

It was a hospital based single blinded interventional prospective study, conducted in the department of dermatology over a period of 12 months from July 2021 - June 2022 after obtaining clearance from the Institutional Ethics Committee.

#### Study subjects

All consecutive patients with cutaneous warts were enrolled for the study according to the following exclusion criteria: age below 12 years, active infection, pregnancy, lactation, bleeding disorder and immunosuppression. A washout period of 3 weeks was allowed for patients taking any other treatment for warts.<sup>6</sup>

A detailed history was taken regarding age, sex, duration of warts and previous treatment taken. A detailed cutaneous examination was performed including the site, type, number, size (length, breadth and height) and distant warts if present were noted. Baseline blood investigations were carried out, including CBC, liver function profile and renal function profile.

A total of 176 patients were enrolled. The study population was randomly divided into two groups:

**Group A** consisted of 88 patients treated with intralesional injection of 5-FU.

**Group B** consisted of 88 patients treated with intralesional injection of Vitamin D3.

\*Corresponding author: Shruti Gupta

S.N. Medical College, Moti katra, MG Road, Agra 282001

**Procedure**

Photographs were taken at baseline and at each follow-up visit to support the recorded data.

Group A were injected with a mixture of 20 units (0.5 ml) 2% lidocaine + adrenaline (1:200000) and 10 units 5-fluorouracil (250mg/5ml) in an insulin syringe, at the base of warts, and Group B were injected with 0.5ml 2% lidocaine + adrenaline (1:200000) and then 0.2-0.5 ml of Vitamin D3 (15mg/ml) at the base of wart.

Larger warts were considered for the injection. A maximum of four warts were treated at each session. The injections were repeated at 2 weekly intervals for a maximum of five injections. If complete clearance was achieved before five injections, the treatment was stopped, and patient was followed up for recurrence.

**Follow up**

Patients were evaluated for treatment efficacy and adverse reactions every 2 weeks for first 3 months and monthly thereafter to record for any recurrence for 6 months. Laboratory tests including CBC, liver profile and renal profile was repeated every month.

Clinical response was documented by recording the decrease in number and size of warty lesions at each visit i.e., at 2 weekly intervals for 5 sessions and 6 months after the last injection. Response was graded as:

- Complete clearance if all the warts both treated and distant warts resolve completely.

- Moderate response if >50% to <100% reductions in both size and number of lesions.
- Mild response if 1% and <50% reductions in both size and number of lesions.

**Statistical analysis**

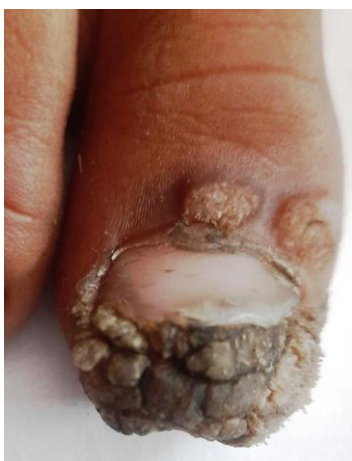After collecting information, data was compiled, tabulated and analyzed using the SPSS software version 25.0. Chi-square test and students t-test were applied and p value <0.05 was considered statistically significant.

**RESULTS**

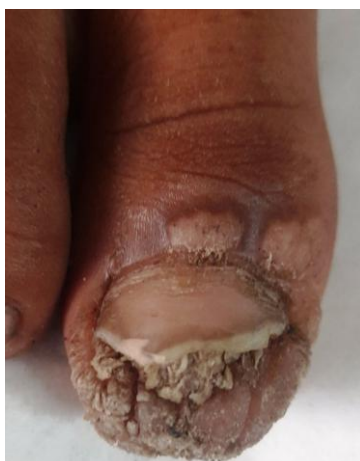The age of patients ranged from 12 to 46 yrs with mean (± SD) 23.59 ± 8.04 yrs. In Group A there were 26 females (29.55%) and 62 males (70.45%) while in Group B there were 32 females (36.36%) and 56males (63.64%). The types of warts included in our study were common warts (48%), palm plantar (41%), periungual (9.6%) and mosaic (1.14%). The baseline parameters (age, sex, distribution of warts) between the two groups were statistically comparable and no significant statistical difference was observed (Table 1). Student's t test was used to test the statistical difference in mean age and duration of warts between the groups. A total of 88 patients in Group A were treated with intralesional 5-FU, out of which 72 cases (81.8%) showed complete clearance and 14 cases (15.9%) showed moderate response (Table 2, fig 4). Of the 88 patients in Group B treated with intralesional vitamin D3, 56 cases (63.6%) showed complete clearance and 30 cases (34%) showed moderate response.

**Table 1** Baseline parameters of study participants

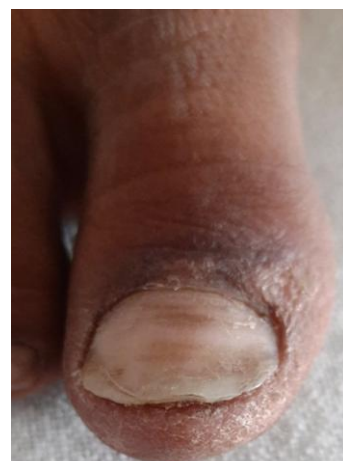Parameter	Group A n=88	Group B n=88	Total n=176	p-value
Age	23.39±7.40	23.80±8.67	23.59±8.04	0.7362
Mean ±SD				
Gender				
Male	62(70.4%)	56(63.6%)	118(67%)	
Female	26(29.5%)	32(36.3%)	58(32.9%)	
Duration(months)	9.5±4.34	9.38±3.09	9.44±3.76	0.832
Mean ±SD				
Symptom				
Pain	38(43.2%)	36(40.9%)		
Cosmetic	50(56.8%)	46(52.2%)		
Bleeding	2(2.3%)	0		
Itching	38(43.2%)	6(6.82%)		
Type of wart				
Common	38(43.2%)	47(53.4%)		
Mosaic	2(2.3%)	0		
Palmoplantar	36(40.9%)	36(40.9%)		
Periungual	12(13.6%)	5(5.68%)		
Distant warts				
Present	22(25%)	14(15.9%)		0.134
Absent	66(75%)	74(84%)		



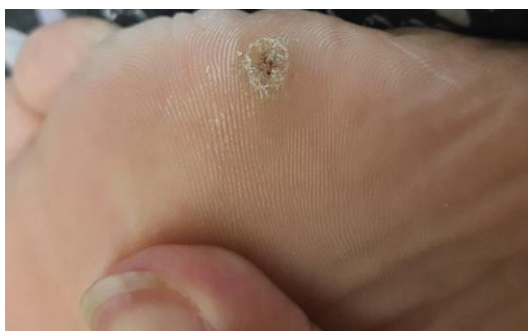**Fig. 1A** Group A P1: at baseline



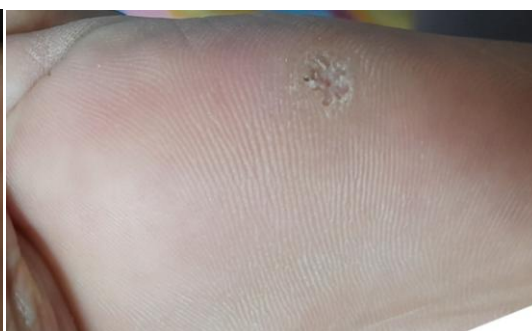**Fig. 1B** Group A P1: at 2<sup>nd</sup> week



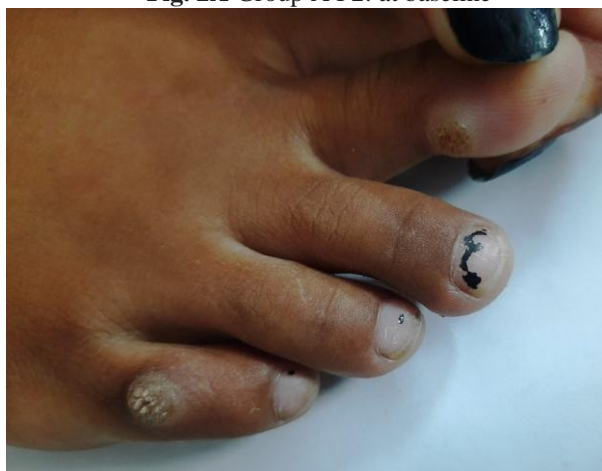**Fig. 1C** Group A P1: at 6<sup>th</sup> week



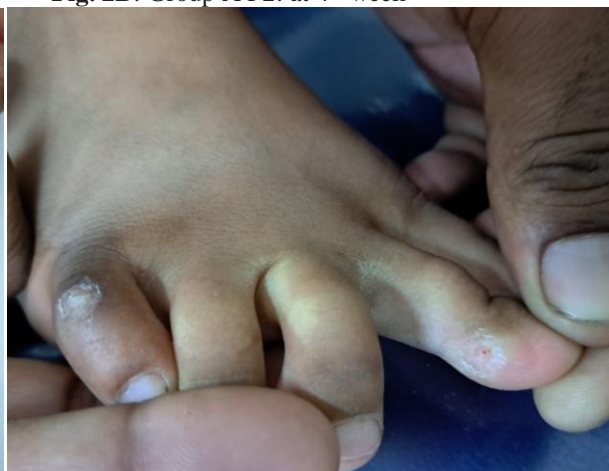**Fig. 2A** Group A P2: at baseline



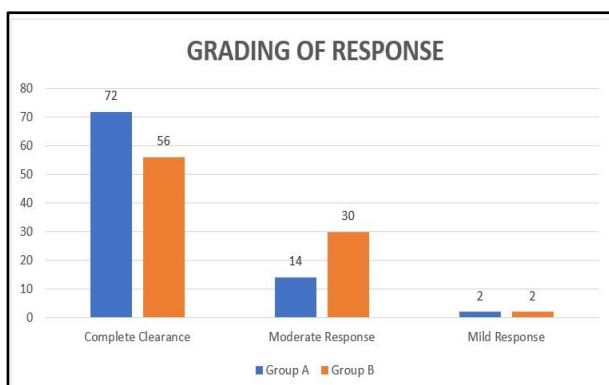
**Fig. 2B:** Group A P2: at 4<sup>th</sup> week



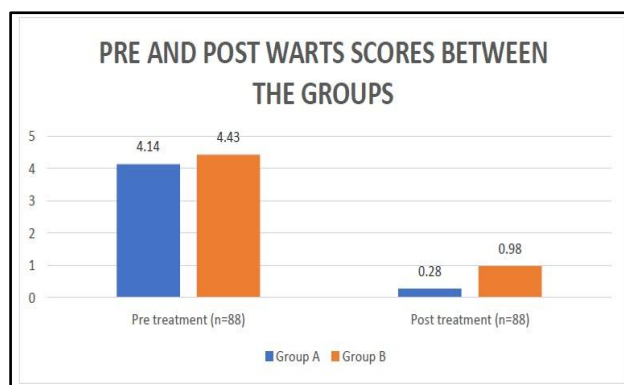
**Fig. 3A** Group B P1: at baseline



**Fig. 3B** Group B P1: at 4<sup>th</sup> week



**Fig. 4** Grading of response



**Fig. 5** Pre and Post treatment wart scores between both groups

**Table 2** Grading of Response

Response	Group A	Group B	$\chi^2$ value	P value
	n=88	n=88		
Complete clearance	72(81.82%)	56(63.64%)	7.8	0.02
Moderate response	14(15.91%)	30(34.09%)		
Mild response	2(2.27%)	2(2.27%)		

Regression of mean number of warts at baseline and each follow-up visit was recorded and evaluated for statistical difference using student's t test. (Table 3)

**Table 3** Wart scores at baseline and follow-up visits

Follow-up	Group A (Mean±SD)	Group B (Mean±SD)	t-value	p value
Baseline	4.14±3.78	4.43±3.10	0.556	0.578
2 <sup>nd</sup> week	2.25±2.12	3.20±2.57	2.675	0.008
4 <sup>th</sup> week	1.81±1.82	2.79±2.04	3.363	0.0009
8 <sup>th</sup> week	0.96±1.12	1.74±1.86	3.37	0.0009
12 <sup>th</sup> week	0.28±0.66	0.98±1.65	3.695	0.0003

Table 4 shows the pre and post treatment regression of mean number of warts in Group A and B. A significant improvement of 93.1% was seen in the number of warts post-treatment in the patients of Group A as compared to patients in Group B where 78.4% regression in the number of warts was observed (p=0.0003). (Fig 5)

**Table 4** Pre and post treatment wart scores

	Pre		Post		t-value	p-value
	Total	Mean±SD	Total	Mean±SD		
Group A	364	4.14±3.78	25	0.28±0.66	-9.437	<0.0001
Group B	405	4.43±3.10	86	0.98±1.65	-9.216	<0.0001
t-value	0.556		3.695			
p-value	0.5786		0.0003			

Side effects such as edema, pigmentation, onycholysis and necrosis were similar in both the groups (Table 5). Most patients complained of pain during injection which subsided over the next 4-5 minutes. The warts regressed with slight hyper pigmentation which cleared during the follow-up period of 6 months.

**Table 5** Complications after treatment

Complain	Group A n=88	Group B n=88	$\chi^2$ value	p value
None	51(57.95%)	61(69.32%)		
Pain	27(30.68%)	20(22.73%)		
PIH	7(7.95%)	3(3.41%)		
Necrosis	1(1.14%)	0		
Onycholysis	2(2.27%)	0		
Edema	0	4(4.55%)	8.2	0.08

We noted that in the Vitamin D3 treated group, the warts present over the anatomically distant sites than the ones treated also started to regress (Table 6).

**Table 6** Effect on distant warts

Effect on patients with distant warts	Group A N=22	Group B N=14	$\chi^2$ value	P value		
Reduction in size/ number	3(13.64%)	8(57.14%)			7.63	0.005
No change	19(86.36%)	6(42.86%)				

**DISCUSSION**

Owing to the pivotal role of the immune system in restricting wart proliferation, intralesional immunotherapy has emerged as a potential therapeutic approach in patients with cutaneous warts. Its action is based on the activation of the patient's immune system which enhances the recognition and eradication of the virus, leading to clearance of primary and distant warts.<sup>7</sup>

Iscimen *et al.*<sup>2</sup> (2004) noted complete response in an average of 70% of those treated with 5-FU. Their study was limited to only common warts and did not include any other type. A study by Yazdanfar *et al.*<sup>8</sup> (2008) showed 64.7% complete response with intralesional 5-FU. Another study carried out by Kannambal *et al.*<sup>9</sup> (2019) recorded a response of 60-63% at 3<sup>rd</sup> visit in common and palmar warts. In the present study, we observed complete response in up to 82% of cases, and moderate response was seen in 16 % of cases. The better response in our study could be the result of higher dose of 5-FU (8-12mg) as compared to previous studies (2-6mg),<sup>8</sup> which was still much less than the systemic therapy to cause any adverse effects.

Aktas *et al.*<sup>5</sup> (2016) were the first to use intralesional vitamin D3 in the treatment of viral warts. They reported complete clearance in 80% of patients. The effect of vitamin D derivatives on warts is claimed to be due to its potential to regulate epidermal cell proliferation and cytokine production.<sup>10,11</sup> In the present study, we gave intralesional Vitamin D3 injection to patients for up to 5 sessions. We noted complete clearance in 56 (64%) patient by the end of 6 month follow-up period. Thirteen patients (14%) however, showed recurrence during the follow-up period and had to be re- treated with further dose of intralesional Vitamin D3.

Raghukumar *et al.*<sup>12</sup> (2017) mentioned clearance in 90% cases while Kavya *et al.*<sup>13</sup> (2016) noted complete clearance in 19 (82.60%) out of 23 patients with palmoplantar warts and 14(77.77%) of 18 patients with verruca vulgaris. The mean number of intralesional injections required for complete clearance was 3.<sup>13</sup> However, in the present study, the mean number of injections of Vitamin D3 taken for complete clearance of warts in Group B was 4.5. In Group A, average number of 5-FU injections for complete clearance was 3.7.

In our study, almost 57% showed complete clearance of distant warts in Group B. It was probably the result of improving immunity due to the immunomodulatory action of Vitamin D3 by increasing the cytokine levels in the blood,<sup>6,10,11</sup> or by inhibiting the expression of interleukin-6

(IL-6), IL-8, tumour necrosis factor (TNF)- $\alpha$  and TNF- $\gamma$  mediated through VDR-dependent pathway (Vitamin D Receptor).<sup>14</sup> The patient number with distant warts was very few and thus small sample size was a limiting factor in assessment of result.

**Financial support:** Nil

**Conflicts of interest:** Nil

## References

1. Ciconte, A., Campbell, J., Tabrizi, S., Garland, S., & Marks, R. (2003). Warts are not merely blemishes on the skin: A study on the morbidity associated with having viral cutaneous warts. *Australasian Journal of Dermatology*, *44*, 169-173.
2. Iscimen, A., Aydemir, E. H., Göksügür, N., & Engin, B. (2004). Intralesional 5-fluorouracil, lidocaine and epinephrine mixture for the treatment of verrucae: A prospective placebo-controlled, single-blind randomized study. *Journal of the European Academy of Dermatology and Venereology*, *18*(4), 455-458.
3. Barkat, M. T., Abdel-Aziz, R. T. A., & Mohamed, M. S. (2018). Evaluation of intralesional injection of bleomycin in the treatment of plantar warts: Clinical and dermoscopic evaluation. *International Journal of Dermatology*, *57*(12), 1533-1537.
4. Pandhi, R. K., Mittal, A., & Gupta, K. L. (1993). Intralesional interferon alpha - 2b in genital warts: A preliminary study. *Indian Journal of Dermatology Venereology and Leprology*, *59*(4), 194-196.
5. Aktas, H., Ergin, C., Demir, B., & Ekiz, Ö. (2016). Intralesional Vitamin D injection may be an effective treatment option for warts. *Journal of Cutaneous Medicine and Surgery*, *20*(2), 118-122.
6. Abou-Taleb, D. A. E., Abou-Taleb, H. A., El-Badawy, O., Ahmed, A. O., Thabiet Hassan, A. E., & Awad, S. M. (2019). Intralesional vitamin D3 versus intralesional purified protein derivative in treatment of multiple warts: A comparative clinical and immunological study. *Dermatologic Therapy*, *32*(1), e13034.
7. Nofal, A., Salah, E., Nofal, E., & Yosef, A. (2013). Intralesional antigen immunotherapy for the treatment of warts: Current concepts and future prospects. *American Journal of Clinical Dermatology*, *14*(4), 253-260.
8. Yazdanfar, A., Farshchian, M., Fereydoonnejad, M., & Farshchian, M. (2008). Treatment of common warts with an intralesional mixture of 5-fluorouracil, lidocaine, and epinephrine: A prospective placebo-controlled, double blind randomized trial. *Dermatologic Surgery*, *34*(5), 656-659.
9. Kannambal, K., Kaviarasan, P. K., Prasad, P. V. S., Poorana, B., & Balajiganesh, J. (2019). Efficacy of intralesional 5-fluorouracil in recalcitrant warts a study at Tertiary Care Centre. *Journal of Medical Sciences and Clinical Research*, *7*(8), 556-560.
10. Imagawa, I., & Suzuki, H. (2007). Successful treatment of refractory warts with topical vitamin D3 derivative (maxacalcitol, 1 $\alpha$ , 25-dihydroxy-22-oxacalcitriol) in 17 patients. *Journal of Dermatology*, *34*(4), 264-266.
11. Rind, T., Oiso, N., & Kawada, A. (2010). Successful treatment of anogenital wart with a topical Vitamin D(3) derivative in an infant. *Case Reports in Dermatology*, *2*(1), 46-49.
12. Raghukumar, S., Ravikumar, B. C., Vinay, K. N., Suresh, M. R., Aggarwal, A., & Yashovardhan, D. P. (2017). Intralesional Vitamin D3 injection in treatment of recalcitrant warts: A novel proposition. *Journal of Cutaneous Medicine and Surgery*, *21*(4), 320-324.
13. Kavya, M., Madegowda, B., & Shweta, B. P. (2016). Intralesional vitamin D3 injection for the treatment of difficult warts. *Journal of Cutaneous and Aesthetic Surgery*, *7*(3), 203-208.
14. AlGhamdi, K., Kumar, A., & Moussa, N. (2013). The role of Vitamin D in melanogenesis with an emphasis on vitiligo. *Indian Journal of Dermatology Venereology and Leprology*, *79*(6), 750-758.

### **How to cite this article:**

Shruti Gupta, Yatendra Singh Chahar, Karamvir Singh and Akshara Kharabanda. (2024). A comparative study to evaluate efficacy of intralesional 5-fluorouracil versus vitamin d3 in management of cutaneous warts. *International Journal of Current Advanced Research*.13(03), pp.2904-2908.

\*\*\*\*\*