



Research Article

ROLE OF SIDDHA IN MANAGEMENT OF DUCHENNE MUSCULAR DYSTROPHY TO REINFORCE THE QUALITY OF LIFE- A PEDIATRIC CASE REPORT

Dr Bhuvanagiri Sathya Sindhuja¹, Injarapu Sankar², Dr Ram Mohan Reddy³, Dr Shweta Tiwari^{4*}¹Patron, Chakrasiddh; ²Chief Healer; ^{3,4}Consultant Dr
^{1,2,3,4}Dept of Siddha Medicine, Chakrasiddh health centre, Hyderabad, India

ARTICLE INFO

Article History:

Received 22nd November, 2023Received in revised form 1st January, 2024Accepted 14th January, 2024Published online 28th January, 2024

Key words:

Duchenne's Muscular dystrophy, Muscle weakness, Creatine kinase, Gower sign, Siddha therapy, Thasaivatham

ABSTRACT

Duchenne muscular dystrophy (DMD) is a progressive muscular disorder characterized by muscle weakness, motor delays, respiratory impairment, and if left untreated can cause loss of ambulation. It is the most typical X-linked disorder of muscular dystrophy primarily affecting male children, with proximal muscle weakness and calf hypertrophy in affected boys. In Siddha literature, DMD symptoms bears a resemblance to Thasaivatham (Muscular Dystrophy) and is explained by increased Vatham. Siddha is an ancient traditional therapy which believes in treating the disease from its root cause from within. Here, we present a case study of a ten-year-old male diagnosed with DMD. From the age of four and half, the patient had difficulty walking for long distances, needed support while climbing stairs, frequent falls, muscle spasms, and had lower extremity weakness on both sides with a reduced range of motion (ROM). Since last one month, the patient is having increased muscle pains & difficulty in breathing, is unable to balance while walking and has decreased strength, stamina, in both lower limbs. Gowers sign was positive which suggested DMD. The main objective of this case is to determine the role of Siddha therapy in management of DMD and is focused mostly on maintaining the range of motion (ROM), and to improve the quality of life of the child. The patient was treated with Siddha therapy utilizing stimulation of Varmam Maruthuvam by pressing (Amartthal) technique and Thokkanam (Massage manipulation) on OPD basis for 45 sessions in two phases. The treatment also included the support of physiotherapy in different sittings for three months for mobility assistance along with yogasanam. A diet designed specially for strengthening the muscles and stamina was advised for further improvement. His CPK-creatinine kinase was 9021 U/L (NV= 25 to 200U/L) which became 5200 U/L post-treatment. The assessment was done on North Star Ambulatory Assessment. He is able to walk long distances (>1km) with faster pace and is able to stand without support for 15 minutes on his own. There is lot of improvement in hand strength & increased range of motions in both legs measured by the goniometer. The child had no frequent falls and strength in lower limbs is seen better. DMD has no permanent cure but by adopting a multi-dimensional treatment approach, including Siddha therapy with dietary modifications, physiotherapy, family support and counselling of patient; the quality of life can be reinforced to much extent. This study presents Siddha therapy as a new treatment option to manage symptoms of DMD, install a confidence in patient and increased stamina to perform his daily life activities thus improving quality of life. **Abbreviations:** Duchenne's Muscular dystrophy (DMD), Range of motion (ROM)

Copyright© The author(s) 2024. This is an open access article distributed under the Creative Commons Attribution License, which permits unrestricted use, distribution, and reproduction in any medium, provided the original work is properly cited.

INTRODUCTION

Duchenne muscular dystrophy (DMD) is a progressive neuromuscular genetic disorder and one of the most severe types of muscular dystrophy [1]. It is an atypical inherited disorder which primarily affects boys between age group 5-25 years [2]. The prevalence of DMD is estimated 1 in every 7500 males [3]. It is an X-linked recessive muscular dystrophy caused by a mutation in the dystrophin gene, which leads to the absence or decrease in dystrophin. The levels of Serum

creatinine kinase are drastically raised than normal laboratory values [4]. 78% cases of DMD are usually inherited from the mother, whereas approximately 22% occurs due to a mutation in the gene for dystrophin [1,5]. DMD patients produce very little or no dystrophin at all in their muscles, and due to its absence, even everyday activity can cause huge damage to the muscle cells. Although it is a genetic disorder, sometimes DMD can be seen in individuals who do not even have a

*Corresponding author: Dr Shweta Tiwari

Consultant Dr, Dept of Siddha Medicine, Chakrasiddh health centre, Hyderabad, India

family history of it suggesting the genes are mutated on their own [5].

In most of the cases DMD is clinically diagnosed at 4-5 years of age, progression of disease may lead to wheelchair dependency by the age of 11-12 year and finally death by 20-25 years [6]. Typically, muscle weakness affects the proximal muscles in DMD and hence begins in the lower limbs first. Proximal-distal weakness is a confirmatory sign at the time of clinical manifestation of DMD [7]. It is characterized by motor impairments, muscle weakness, walking difficulty, waddling, toe-walking, difficulty in climbing stairs and running. Patients use their hands to lift from the floor, is illustrated by Gowers' sign, and is considered a confirmatory sign of having DMD [8]. Pseudo-muscular hypertrophy another sign of DMD, is characterized by enlarged calf muscles leading to muscle fiber hypertrophy [9]. Mild to moderate lordosis is very common in DMD along with other signs [10].

Progressive decrease in muscle strength and stamina leads to limited physical activity. Frequent falls, the need of help to stand up develops fear among patients and further reduces leg activities, resulting in disuse of the musculoskeletal and cardio-respiratory systems [8,9]. The main cause for patients death is confirmed to be either by respiratory failure or cardiac failure, as it is noted that 95% of patients having DMD progresses to cardio-myopathies [11]. Limited physical activity arising due to loss of ambulation hurdles daily life activities leading to a decrease in health-related quality of life (HRQOL) and increase in economic burden.[12]. For prolong life expectancy and slow progression of disease, a high-quality multidisciplinary care is needed [13].

Ongoing studies shows positive effects of many therapies that initiates the relief but there is still no curative therapy available thus, treatment remains symptomatic. All therapy aims to manage DMD by providing an aid to preserve functional abilities for as long as possible [14]. In Siddha literature, DMD symptoms bears a resemblance to Thasaivatham (Muscular Dystrophy) and is explained by increased Vatham in the body [15]. Siddha is an ancient traditional therapy which believes in treating the disease and ailments holistically; aiming not just to prevent pain but to remove the root cause of the disease. It involves healing using a combination of Siddha deep tissue Therapies, mobility exercises, and lifestyle changes along with spiritual healing to completely relieve pain, restore mobility, and help in leading a better life [15]. The spiritual aspect refers to spiritual energy working at a deep level on our spiritual being. The healing involves the transfer of energy; in other words, it is not from the healer him or herself, but the healer links with 'Universal' or Divine energy to channel healing for the mind, body and spirit [16].

Among the deep tissue therapies is Varmam therapy; it is the therapeutic manipulation of Varmam points in which the pranic energy remains concentrated. Manipulation over these points with a particular force for the specified time will release the pranic energy from these points and bring relief to the affected individual by regulating the flow of pranic energy which is obstructed due to assault on specific points (Varmam points) or due to other causes [17].

CASE PRESENTATION

A ten-year-old male diagnosed with DMD presented in the Chakrasiddh in May-2022 with severe muscular pain and difficulty in breathing. The parents reported a history of repeated falls, excessive fatigue, progressive muscle weakness, and inability to climb stairs. He had difficulty walking for long distances, needed support while climbing stairs, muscle spasms, and had lower extremity weakness on both sides with a reduced range of motion (ROM). Since last one month, the patient is having increased muscle pain & fatigue in vigorous physical activities, is unable to balance while walking and has decreased strength, stamina, in both lower limbs. He was unable to keep up with peers during sports and was also C/O pain in hand while writing. This was causing poor performance in school and his self confidence was getting down. Family history details showed no one of his family members having DMD, his parents did not have consanguineous marriage and his one elder brother is healthy.

On examination, Gowers sign was positive which suggested DMD (Fig 1). He was having difficulty while getting up from floor, a waddling gait with enlarged calf muscles were noticed. According to Siddha Manual, DMD is primarily caused when Vatham in body is disturbed or increased and this affects the seven udalthathukal Saaram, Senneer, Oon and kozhuppu. We performed various laboratory investigations. His Vit D levels were lower than normal, MLPA taken out in 2015 showed Deletion of Axon 10-17. CBC reported normal range but, biochemistry analysis showed significantly elevated levels of Creatine kinase, alanine aminotransferase, aspartate aminotransferase, and lactate dehydrogenase (9021 U/L, 223 U/L, 195.4 U/L and 674 µg/dl, respectively) (Table 1). Muscle biopsy results revealed an extensive loss of skeletal muscle fibers that are replaced by fat tissue, and extensive fibrosis noted. ECG and EEG were essentially normal. Therefore, based on history, clinical examination, and investigations, the diagnosis of DMD was established. The motor nerve conduction studies revealed low amplitude compound muscle action potentials throughout, with normal conduction velocities. The history, physical examination findings and elevated creatine kinase/ levels strongly suggested a case for DMD. North Star Ambulatory Assessment (NSAA), a functional scale specifically developed for assessing motor function in DMD, and validated in ambulant DMD children older than 5 years, was used for this patient to access the improvement pre and post treatment.

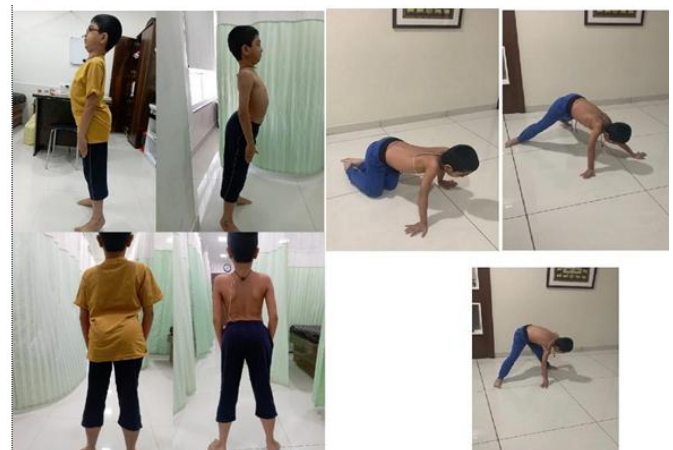

Fig 1: Depicting mild Scoliosis and Gower's Sign (DMD)

Table 1: Investigation Reports

Parameters	Patients Value	Parameters	Patients Value
CPK	9021	Alanine aminotransferase	223 U/L
Vit D	14.21	Aspartate aminotransferase	195.4 U/L
MLPA	Deletion of Axon 10-17	lactate dehydrogenase	674 U/L

TREATMENT PROTOCOL

After proper history and examination, 40sessions of Varmam therapy were planned, each with 20days and at an interval of 45days. Siddha procedures like Thokannam (pressure manipulation) and Varmam Maruthuvam along with Yoga Maruthuvam & Physio exercises were performed for all 40 days [19]. Parents of patient were counseled from time to time to monitor and help child to understand the condition. Regular monitoring by a Nutritionist regarding his weight and muscle loss or gain was done along with Physiotherapist who worked on strengthening core muscles. Special therapies of points advised are mentioned in Table 3. The chief healer of Chakrasiddh did 4 special sessions of the patient in relation to energy sessions as she is a firm believer that people carry around unhelpful energetic burdens (past or carriers from parents) which can be alleviated by healing [16]. Whenever such sessions were conducted, the feedback from patient was very positive and he could feel more fresh and light.

Table 3: Special Therapies

Xxxx

In initial week, patient had lots of pain as he had capped his steroids but could see difference in his stiffness. He could notice the level of strength in his legs was improved and he was able to walk for 20 mins without any help. He was able to take steps and his confidence boosted up. Since, the treatment included a break time for 2 months for working on muscular strength, he was temporarily given break.

After break, his treatment focused mainly on improving his quality of life. Work was started on strengthening his hands and legs. There was stiffness in his back due to hyperlordosis which was a hurdle in sleeping but there was vast improvement in pain intensity while performing activities from 9 (severe) to 6 (moderate) on VAS. The treatment was given to him for 20 days in 2nd phase.

OBSERVATION AND RESULTS

CPK level was reduced noticeably from 9021 U/L to 5200 U/L, mentioned in Table 2. Along with improvement in CPK levels, improvement in symptoms was also appreciated by the patient. The assessment was done on NSSA on different symptoms (Table 3) .After 1st sitting, patient reported mild relief in generalized weakness and walking was mildly improved. Though the patient was still unable to sit in squatting position, but his H/O frequent falls decreased and on completion he had no falls. Patient also appreciated relief in calf muscle pain and tightness. Mild improvement was also seen in picking up weights and sleeping straight with no disturbance. Walking was improved, and he is able to walk long distances (>1km) with faster pase and is able to stand without support for 15 minutes on his own. Patient could

walk or run without falling. Patient reported improvement in being able to stand from sitting position. There is lot of improvement in hand strength & increased range of motions in both legs measured by the goniometer. Especially power in left hand (patient is left hander) was improved as parents told about his exam in which he wrote for 3 hours while earlier he could barely write for 15 mins. His self confidence and speech was improved.

The X-rays taken out after 3 months post treatment showed improved hyperlordosis condition (Fig 2)

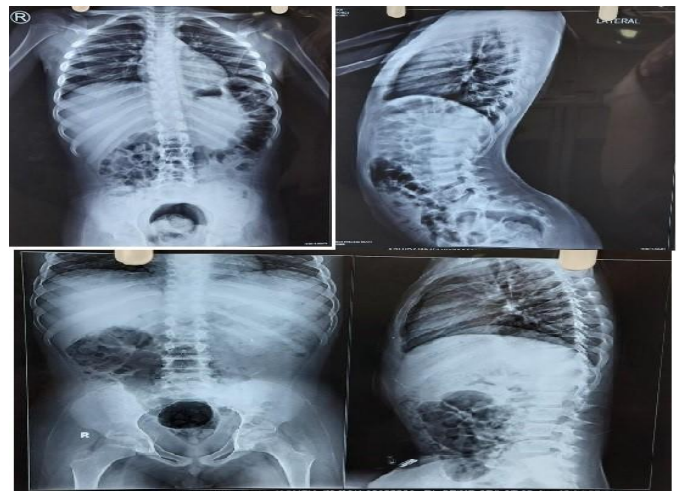


Fig 2: X-Ray (Pre and Post treatment)

Table 2: Investigation Reports

Parameters	Value Before treatment	After treatment
CPK	9021 U/L	5200 U/L

DISCUSSION

Duchenne muscular dystrophy is the most common and severe form of muscular dystrophy [1]. It is a genetic or inherited disorder, primarily affecting boys between age group 5-25 years [2]. The prevalence of DMD is estimated 1 in every 7500 males [3]. DMD manifests as weakness affecting proximal muscles, typically that of lower limbs initially [6]. Gower’s sign, toe walking, waddling gait and hyperlordosis are the later features which put an emotional as well as monetary burden to patients [7]. It is seen most children having DMD are confined to wheelchair by the age of 12-15 years. No specific treatment for the same exists.

In Siddha no exact correlation can be found, however there are certain references in classical texts which show similarity to DMD. In Yugi Vaidhya Chinthamani book, he mentioned about Thasaivatham (Muscular Dystrophy) in his book which bears resemblance to symptoms of DMD [15]. He has explained about the its cause due to increased Vatham. The seven udalthathukal Saaram, Senneer, Oon and kozhuppu gets affected in such cases [16]. Such cases can be treated by multidimensional approach involving mind, body and soul. The treatment involves therapies like Varmam therapy in which there is therapeutic manipulation of Varmam points in which the pranic energy remains concentrated. Manipulation over these points with a particular force for the specified time will release the pranic energy from these points and bring

relief to the affected individual by regulating the flow of pranic energy [19].

Ullthodai Varmam, Komberikalambam and Mannai Varmam points helped the patient in strengthening his core muscles and helped in increasing his stamina [20]. Energy sessions in Spiritual healing helped the patient to release unhelpful energetic burdens, in other words he was relaxed by easy flow of energy [18]. As mentioned in observations, noticeable improvement was found in patient's gait; he could walk or run without falls. His parents were quite satisfied with his performance in school and in his physical activities which was the main aim of our treatment.

CONCLUSION

Duchenne muscular dystrophy is a neuromuscular disorder. This article is an attempt to present a case of Duchenne muscular dystrophy, effectively managed by Siddha principles. DMD has no permanent cure in modern medicine but by adopting a multi-dimensional treatment approach, including traditional Siddha therapy with dietary modifications, physiotherapy, family support and counselling of patient; the quality of life can be reinforced to much extent. Whether Siddha therapies can improve the lifespan of patient or not, is a subject of research but, by reducing the intensity of symptoms, it can be a new treatment option for DMD. The traditional therapy installed an impact on confidence in patient, improvement in his sufferings, increased stamina all indicating improved lifestyle of the patients.

References

1. Birnkrant, D. J., Bushby, K., Bann, C. M., et al. (2018). Diagnosis and management of Duchenne muscular dystrophy, part 1: diagnosis, and neuromuscular, rehabilitation, endocrine, and gastrointestinal and nutritional management. *Lancet Neurology*, 17, 251-267. [https://doi.org/10.1016/S1474-4422\(18\)30024-3](https://doi.org/10.1016/S1474-4422(18)30024-3)
2. Hoffman, E. P., Brown, R. H. Jr., & Kunkel, L. M. (1987). Dystrophin: The protein product of the Duchenne muscular dystrophy locus. *Cell*, 51, 919-928.
3. Richard, A., Thompson, M. D., Paul JV Jr., & Cleveland, M. D. (1959). Serum aldolase in muscle disease. *AMA Arch Intern Med*, 103(4), 551-564.
4. Chamberlain, J. S., Pearlman, J. A., Muzny, D. M., Gibbs, R. A., Ranier, J. E., et al. (1988). Expression of the murine duchenne muscular dystrophy gene in muscle and brain. *Science*, 239, 1416-1418.
5. Tinsley, J. M., Potter, A. C., Phelps, S. R., Fisher, R., Trickett, J. I., et al. (1996). Amelioration of the dystrophic phenotype of mdx mice using a truncated utrophin transgene. *Nature*, 384, 349-353.
6. Mah, J. K., Selby, K., Campbell, C., Nadeau, A., Tarnopolsky, M., McCormick, A., et al. (2011). A population-based study of dystrophin mutations in Canada. *The Canadian Journal of Neurological Sciences*, 38(3), 465.
7. Ryder, S., Leadley, R., Armstrong, N., Westwood, M., de Kock, S., Butt, T., et al. (2017). The burden, epidemiology, costs and treatment for Duchenne muscular dystrophy: an evidence review. *Orphanet Journal of Rare Diseases*, 12(1).
8. Martini, F. H. (1998). *Fundamentals of Anatomy and Physiology* (4th ed.). Prentice Hall Inc. Simon and Schuster. (pp. 148-150).
9. Flanigan, K. M. (2014). The Dystrophinopathies. In: Hilton-Jones, D., Turber, M. R. (Eds.), *Oxford Textbook of Neuromuscular Disorders*. Oxford University Press. (pp. 2076-2078).
10. Martini, F. H. (1998). *Fundamentals of Anatomy and Physiology* (4th ed.). Prentice Hall Inc. Simon and Schuster. (pp. 152-155).
11. Bushby, K., Finkel, R., Birnkrant, D. J., Case, L. E., Clemens, P. R., Cripe, L., et al. (2010). Diagnosis and management of Duchenne muscular dystrophy, part 1: diagnosis, and pharmacological and psychosocial management. *Lancet Neurology*, 9(1), 77-93.
12. Ryder, S., Leadley, R., Armstrong, N., Westwood, M., de Kock, S., Butt, T., et al. (2017). The burden, epidemiology, costs and treatment for Duchenne muscular dystrophy: an evidence review. *Orphanet Journal of Rare Diseases*, 12(1).
13. Schreiber-Katz, O., Klug, C., Thiele, S., Schorling, E., Zowe, J., Reilich, P., et al. (2014). Comparative cost of illness analysis and assessment of health care burden of Duchenne and Becker muscular dystrophies in Germany. *Orphanet Journal of Rare Diseases*, 9(1).
14. Kieny, P., Chollet, S., Delalande, P., Le Fort, M., Magot, A., Pereon, Y., et al. (2013). Evolution of life expectancy of patients with Duchenne muscular dystrophy at AFM Yolaine de Kepper centre between 1981 and 2011. *Annals of Physical and Rehabilitation Medicine*, 56(6), 443-454.
15. Kuppusamy Mudaliar, K. N., & Mookadaipu. (1987). Siddha Maruthuvam. Tamil Nadu Siddha Maruthuva Variyam. (pp. 192-200).
16. Agnivesha, Charaka. (2008). *Charaka Samhita*. Rajeshwardatta Shastri (Ed.). Chaukhamba Bharati Academy. (pp. 202).
17. Charman, R. A. (2000). Placing Healers, Healees, and Healing into a Wider Research Context. *The Journal of Alternative and Complementary Medicine*, 6(2), 177-180.
18. Angelo, J. (2001). *Your Healing Power: A Comprehensive Guide to Channelling Your Healing Energies*. Piatkus Publishers.
19. Rajendran, T. (2006). *Text Book of Varmam and Massage Science*. Varma Ariviyal Aayvu Maiyam, Kanyakumari.
20. Thyagarajan, R. (1976). *Varmavithi*. Arulmigu Palani Thandayuthabahni Swamy Thirukkivil Siddha Maruthuva Nool Veliyeettu Kuzhu, Madras.

How to cite this article:

Bhuvanagiri Sathya Sindhuja, Injarapu Sankar, Ram Mohan Reddy, Shweta Tiwari. (2024), Role of Siddha in Management of Duchenne Muscular Dystrophy to Reinforce the Quality of Life- a Pediatric Case Report. *International Journal of Current Advanced Research*. 13 (1), pp. 2769-2772.