



Research Article

ADRENAL MYELOLIPOMA IN A YOUNG FEMALE PATIENT: A CASE REPORT

Sumiti Gupta, Pooja Rathee\*, Rachana, Navneet Kaur, Renuka Verma and Sunita Singh

Department, of Pathology, Pt. B.D. Sharma, PGIMS, Rohtak

ARTICLE INFO

Article History:

Received 06<sup>th</sup> May, 2023

Received in revised form 14<sup>th</sup> June, 2023

Accepted 23<sup>rd</sup> July, 2023

Published online 28<sup>th</sup> August, 2023

Key words:

Adrenal, myelolipoma, rare, hematopoietic elements, liposarcoma.

ABSTRACT

Adrenal myelolipoma is a rare, benign, non-functioning mass that occurs in the adrenal gland. It is composed of an admixture of hematopoietic elements and mature adipose tissue, similar to bone marrow. Most patients are asymptomatic, though some present with pain or endocrine dysfunction. Imaging studies has led to an increased rate of detection of myelolipoma in the recent years. It is important to recognize this entity since they can attain massive sizes leading to pressure symptoms and need to be differentiated from the malignant tumors like liposarcomas. Few cases of adrenal myelolipoma have been reported in the literature. We present a case of adrenal myelolipoma in a 34year old female who presented with complaint of abdominal pain and discuss its histopathology findings.

Copyright© The author(s) 2023. This is an open access article distributed under the Creative Commons Attribution License, which permits unrestricted use, distribution, and reproduction in any medium, provided the original work is properly cited.

INTRODUCTION

Adrenal myelolipoma is a rare, benign, non-functioning mass of the adrenal gland.<sup>1</sup>It is often asymptomatic, discovered incidentally and falls within the scope of adrenal incidentalomas.<sup>2</sup> It usually occurs as a single, unilateral lesion, ranging from 1 to 34cm.<sup>3</sup> Myelolipomas can occur at various sites, especially in the retroperitoneum, pelvis, mediastinum, and paravertebral region.<sup>1</sup> The pathogenesis is believed to be either metaplastic changes in the mesenchymal cells or over stimulation by adrenocorticotrophic hormone (ACTH).<sup>3</sup> Histologically, these tumors are composed of an admixture of hematopoietic elements and mature adipose tissue, similar to the elements of the bone marrow.<sup>1</sup>

Radiologically, adrenal myelolipomas may mimic other fat containing retroperitoneal lesions, like liposarcoma, teratoma, and extramedullary hematopoiesis.<sup>2</sup>

Small myelolipomas (<4 cm in diameter) are usually asymptomatic but become symptomatic as the size increases, due to mass effect or hemorrhage. Size-related pressure on vital organs can cause back or abdominal pain, high blood pressure, blood in urine, or pain at the site of the tumor. Complication of adrenal myelolipoma include spontaneous retroperitoneal haemorrhage.<sup>4</sup>

We report the case of adrenal myelolipoma in a 34year old female presented with complaint of abdominal pain and discuss the histological findings.

Case presentation

CASE HISTORY

A 34year old female presented with complaint of abdominal pain, fullness of stomach for one year with no history of fever, hematuria, pyuria, diabetes mellitus and hypertension.

Review of the patient's past medical history revealed migraine for which patient was on medication for 10years. MRI Brain showed a calcified granuloma with minimal gliosis in the right frontal lobe.

Laboratory investigations

Lab investigations carried out show haemoglobin 10.8g/dL, deranged renal function test, decreased serum aldosterone, normal urine cortisol and increased urine metanephrines.

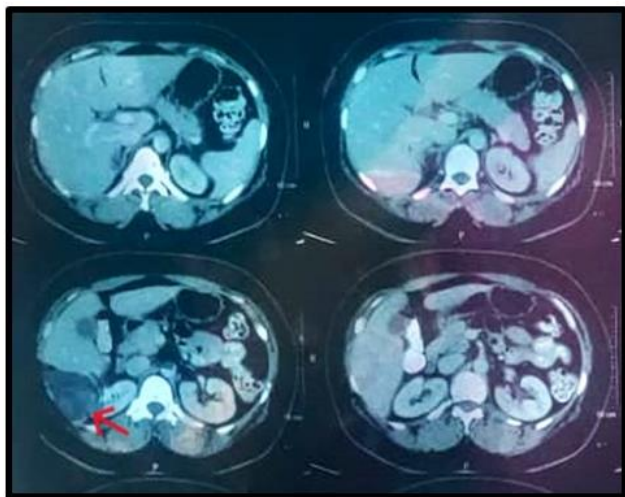
Radiology investigation

On radiology, USG abdomen revealed a hyperechoic lesion in the right suprarenal region. CECT abdomen and pelvis showed a small non-enhancing hypodense lesion with fat density measuring approximately 22X18mm in right adrenal gland. (Figure1) A radiological diagnosis of adrenal adenoma was made.

An open right adrenalectomy surgery was planned and the specimen was sent to the department of pathology for histopathological examination.

\*Corresponding author: Pooja Rathee

Department, of Pathology, Pt. B.D. Sharma, PGIMS, Rohtak

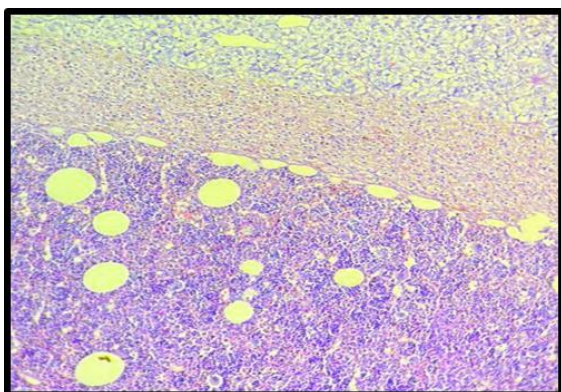


**Figure 1** Computed tomography scan of the adrenal myelolipoma. On computed tomography, adrenal myelolipomas exhibit distinct characteristics, with most of the mass showing fat attenuation.

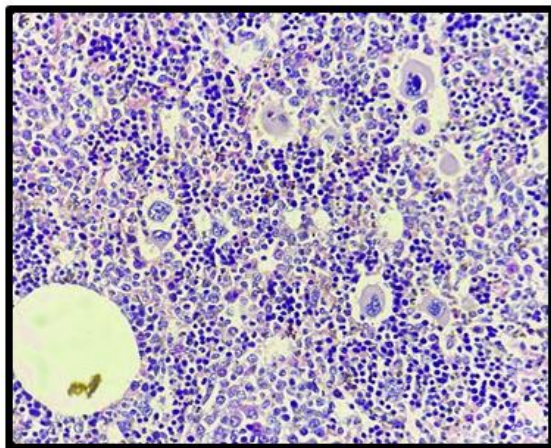
### Histopathological examination

Received a grey brown to tan coloured soft tissue piece measuring 2.5X2.2X1.6cm. Cut surface showed a well circumscribed grey brown lesion identified measuring 2.0X2.0X1.3cm.

Microscopic examination showed a well demarcated lesion comprising of mature adipocytes and extramedullary trilineage hematopoietic cells with full maturation with a markedly increased number of megakaryocytes. Adjacent adrenal tissue showed no significant pathological change. (Figure 2 and 3)



**Figure 2** Photomicrograph showing encapsulated myelolipoma surrounded by rim of compressed adrenal cortical tissue.



**Figure 3** H&E stained section show myelolipoma comprising of hematopoietic cells and mature fat. Increased megakaryocytes are prominent on high power.

A histopathological diagnosis of adrenal myelolipoma was made.

### DISCUSSION

Adrenal myelolipoma was described for the first time in 1905 by Gierke, and owes its name to Oberling.<sup>2</sup> These are the second most common adrenal incidentalomas after adrenal adenomas. Extra-adrenal sites for myelolipomas are rare and include the retroperitoneum, thorax and pelvis.<sup>3</sup> They are more commonly seen between the fifth and seventh decade of life, without sex predilection, are mostly unilateral and rarely exceeds 4 cm. The right adrenal gland involvement is more common. Very large and bilateral tumors occurrence is noted in about 10% of cases.<sup>2</sup>

Clinically, it can be found associated with Cushing's syndrome, hyperaldosteronism, or congenital adrenal hyperplasia.<sup>2</sup> Etiopathogenesis is hypothesised to be metaplasia of adrenal cortical cells into reticuloendothelial cells in response to infection, chronic stress or degeneration of the adrenal gland.<sup>5</sup>

Acute hemorrhage is the most frequent complication seen with large myelolipomas that can present as pain, nausea, vomiting, hypotension, and anemia.<sup>4</sup>

The ultrasound of an adrenal myelolipoma typically shows a hyperechoic mass with hypoechoic parts of myeloid tissue. Due to tumor's non-uniform architecture, calcification and haemorrhage, diagnosis through imaging alone is difficult.<sup>3</sup> The Computed tomography is the most sensitive test because it can show an encapsulated adrenal mass with tissue density equivalent to fat.<sup>2</sup> MRI could be added when a differential diagnosis is required or a diagnosis is particularly difficult.<sup>3</sup> Imaging differentials include lipoma and liposarcoma, adrenal cortical adenoma, adrenal carcinoma and upper pole renal angiomyolipoma.<sup>6</sup>

A percutaneous fine-needle biopsy provides a safe and effective tool in making diagnoses when radiological findings are inconclusive.<sup>4</sup> On, histopathological examination, these tumors are predominantly composed of mature adipose tissue intermixed with mature trilineage hematopoietic(erythroid, myeloid and megakaryocyte) elements.<sup>6</sup>

Treatment is generally defined by the size and symptoms of the tumor. For those greater than 7–10 cm, surgery is recommended due to its high risk of spontaneous rupture retroperitoneal hemorrhage.<sup>2</sup>

### CONCLUSION

Myelolipomas are uncommon, benign tumors which typically occur in the adrenal glands and consist of mature adipose tissue and benign hematopoietic components. Although adrenal myelolipoma is rare, physicians should be familiar with this entity and follow the most appropriate treatment.

### References

1. Kim DS, Lee JW, Lee SH. Spontaneous rupture of adrenal myelolipoma as a cause of acute flank pain: A case report. *World J Clin Cases*. 2021 Aug 6;9(22):6552-6.
2. Rkik M, Fadil Y, Elidrissi O, Dakir M, Debbagh A, Aboutaieb R. Geant adrenal myelolipoma: A case

- report with literature review. *Urol Case Rep.* 2020 Dec 18;35:101541.
3. Park SY, Kwak MK, Kim HJ, Park HK, Suh KI, Yoo MH, *et al.* Case report of a bilateral adrenal myelolipoma associated with Cushing disease. *Medicine (Baltimore).* 2017 Dec;96(52):e9455.
  4. Sethi S, Thakur S, Jacques S, Aoun HD, Tranchida P. Myelolipoma of the Pelvis: A Case Report and Review of Literature. *Front Oncol.* 2018 Jul 3;8:251.
  5. Rahoui M, Ouanes Y, Chaker K, Dali KM, Bibi M, Sellami A, *et al.* Giant adrenal myelolipoma in a young female patient: A case report. *J. Surg. Case Rep.* 2022 May 5;2022(5):1-2.
  6. Katsoulis IE, Dafnis AN, Sourouppi C, Katsaounis D, Boti E, Arnogiannaki N. A large adrenal myelolipoma: Case report and review of the literature. *J. Surg. Case Rep.* 2023 June 07; 2023(6):1-3.

**How to cite this article:**

Sumiti Gupta *et al* (2023) 'Adrenal Myelolipoma in a Young Female Patient: A Case Report', *International Journal of Current Advanced Research*, 12(08), pp. 2455-2457. DOI: <http://dx.doi.org/10.24327/ijcar.2023.2457.1534>

\*\*\*\*\*