



**CASE REPORT**

**TUBERCULOSIS OF ANKLE – A CASE REPORT**

**Shrihari L K., Sunil Manual., Manjunath Japatti and Rajath H P**

Department of Orthopaedics, SDM College of Medical Sciences and Hospital, Dharwad

**ARTICLE INFO**

**Article History:**

Received 8<sup>th</sup> December, 2016

Received in revised form 19<sup>th</sup> January, 2017

Accepted 12<sup>th</sup> February, 2017

Published online 28<sup>th</sup> March, 2017

**Key words:**

Ankle tuberculosis, arthroscopy, anti-tubercular therapy

**ABSTRACT**

Tuberculosis(TB) still remains a leading infection, causing death and disability worldwide. Osteoarticular tuberculosis of the ankle joint is rare, and diagnostic delays are common with this condition. Tuberculosis of ankle is an uncommon presentation of skeletal tuberculosis. The uncommon site, lack of awareness, and ability to mimic other disorders clinically and on radiographs, leads to diagnostic and therapeutic delays.

Relating to this we present a case report of 30 year old male patient with complaints of pain and swelling of left foot and ankle from 6 months which after preliminary investigation was suspected as tuberculosis and was confirmed by biopsy. Patient was treated with arthroscopy and clearance of ankle joint, ankle was immobilized with a below knee cast and he was started on anti-tubercular therapy of four drug regimen. At 9 months follow up the patient is asymptomatic with full range of ankle movements and mobilizing full weight bearing.

Objective of this case report is to present a case of isolated tuberculosis of ankle joint which is a rare presentation of extra-pulmonary tuberculosis and consideration of this diagnosis in chronic ankle and foot pain.

Copyright©2017 **Shrihari L K et al.** This is an open access article distributed under the Creative Commons Attribution License, which permits unrestricted use, distribution, and reproduction in any medium, provided the original work is properly cited.

**INTRODUCTION**

Tuberculosis has been known to mankind since the dawn of human civilization but still remains a major health problem in India and the developing countries.

In India pulmonary tuberculosis is the most common form of tuberculosis accounting for 75-90% of all types of TB. Extra-pulmonary tuberculosis constitutes 10-25% of TB cases and accounts for more than 50% of all cases of TB in HIV positive patients.<sup>1</sup>

In extra-pulmonary tuberculosis involvement of musculoskeletal system is only 1-2% out of which major proportion of involvement was seen in spine and weight bearing joints such as hip and knee. The incidence of ankle tuberculosis was found to be less than 5% of all osteoarticular tuberculosis. Although there is extensive literature on osteoarticular tuberculosis, there have been few studies on the involvement of the foot and ankle. Ankle tuberculosis is uncommon and can mimic a wide range of acute and chronic conditions like pyogenic osteomyelitis, inflammatory arthritis, osteochondrosis, charcotarthropathy, and malignancy arising from bone and soft tissue.<sup>[1,2,3]</sup> If diagnosed at earliest a lot of time can be saved, treatment can be instituted early with a very good outcome. However its unusual symptomatology and presentation explains the delay in diagnosis, treatment and poor outcome.

\*Corresponding author: **Shrihari L K**

Department of Orthopaedics, SDM College of Medical Sciences and Hospital, Dharwad

**Case Report**

30 years male patient presented in our OPD with complaints of pain and swelling in left ankle and foot for 6 months, with inability to bear weight on affected limb. There was no associated history of trauma, fever, long standing cough or weight loss. Preliminary investigations were normal which showed no raised ESR, other parameters were within normal limits. X-ray of the ankle showed features of diffuse soft tissue cellulitis with irregular articular surface (Fig1). Patient was further investigated with MRI which suggested diffuse synovial thickening with enhancement, mild collection around posterior aspect of ankle joint suggestive of synovitis and contiguous involvement with diffuse edema of distal tibia, fibula, talus and calcaneus with joint effusion suggesting infective pathology (fig-2). Arthroscopy, joint clearance and biopsy was done which on histopathological examination showed multiple granuloma and caseating necrosis which confirmed our diagnosis to be tuberculosis of ankle joint. TB-PCR of the sample was positive for tuberculosis. Patient was on 4 drug regime for 9 months along with symptomatic treatment. Post operatively ankle was immobilized with a below knee POP cast for 6 weeks.

Physiotherapy was started after 6 weeks of surgery and patient was followed up monthly for the first three months and then for every three months till the completion of the chemotherapy course. Partial weight bearing was allowed after six weeks postoperatively and full weight bearing after three months postoperatively. At the end of six months anti-TB therapy, the patient had no pain while walking and was

able to perform daily activities without restrictions. Further improvement was observed at 9 months at the completion of chemotherapy.

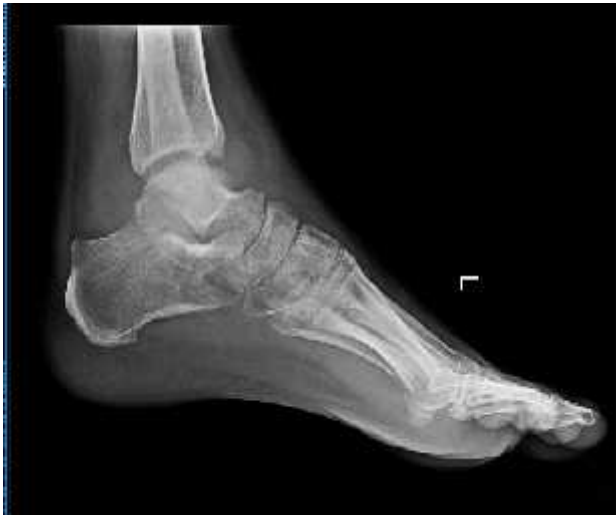

Fig 1 X Ray of ankle with foot showing soft tissue shadow and articular irregularity of ankle

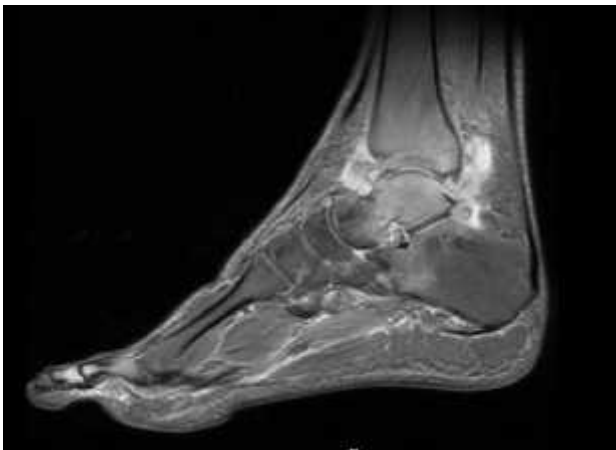


Fig 2 MRI of ankle showing diffuse synovial thickening around the ankle joint

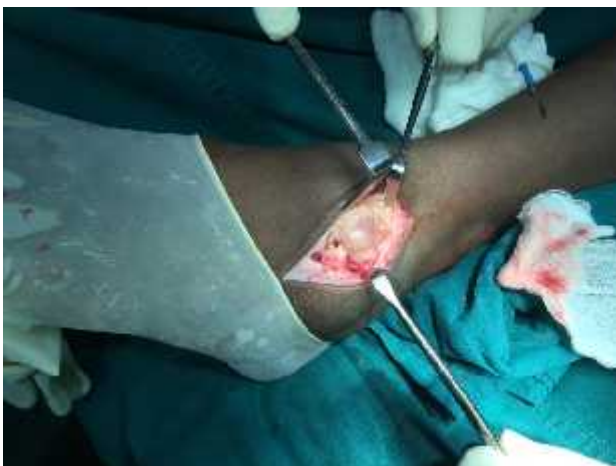

Fig 3 Intra operative image showing arthroscopy of ankle joint with anterio lateral approach

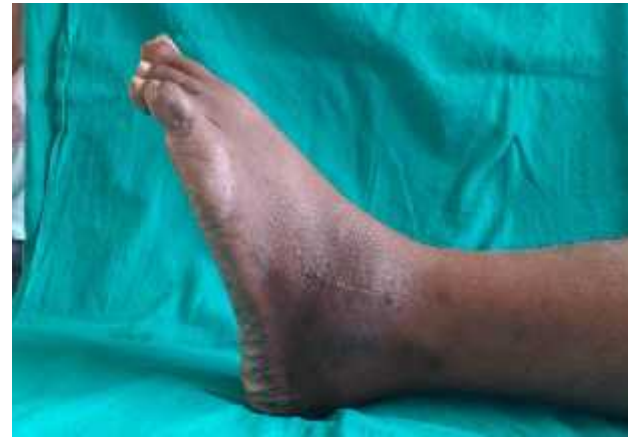

Fig 4 At 6 weeks post-surgery, reduced swelling and stiff ankle which was managed with physiotherapy.

## DISCUSSION

Tuberculosis still remains the leading infectious disease encountered in developing countries and has been a major cause of morbidity and disability with major economic burden on health system. Osteoarticular tuberculosis (TB) represents 1–5% of all cases of tuberculous disease and 10–18% of extra-pulmonary involvement with spine being the most commonly affected followed by major weight bearing joints. Ankle tuberculosis has been a rare entity and account for only 1% of musculoskeletal tuberculosis which was in accordance to study of Dhillon et.al.

Diagnosis of ankle tuberculosis is difficult as it is detected in late stage. Most common symptoms includes pain, swelling and stiffness, while swelling with fullness around malleoli and tendoachilis insertion, restricted plantar flexion of ankle joint are the important signs of ankle TB. There may be discharging sinus or non-healing ulcer with secondary infection. Most commonly involved bones are calcaneum, talus, first metatarsal and navicular. Mid-tarsal joint is the most commonly affected joint in this disease. Pulmonary involvement is uncommon and usually present in less than 50% of cases.<sup>[4,5]</sup>

X-ray is rarely diagnostic until late stage, MRI should be done on high suspicion of ankle tuberculosis as signs of bone destruction and osteolysis can be seen but diagnosis is confirmed only by histopathological examination of bone or soft tissue taken from infected site. Treatment is usually conservative with ATT for 9-20 months with immobilization of affected joint by cast. In our case tubercular drugs were advised for 9 months as recurrence is higher after shorter course.<sup>[6,7]</sup> As, results of conservative treatment are very good hence surgical intervention (debridement and curettage, excision of sequestrated/destroyed bones and arthrodesis) is reserved only for failure of conservative therapy. In our case arthrotomy and biopsy for histopathological examination and TB PCR was done as diagnostic and therapeutic mode of management. Patient was reviewed every month initially for 3 months where clinical signs of healing such as decreased pain and swelling of ankle were noted. All the above clinical findings are evident as early as 6 weeks, but radiological signs of healing are evident after 3 months of treatment. Weight bearing and gait training was initiated at 6 weeks post operatively.

## CONCLUSION

Tuberculosis of ankle though rare needs high level of suspicion, even in absence of classical constitutional symptoms and should always be considered as a differential diagnosis in cases of chronic ankle and foot pain. Early diagnosis and initiation of treatment leads to good outcomes.

## List of Abbreviations

TB - Tuberculosis. MRI - Magnetic resonance imaging, PCR- Polymerase chain reaction.

## References

1. Tuli SM. Tuberculosis of the skeletal system (bones, joints, spine and bursal sheaths) 4th ed. New Delhi: Jaypee Brothers Medical Publishers (P) Ltd; 2010. pp. 131-9
2. Dhillon MS, Nagi ON. Tuberculosis of the foot and ankle. *Clin Orthop Relat Res* 2002. 2002 May; 398:107-13–107-3. [PubMed]
3. Golden MP, Vikram HR. Extrapulmonary tuberculosis: An overview. *Am Fam Physician*. 2005; 72:1761-8. [PubMed]
4. Mariconda M, Cozzolino A, Attingenti P, Cozzolino F, Milano C. Osteoarticular tuberculosis in a developed country. *J Infect*. 2007; 54:375–80. [PubMed]
5. Hakimi M, Hashemi F, Mirzaie AZ, Pour AH, Kosari H. Tuberculous osteomyelitis of the long bones and joints. *Indian J Pediatr*. 2008; 75:505–8. [PubMed]
6. Dhillon M S, Aggarwal S, Prabhakar S, BachhalV. Tuberculosis of the foot: An osteolytic variety. *Indian J Orthop*. 2012 Mar-Apr; 46(2): 206–211. doi: 10.4103/0019-5413.93683

### How to cite this article:

Shrihari L K et al (2017) 'Tuberculosis Of Ankle – A Case Report', *International Journal of Current Advanced Research*, 06(03), pp. 2500-2502.  
DOI: <http://dx.doi.org/10.24327/ijcar.2017.2502.0037>

\*\*\*\*\*