

CAN TES IMPROVE A SQUINT?

Ibrahim Sahbaz¹ and Umur A. Kayabasi²

¹Uskudar University / Istanbul

²Moodist Hospital/ Istanbul

ARTICLE INFO

Article History:

Received 11th March, 2017

Received in revised form 8th

April, 2017

Accepted 24th May, 2017

Published online 28th June, 2017

Key words:

Transcorneal electrical stimulation,
amblyopia.

ABSTRACT

Objective: To observe whether transcorneal electrical stimulation (TES) can be used in amblyopia.

Methods: A 12 years old boy was with amblyopia related esotropia was treated by TES for 10 days.

Results: Improvement in VA and esotropia after TES was detected.

Discussion: Recent reports show some improvement in amblyopia after the stimulations using transcranial magnetic stimulation devices. Our patient also improved after TES and we believe that esotropia also improved due to the gained binocularity.

Conclusion: TES may be used in amblyopia.

Copyright©2017 Ibrahim Sahbaz and Umur A. Kayabasi. This is an open access article distributed under the Creative Commons Attribution License, which permits unrestricted use, distribution, and reproduction in any medium, provided the original work is properly cited.

INTRODUCTION

Considering many degenerative retinal and optic nerve diseases there is no proven treatment to stop the course of deterioration. As a result, several million people in the world become blind every year and in the recent years there has been a trend to use transcorneal electrical stimulator (TES) to slow the progressive degeneration mostly in retinitis pigmentosa (RP). (1) Research suggests that TES has a cell preserving effect on dying retinal cells and the effect of electrical stimulation is attributable to the activation of several neuroprotective systems and factors. (1) TES also has been used in some optic neuropathies with success. (2) Also recently published data shows the benefits of stimulation therapies like transcranial direct brain stimulation technique (rTMS) in adult amblyopia. (3) Some success has been achieved by rTMS combined with computerized training methods.

Case

A 12 years old boy presented with deep amblyopia OD and 35 prism diopters of esotropia. (Fig.1) He was diagnosed with amblyopia at the age of 5 years, but refused to patch his non-amblyopic eye. No improvement could be achieved in his visual functions. When he presented to us, his visual acuities were 0.005 OD and 1.0 OS by the Snellen chart. Fundus exam was normal. His cycloplegic examination did not reveal a refractive error. TES by using Okuvision GmbH for 40 minutes per day for 10 consecutive days was applied to his amblyopic eye. The phosphene threshold was found and 200

percent of the threshold was used for the stimulation. The repeat exam one day after the last session of the therapy revealed visual acuity of 0.4 OD and 1.0 OS. The esotropia degree became 20 prism diopters. (Fig.2) The patient was followed for 1 week and his vision OS and esotropia degree did not change.



Figure 1 Before TES

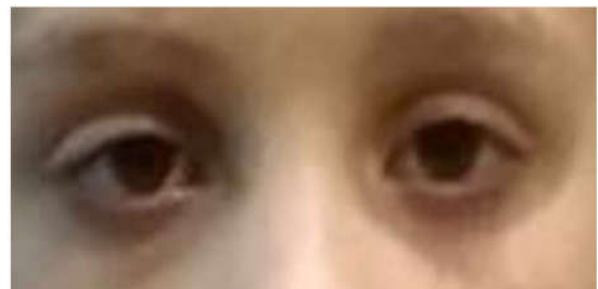


Figure 2 After TES.

DISCUSSION

Our report is the first case study that reveals significant improvement of amblyopia by TES. Amblyopia is a cerebral

*Corresponding author: Ibrahim Sahbaz
Uskudar University / Istanbul

visual impairment and stimulation of the visual pathways and the brain may be the correct strategy. There are reports about transient improvement by transcranial magnetic stimulation (rTMS). Another technique that used theta bursts with rTMS for 5 days disclosed improvement up to 78 days.(4) The brain stimulation may help regain some amount of binocularity which is impaired in amblyopes. Many cortical regions seem to be involved in amblyopia but neuroplasticity can be very helpful in the treatment trials. In a recent study it was demonstrated that anodal tDCS combined with dichoptic treatment led to significantly greater improvements in stereopsis than sham tDCS combined with dichoptic treatment. This effect was not present for monocular acuity suggesting that the treatment enhancing effects of tDCS were limited to binocular visual function. (5) Our findings with TES application revealed that visual acuity could also be improved.

We believe that the binocularity which was gained during TES resulted in improvement of the esotropia in our patient. There may be some questions that come to mind as how long the treatment effect will last or whether longer TES may give even better results, but our treatment approach may give clues for future directions and is another evidence for the benefits of the visual pathway and cortical stimulations.

CONCLUSION

TES may be considered in amblyopia treatment and can improve both visual acuity and binocularity.

References

1. Schatz A, Röck T, Naycheva L, *et al.* Transcorneal electrical stimulation for patients with retinitis pigmentosa: a prospective, randomized, sham-controlled exploratory study. *Invest Ophthalmol Vis Sci.* 2011 Jun 23; 52(7):4485-96.
2. Fujikado T, Morimoto T, Matsushita K, *et al.* Effect of transcorneal electrical stimulation in patients with nonarteritic ischemic optic neuropathy or traumatic optic neuropathy. *Jpn J Ophthalmol.* 2006 May-Jun; 50(3):266-73.
3. Spiegel, D. P., Byblow, W. D., Hess, R. F. Anodal transcranial direct current stimulation transiently improves contrast sensitivity and normalizes visual cortex activation in individuals with amblyopia. *Neurorehabil. Neural Repair.* 2013;27, 760-769.
4. Clavagnier, S., Thompson, B., Hess, R. F. Long lasting effects of daily theta burst rTMS sessions in the human amblyopic cortex. *Brain Stimul.* 2013; 6, 860-86.
5. D.P. Spiegel, J. Li, R.F. Hess, W.D. Byblow, D. Deng, M. Yu, *et al.* Transcranial direct current stimulation enhances recovery of stereopsis in adults with amblyopia. *Neurotherapeutics*, 10 (4) (2013), pp. 831-839.

How to cite this article:

Ibrahim Sahbaz and Umur A. Kayabasi (2017) 'Can Tes Improve A Squint?', *International Journal of Current Advanced Research*, 06(06), pp. 4004-4005. DOI: <http://dx.doi.org/10.24327/ijcar.2017.4005.0418>
