

**Research Article****COVID-19-RELATED ORAL MUCOSA LESIONS: A LITERATURE REVIEW****Vardendra Manvikar<sup>1</sup>, Vanishree M<sup>2</sup>, Shreekanth NG<sup>3</sup>, Anila Koneru<sup>4</sup>,  
Parveen Reddy K. M<sup>5</sup> and Basavana Gowda<sup>6</sup>**<sup>1,2,4</sup>Department of Oral Pathology, Navodaya Dental College and Hospital Raichur, Karnataka, India<sup>3</sup>Department of Oral Pathology, Srinivas Institute of Dental Science, Mangalore, Karnataka, India<sup>5</sup>Department of Pediatrics and Preventive Dentistry, Navodaya Dental College and Hospital, Raichur, Karnataka, India<sup>6</sup>Department of Conservative and Endodontics, Navodaya Dental College and Hospital, Raichur, Karnataka, India**ARTICLE INFO****Article History:**Received 13<sup>th</sup> March, 2023Received in revised form 11<sup>th</sup>  
April, 2023Accepted 8<sup>th</sup> May, 2023Published online 28<sup>th</sup> June, 2023**Key words:**

Covid-19

**ABSTRACT****Aims:** Severe acute respiratory syndrome coronavirus 2 (SARS-CoV-2) is the virus responsible for coronavirus disease 2019 (COVID-19). It manifests as a flu-like respiratory infection affecting multiple organ systems, including the gastrointestinal system, central nervous system, cardiovascular system, skin, and mucosa.**Objectives:** In this paper, we reviewed on specific manifestations of COVID-19 in the oral mucosa. An online literature search in PubMed, Scopus, Google Scholar, and Medline was conducted.**Results:** Oral manifestations of COVID-19 include erythematous plaque, ulcers, blisters, bullae, petechiae, mucositis, and desquamative gingivitis. The most commonly involved oral sites have been reported to be tongue, palate, lips, gingiva, and buccal mucosa.**Conclusion:** A knowledge of oral lesions of COVID-19 is important for all healthcare professionals, but particularly for Dental and Medical practitioners. Although COVID-19 cases around the world had increased, low numbers of patients with specific oral mucosa findings have been reported in the literature.

Copyright© The author(s) 2023. This is an open access article distributed under the Creative Commons Attribution License, which permits unrestricted use, distribution, and reproduction in any medium, provided the original work is properly cited.

**INTRODUCTION**

Severe acute respiratory syndrome coronavirus 2 (SARS-CoV-2) is the virus responsible for coronavirus disease 2019 (COVID-19).<sup>1</sup>

It manifests as a flu-like respiratory infection affecting multiple organ systems, including the gastrointestinal system, central nervous system, cardiovascular system, skin, and mucosa.<sup>1</sup>

In this paper, we reviewed on specific manifestations of COVID-19 in the oral mucosa. And also, to report on the location of these lesions within the oral mucosa.

**MATERIALS AND METHODS**

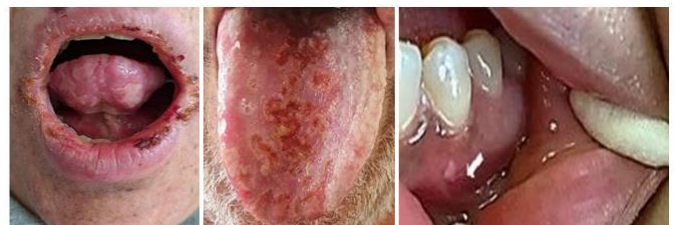An online literature search in PubMed, Scopus and Google Scholar. The search included all articles published until October 2022. We searched the electronic databases for relevant articles with the keywords “oral mucosa,” “oral lesions,” “mucocutaneous,” AND “SARS- CoV-2” or “Covid-19” or “Coronavirus 19.

**RESULTS**

The most common findings, reported were oral ulcers including aphthous, hemorrhagic, and necrotic ulcers.<sup>2</sup>

Other lesions reported includes pustules, macules, bullae, maculopapular enanthema, erythema multiforme-like lesions, erythematous plaque, blisters, petechiae, mucositis, and desquamative gingivitis.<sup>3</sup>

Loss of taste and smell was also reported. The most commonly involved oral sites have been reported to be tongue, palate, lips, gingiva, and buccal mucosa.<sup>4</sup>

**DISCUSSION**

It is unclear about the etiology of oral lesions described in COVID-19. Multiple etiologic factors may have a role. The lesions may be a direct result of the SARS-CoV-2 virus infection, or they could be related to stress, drugs used for COVID-19 treatment, or the general immunosuppressive status brought about by prolonged disease and hospitalization.<sup>5</sup>

\*Corresponding author: **Vardendra Manvikar**

Department of Oral Pathology, Navodaya Dental College and Hospital Raichur, Karnataka, India

Ulcerative lesions (49.1%) were the most frequent clinical presentation with varied sizes, being local or multiple, sometimes ulcers were with haemorrhagic areas, crust and necrosis. The other lesions reported were diffuse erythema diagnosed as mucositis (12%). Angina bullosa haemorrhagic-like and associated vascular disorder (4.3%) Petechiae (1.7%).<sup>6</sup>

### Histopathological changes

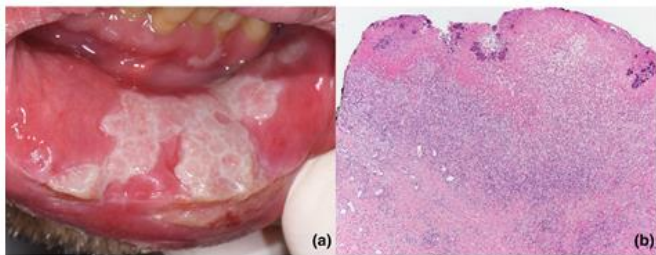
In general, the haematoxylin and eosin staining showed focal exocytosis and paranuclear keratinocytes and vacuolization in epithelium.<sup>1</sup>

The lamina propria presents mononuclear inflammatory infiltrate, vascular thrombosis, and can present haemorrhagic and necrotic focal areas.<sup>1</sup>

According to Soares *et al.* (2020) observations, the inflammatory infiltrate presents on these lesions are composed by T CD3 and T CD8 cells.<sup>7</sup>

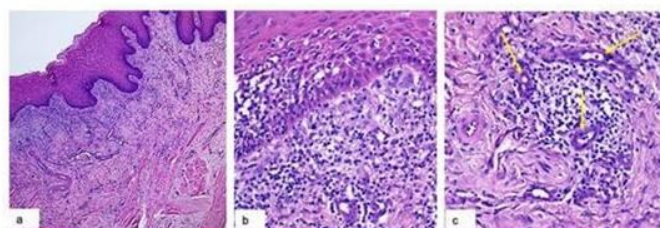
The CD3 positive cells are present in the basal layer of epithelium and surrounding endothelial cells in the connective, while CD8 positive cells were present in lamina propria.<sup>7</sup>

According to Erbas G S *et al.* (2022) histopathology showed ulcerated stratified squamous epithelium, vacuolization focally in the spinous layer, perivascular lymphocytic proliferation in the lamina propria, and subepithelial tissue, marked vascular congestion, and hemorrhage with Moderate lymphocytic infiltrate and microvascular thrombosis.<sup>2</sup>



According to Favia G *et al.* (2021) the histopathological features showed:<sup>3</sup>

1. lympho-monocytes sub-epithelial infiltrate and edema, keratinocyte necrosis, and activation of Langerhans cells
2. lympho-monocellular perivascular infiltration
3. Presence of multiple micro-thrombi (yellow arrows) of sub-epithelial small vessels
4. total occlusion of a middle-size sub-epithelial vessel with initial organization of the thrombus
5. partial occlusion of a deep vessel (yellow circle) and
6. perivascular secondary fibrosis.



## CONCLUSION

A knowledge of oral lesions is important for all healthcare professionals, but particularly for Dental and Medical practitioners. Although COVID-19 cases around the world had increased to 174 million by June 2021, low numbers of patients with specific oral mucosa findings have been reported in the literature. The SARS-CoV-2 virus may infect oral mucosa; however, this tissue may be resistant to the direct effect of the virus due to the protection afforded by innate immune barriers and rich vasculature.

Teledermatology is an effective method to diagnose and treat oral and skin symptoms of COVID-19 without increasing the risk of infection through a doctor's visit. In light of safety concerns, teleconsultation or self-photography may help monitor signs and symptoms in the oral mucosa and may aid in identifying more cases.

## References

1. Santana LADM, Vieira WA, Gonçalo RIC, Lima Dos Santos MA, Takeshita WM, Miguita L. Oral mucosa lesions in confirmed and non-vaccinated cases for COVID-19: A systematic review. *J Stomatol Oral Maxillofac Surg.* 2022 Oct;123(5):e241-e250.
2. Gizem S. Erbas. COVID-19-related oral mucosa lesions among confirmed SARS- CoV-2 patients: a systematic review- *International Journal of Dermatology* 2022; 61: 20–32.
3. Gianfranco Favia. Covid-19 Symptomatic Patients with Oral Lesions: Clinical and Histopathological Study on 123 Cases of the University Hospital Policlinic of Bari with a Purpose of a New Classification. *J. Clin. Med.* 2021; 10(4): 757.
4. Di Spirito, F.; Iandolo, A.; Amato, A.; Caggiano, M.; Raimondo, A.; Lembo, S.; Martina, S. Prevalence, Features and Degree of Association of Oral Lesions in COVID-19: A Systematic Review of Systematic Reviews. *Int. J. Environ. Res. Public Health* 2022;19: 7486.
5. Gutierrez-Camacho JR, Avila-Carrasco L, Martinez-Vazquez MC, Garza-Veloz I, Zorrilla-Alfaro SM, Gutierrez-Camacho V, Martinez-Fierro ML. Oral Lesions Associated with COVID-19 and the Participation of the Buccal Cavity as a Key Player for Establishment of Immunity against SARS-CoV-2. *Int J Environ Res Public Health.* 2022;19(18):11383.
6. Bhujel N, Zaheer K, Singh RP. Oral mucosal lesions in patients with COVID-19: a systematic review. *Br J Oral Maxillofac Surg.* 2021;59(9):1024-1030.
7. Soares CD, Carvalho RA, Carvalho KA, Carvalho MG, Almeida OP. Letter to Editor: oral lesions in a patient with Covid-19. *Med Oral Patol Oral Cir Bucal* 2020;25(4): e563–4.

### How to cite this article:

Vardendra Manvikar *et al* (2023) 'COVID-19-Related Oral Mucosa Lesions: A Literature Review', *International Journal of Current Advanced Research*, 12(06), pp. 2138-2139. DOI: <http://dx.doi.org/10.24327/ijcar.2023.2139.1469>