



Research Article

## EVALUATION OF THE EFFECT OF SUBMUCOSAL INJECTION OF DEXAMETHASONE TO CONTROL POSTOPERATIVE SEQUELAE AFTER THIR DMOLAR SURGERY: A PROSPECTIVE, RANDOMIZED, CROSSOVER CLINICAL STUDY

Neel Kamal\*<sup>1</sup>, Vaz Ashwin Alwyn<sup>2</sup>, Alfisha Sheikh<sup>3</sup>, Navneet Kaur<sup>4</sup> and Amit Sharma<sup>5</sup>

<sup>1,2,3</sup> Department of Oral and Maxillofacial Surgery, Rajasthan Dental College and Hospital, Jaipur

<sup>4</sup>Laxmibai Dental College, Patiala

<sup>5</sup>Rajasthan Dental College and Hospital, Jaipur

### ARTICLE INFO

#### Article History:

Received 9<sup>th</sup> September, 2022

Received in revised form 21<sup>st</sup> September, 2022

Accepted 18<sup>th</sup> October, 2022

Published online 28<sup>th</sup> October, 2022

#### Key words:

Dexamethasone, Pain, Swelling, Trismus

### ABSTRACT

**Introduction:** Impacted third molar surgery is one of the most common procedures performed by maxillofacial surgeons. Removal of symptomatic or diseased third molars has been shown to improve oral health and function of patients. Corticosteroids extensively used in dentoalveolar surgery are Dexamethasone owing to their nearly pure glucocorticoid effects. **Objective:** To evaluate the postoperative sequelae like pain, swelling and mouth-opening following the Dexamethasone administration. **Materials and method:** This study was conducted on 25 patients (50 impacted teeth-split-arches); 8mg Dexamethasone injected intraoral submucosally on one side & other side was injected with Normal-saline injection for placebo effect. Mouth-opening and facial-swelling were evaluated at 2<sup>nd</sup> and 7<sup>th</sup> postoperative day. The subjects were asked to enter their pain level using VAS (visual analog scale) rating. The effects on patients were studied using parameters like pain, trismus and swelling. **Results:** Sample comprising both groups were clinically analysed for pain, swelling and trismus using VAS (visual analog scale) for pain, modification of tape measuring method for swelling, and inter incisal opening for trismus. **Conclusion:** Statistically significant difference noted between two groups with respect to pain, swelling and trismus. Clinically patients on Dexamethasone had better relief with regards to pain, trismus and swelling when compared to Normal-saline group. This study shows that submucosal Dexamethasone successfully reduces the post-operative sequelae after third molar surgery. Hence, 8mg Dexamethasone can be used in routine third molar surgery to improve the postoperative quality of life of the patient.

Copyright©2022 Neel Kamal et al., This is an open access article distributed under the Creative Commons Attribution License, which permits unrestricted use, distribution, and reproduction in any medium, provided the original work is properly cited.

### INTRODUCTION

Surgical third molar extraction is most common procedure in patients aged (18-45 years) in oral & maxillofacial surgery department. There are many factors to consider before a decision to remove a mandibular third molar can be reached, involving a thorough medical, dental and social history combined with clinical and radiographic assessment. Removal of symptomatic or diseased third molars has been shown to improve oral health and function of patients.<sup>1,2</sup>

Post-operative sequelae (pain, swelling and trismus) are acute inflammatory complications of surgical removal of impacted mandibular third molar and are generally regarded as short-term problems of it. Minimally invasive surgical technique will minimize the sequelae of inflammation but won't prevent them.<sup>3</sup> Therefore, pharmacological intervention is needed to

control extent of inflammation and sequelae such as pain, swelling and trismus.

Following third molar removal, as with other surgical procedures, postoperative pain is a common undesirable outcome.<sup>3, 4, 5</sup> It is estimated that 40% of patients undergoing day-case surgical procedures experience moderate to severe post-operative pain.<sup>6</sup> Many clinical studies have investigated the treatments to reduce postoperative sequelae by using antiseptic mouthwashes, use of drains, flap design, antibiotics, enzymes, corticosteroid treatment, muscle relaxants, and physiotherapy. Among them, the use of corticosteroids has gained wide acceptance. Corticosteroids extensively used in dentoalveolar surgeries are Dexamethasone owing to their nearly pure glucocorticoid effects.<sup>7</sup>

Dexamethasone can be used for this purpose in surgery of third molar impactions. Post-operative swelling and edema

\*Corresponding author: Neel Kamal

Professor, Department of Oral and Maxillofacial Surgery, Rajasthan Dental College and Hospital, Jaipur

may be due in part to the conversion of phospholipids into arachidonic acid by phospholipidase A2 and resultant synthesis of prostaglandins, leukotrienes or thromboxane which act as mediator's inflammatory response. Thus, these drugs are supposed to have inflammation inhibiting properties as well as positive effect on edema.<sup>7</sup> In clinical trials that investigated the effect of pre-operative Dexamethasone, various routes of administration were employed ranging from oral tablet formulation, intra-muscular, intra-alveolar to intravenous administration.<sup>8,9,10</sup> Our study investigated the effects of the submucosal injection of 8mg Dexamethasone to control the postoperative pain reported at the surgical time.

## MATERIALS AND METHOD

The present study was carried out on 25 patients (50 impacted teeth – split-arch) who underwent surgical extraction of mandibular third molars in the Department of Oral and Maxillofacial Surgery, Rajasthan Dental College & Hospital, Jaipur. The patients were enrolled for the study consecutively as and when they reported to the hospital. A detailed case-history was recorded for every patient. Informed written consent was taken from each patient.

### Inclusion Criteria

- Patient's reporting for surgical removal of asymptomatic impacted mandibular third molars.
- Age group of 18-45 years.<sup>11</sup>
- Patients with similar bilaterally impacted mandibular third molars classified under Pell & Gregory's classifications.
- Patients giving consent.
- Exclusion Criteria
- Allergic to medications to be prescribed.
- Smokers, alcoholics.
- Systemically compromised or under long term steroid therapy.
- Patients with Periapical Pathologies.

## METHOD

The study subjects were randomly assigned in to two groups: Control and Experimental Group (8mg Dexamethasone). This study was conducted in same patient; 8mg Dexamethasone injected submucosally on one side & other side was injected with Normal-saline injection for placebo effect. A randomized prospective study was conducted on healthy patients with asymptomatic impacted mandibular third molars. Mouth-opening and facial-swelling were evaluated at 2nd and 7th postoperative day. The subjects were asked to open the mouth until pain was felt. Maximal interincisal distance was measured using ruler. Facial-swelling was evaluated by a modification of tape measuring method.

Trismus was assessed by measuring distance between the right upper and lower central incisors with the help of a caliper. The evaluation of trismus was also done preoperatively (baseline) and after 1, 2, 3 and 7-days following surgery. All measurements were performed by a trained examiner.

For randomization, a random-number table was used to generate block randomization schedule chart specifying the group to which each subject would be assigned up on the first-come-first-serve basis. On first day of surgery, the test drug of Dexamethasone 8 mg (2mL) and the placebo (2mL of Normal

Saline) were prepared in identical 2mL syringes according to random table and documented the same in a chart.

After the surgical preparation of subjects, lignocaine 2% with epinephrine 1:2, 00,000 was used as anesthetic agent to block the inferior-alveolar, lingual and long-buccal nerve. 8mg Dexamethasone or Normal-saline in placebo was injected submucosally into pre-third molar regions. Post-operative instructions were given to subjects, including an ice pack for 20 minutes and a pressure pack for 30 minutes over the surgical site to achieve hemostasis. All the subjects were prescribed antibiotic orally three times a day for 5 days and analgesic orally 8 hourly. The subjects were asked to take the first analgesic post-operatively as soon as the pain reached moderate level and asked to record the time. The subjects were instructed to not take any other analgesic drugs.

All the subjects were given a 10cm visual analog scale (VAS) and instructed about the rating.<sup>12</sup> They were asked to enter their pain level, time at which analgesic was taken, and number of tablets taken until the end of first post-operative week. They were asked to report to the OPD on 2<sup>nd</sup> and 7<sup>th</sup> post-operative days. The maximum interincisal distance and facial contours were measured on these appointments by the same examiner who had assessed them preoperatively. The technique and reference points used for these measurements were the same as those based in the pre-operative assessment. The evaluation of trismus and facial edema was recorded as the differences between pre-operative (baseline) and post-operative values.

## STATISTICAL ANALYSIS

All demographic details, baseline data and postoperative data were recorded in case report form over the course of the study. The quantitative data was represented as Mean  $\pm$  Standard-Deviation. Data was analyzed using Chi-square test and independent sample t-test for group analysis. The difference was considered as being of statistical significance at  $P < 0.05$ . The statistical analysis was done using SPSS (Statistical Package for Social Sciences) Version 22.0 statistical Analysis Software. The results were tabulated and data analyzed using method described above and results were obtained.

## MATERIALS

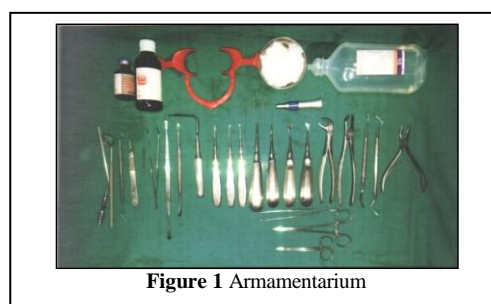


Figure 1 Armamentarium

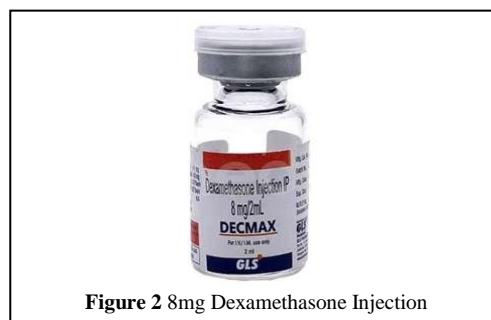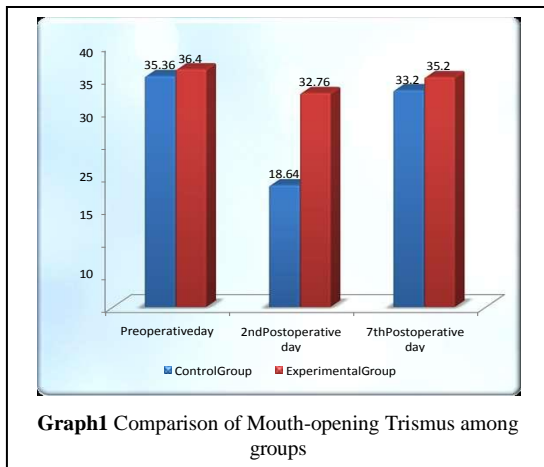


Figure 2 8mg Dexamethasone Injection

## RESULTS

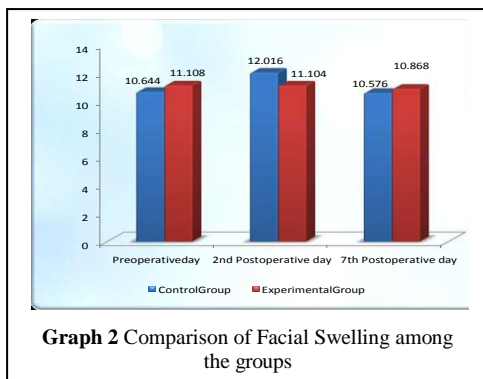
A total of 25 patients divided into 2 groups, reporting to the Department of Oral and Maxillofacial Surgery, Rajasthan Dental College and Hospital, Jaipur was enrolled in the study. A detailed medical history of the patient was recorded preoperatively.

The mouth-opening trismus, facial swelling and VAS scores 12 for painandindra and postoperative sequelae complications were recorded and results were tabulated in tables and depicted in graphs. A total of 14 male and 11 female patients were selected, in the age group between 18 and 42 years. Majority of patients were between 18-27 years (56%), followed by 28-42 years (44%). The age of patients, in years, was mean (M) = 28.56, standard-deviation (SD) = 6.90. On the second post-operative day, the reduction in mouth-opening was limited in both the groups compared to the preoperative measurements. There was increase in average mouth-opening after using 8mg Dexamethasone compared to control group. However, difference between the two groups was statistically significant (P = 0.000). On the seventh post-operative day, mouth-opening was increased in the control and experimental-group (Dexamethasone). On applying t-test, the statistically significant differences in the amount of inter incisal opening were noted between the two groups (p= 0.042). We observed that nearly all subjects gained preoperative inter incisal opening after trismus on Day 7 (Graph 1).

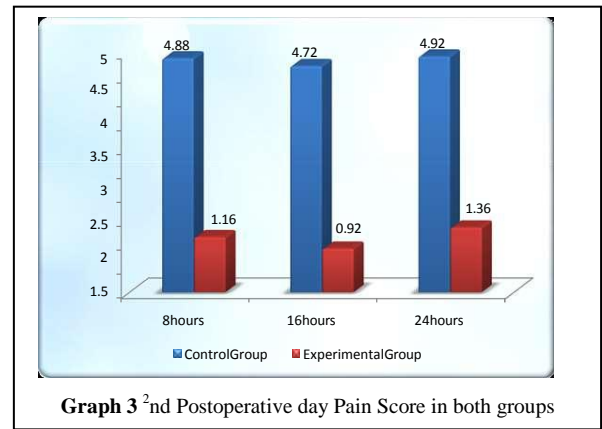


**Graph 1** Comparison of Mouth-opening Trismus among groups

On the second postoperative day, the mean-value of control group is 12.016 and experimental group is 11.104. There was an average decrease in facial swelling in experimental group compared to control group, indicating that there is significant difference between both the groups. It was observed that facial contour by the 7<sup>th</sup> post-operative day returned to normal in both the groups (Graph 2).

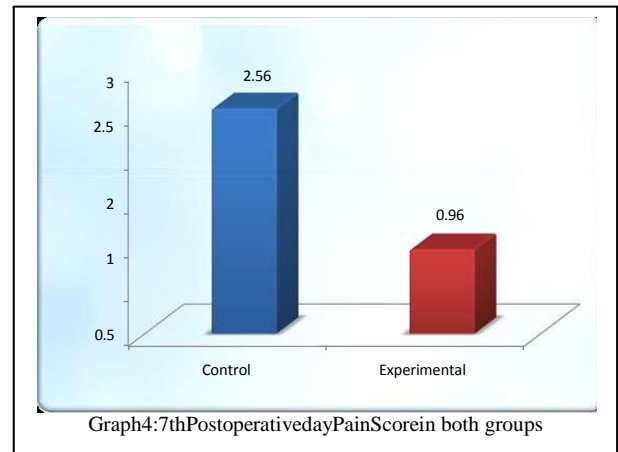


**Graph 2** Comparison of Facial Swelling among the groups



**Graph 3** 2<sup>nd</sup> Postoperative day Pain Score in both groups

We included VAS score evaluation for the pain analysis. There was a significant difference in pain scores between both the groups. At each hourly observation time, more patients had higher VAS scores with Normal-saline procedure than with 8mg Dexamethasone procedure. The pain scores of 8 hours were statistically significant among both the groups (p = 0.034).



**Graph 4**: 7<sup>th</sup> Postoperative day Pain Score in both groups

The pain scores of 16 and 24 hours were significantly higher in the control group than the experimental group (p= 0.000). On the 2<sup>nd</sup> and 3<sup>rd</sup> postoperative day, the average pain score of 8 and 24 hours were increased compared to the 16 hours in both groups. There was a statistically higher significant difference in pain scores between both the groups (P=0.000). On the 7<sup>th</sup> postoperative day, the average pain score was increased in control group compared to the experimental group. There was a statistically significant difference in pain scores between both the groups (P=0.019).

## DISCUSSION

The acute post-operative sequelae of impacted mandibular third molar surgery are manifestations of inflammation due to tissue injury. Dental extraction is one of the most frequently performed surgical procedures in dental practice. But only teeth with fully-form edroots and bony impaction (usually the mandibular third molars) are more difficult to extract than those with partially-formed or no roots, requiring a more invasive surgery. The inflammatory reaction is an essential vital process that promotes healing of the injured tissue, further justifying the use of corticosteroid only in third molar surgery rather than in routine dental surgery.<sup>13</sup> The control of inflammation after the surgery needs maximum attention and therefore, the choice of the anti-inflammatory agents should be directed against the control of the inflammation which further limits

the intensity, decreases the post-operative sequelae like pain, swelling & mouth-opening.<sup>14</sup> In an attempt to overcome these problems, steroids, non-steroidal anti-inflammatory drugs, anti-histamines, long acting local anesthetics and antibiotics have been tried with varying degree of success.

Numerous non-steroidal anti-inflammatory drugs have been used to reduce pain, edema and improve mouth-opening by inhibiting prostaglandin synthesis. These drugs suppress the post-operative pain without prominent anti-inflammatory properties. Overall pain experience and morbidity were not significantly improved suggesting that there was no clinical benefit derived from interference with tissue prostaglandin synthesis at the time of surgery. The NSAIDs are dose related. Smaller doses of the drug act as analgesic. To get good anti-inflammatory action, larger doses were used.<sup>15</sup>

There are ample studies on perioperative use of corticosteroid in oral surgery,<sup>7,16</sup> but to the best of our knowledge, only two studies have been reported on submucosal administration.<sup>17,18</sup> It has been shown in various studies that preoperative corticosteroid produces a significant result because the anti-inflammatory mediators are released immediately after the surgical trauma and Corticosteroid takes 3-4 hours to act.<sup>19</sup> However, in a typical practice setting, sub mucosal administering of corticosteroid three hours before surgery is usually not convenient. So, we preferred sub mucosal injection of 8mg Dexamethasone as local anesthesia injections just before surgical procedure, which prolong the duration of absorption leading to a maximum concentration at the site of action and a minimum systemic absorption due to the lack of the first-pass effect by the use of this route.<sup>20</sup> Hence, a single dose preoperative sub mucosal Dexamethasone was used.

The study showed significant improvement in mouth-opening on the 7<sup>th</sup> post-operative day. Graziani *et al*<sup>17</sup> reported that endo-alveolar applications of Dexamethasone powder significantly reduce the post-operative trismus at both the second and seventh days. But surprisingly, sub mucosal injection of Dexamethasone did not reduce trismus compared with the control group in his study. Markovic A *et al* reported that the seventh postoperative day, nearly all patients gain their pre-operative conditions.<sup>21</sup> Hence, we got significantly less trismus in the control group when compared with the Dexamethasone group on the second post-operative day but not on the seventh postoperative day. Another study also reported that trismus maybe a direct consequence of postoperative swelling that then compresses the nervous structures.<sup>22</sup> In our study, better results were obtained in the experimental group compared to the control group, especially on the 7<sup>th</sup> postoperative day, and significant difference in the mean-value of the 2<sup>nd</sup> day and 7<sup>th</sup> day after surgery ( $P= 0.000$  and  $0.042$ , respectively). Therefore, trismus seemed to follow the postoperative swelling.

Various studies have shown a significant decrease of the post-operative swelling in patients who were given a single dose corticosteroid immediately before surgery. 4mg Dexamethasone significantly decreases the post-operative swelling and trismus<sup>12</sup> whereas Neupert *et al*<sup>23</sup> did not find any benefit after the same administration. This may be a sub-

therapeutic dosage. The effect of a sub mucosal injection of Dexamethasone on reduction of edema on the second post-operative day has been shown in previous studies.<sup>17, 18</sup> Our study showed a similar result on the 1<sup>st</sup> and 2<sup>nd</sup> post-operative day, when maximum facial swelling was expected. However, the effect on reduction of edema on the 7<sup>th</sup> post-operative day is variable. However, in our study, we have not found any difference between the groups on the 1<sup>st</sup> and 7<sup>th</sup> post-operative day ( $P>0.05$ ). But we have found the difference between thereupon the 2<sup>nd</sup> post-operative day ( $P<0.05$ ). This could be due to the fact that the swelling of the face usually resolves after a week of surgery.<sup>24</sup> Also, the half-life of Dexamethasone is 36 hours and it suppresses the accumulation of leukocytes at the site of the inflammation and plasma exudation only up to the second post-operative day but not up to the seventh post operative day.

Corticosteroids are primarily used after surgical procedures for suppressing tissue mediators of inflammation, thereby reducing transudation of fluids and lessening edema.<sup>25,26</sup> Trismus is muscle stiffness that limits mouth-opening and is caused by fluid accumulation within muscles adjoining the operative site.<sup>7</sup> Although reduction of postoperative pain, generally accompanies a reduction of trismus and edema, steroids alone do not have a clinically significant analgesic effect.<sup>27</sup> A meta-analysis of six trials by Markiewicz *et al* found that corticosteroid treatment had marginally significant less pain than the control group in the early post-operative days.<sup>20</sup> Dexamethasone prolongs the duration of action of local anaesthesia.<sup>28,29</sup> Dionne *et al* conducted a study in which Dexamethasone 4 milligrams was given orally at 12 hours and 4 milligrams intravenously one hour before surgery, 1 hour before third molar surgery does not suppress PGE2 release sufficiently to produce analgesia after anesthetic offset.<sup>30</sup> We agree with these results only during immediate post-surgery period, as there was no account of pain levels after 180 hours of surgery in Dionne *et al* study. Results in our study showed less severity of pain during the 2<sup>nd</sup>, 3<sup>rd</sup> and 7<sup>th</sup> postoperative follow up period after using 8mg Dexamethasone injection compared with the control group. Statistical difference in the pain was noted which was significantly less in Dexamethasone compared to the control group. Overall, the results of the present study showed a reduction in the severity of pain of all the above-mentioned parameters in after 8, 16 and 24 hours on 2<sup>nd</sup>, 3<sup>rd</sup> and 7<sup>th</sup> day postoperatively indicating the effectiveness of Dexamethasone in reducing inflammation. Similar results were obtained in a study by Wajid *et al* where they compared sub mucosal to intramuscular injection of Dexamethasone following third molar surgery.<sup>14</sup>

In the present study it was observed that preoperative sub mucosal administration of Dexamethasone reduces the incidence of postoperative inflammatory complications such as pain, edema and trismus. Single preoperative dose of 8mg Dexamethasone via sub mucosal route at the site of surgery is more efficacious in reducing the postoperative sequel of third molar surgery than 8mg of Dexamethasone via intramuscular route in the same surgical procedure. Patients who were not subjected to Dexamethasone had higher incidence of postoperative sequelae complications to the patients who were subjected to intraoperative Dexamethasone.

## CONCLUSION

Third molar surgery is a traumatic procedure and the most common in Oral and Maxillofacial Surgery field. Being a highly vascularized area, predominantly constituted by loose connective tissue, a series of functional and structural alterations is expected among them of which, swelling, pain and trismus is most common. To control postoperative inflammation and symptoms associated, it is necessary to adopt a careful surgical technique and to provide an adequate anti-inflammatory therapy.

Many different regimens of glucocorticoids administration have been recommended to decrease the postoperative sequelae of pain, trismus and edema following removal of impacted third molars. In choosing a therapeutic regimen for glucocorticoid administration, a number of decisions must be made, including the type of steroid, the dosage and the route of administration, single versus multiple dosing, and finally, the timing of the administration relative to surgical procedure. As the third molar surgery in our setting is usually performed under local anesthesia, there is a convenience for both the surgeon and the patient in the use of sub mucosal corticosteroid. Technically, the sub mucosal route is easier to perform, without any extra skill necessary for IV or IM, and is not dependent on patient compliance and is without noticeable systemic side effects. Our study shows that Dexamethasone successfully reduces the post-operative sequelae after third molar surgery. Hence, 8mg Dexamethasone can be used in routine third molar surgery to improve the post-operative quality of life of the patient.

This study has led to the conclusion that the sub mucosal use of steroids such as Dexamethasone can be a valuable tool to control postoperative sequelae of third molar surgery. Since our sample size is small, still further studies with larger sample size are required to effectively evaluate the efficacy of Dexamethasone.

## References

- 1 Savin J, Ogden G. Third molar surgery—a preliminary report on aspects affecting quality of life in the early postoperative period. *British journal of oral and maxillofacial surgery*. 1997; 35(4):246-53.
- 2 McGrath C, Comfort MB, Lo EC, Luo Y. Can third molar surgery improve quality of life? A 6-month cohort study. *Journal of oral and maxillofacial surgery*. 2003; 61(7):759-63.
- 3 Bouloux GF, Steed MB, Perciaccante VJ. Complications of third molar surgery. *Oral and Maxillofacial Surgery Clinics*. 2007; 19(1):117-28.
- 3 Yuasa H, Sugiura M. Clinical postoperative findings after removal of impacted mandibular third molars: prediction of postoperative facial swelling and pain based on preoperative variables. *British Journal of Oral and Maxillofacial Surgery*. 2004; 42(3):209-14.
- 4 Grossi GB, Maiorana C, Garramone RA, Borgonovo A, Creminelli L, Santoro F. Assessing postoperative discomfort after third molar surgery: a prospective study. *J Oral Maxillofac Surg*. 2007; 65(5):901-17.
- 5 Janssen KJ, Kalkman CJ, Grobbee DE, Bonsel GJ, Moons KG, Vergouwe Y. The risk of severe

- postoperative pain: modification and validation of a clinical prediction rule. *Anesthesia & Analgesia*. 2008; 107(4):1330-9.
- 6 Moore PA, Brar P, Smiga ER, *et al*. Preemptive rofecoxib and dexamethasone for prevention of pain and trismus following third molar surgery. *Oral Surg Oral Med Oral Pathol Oral Radiol Endod*. 2005;99(2):1-7.
- 7 Simone JL, Jorge WA, Horliana ACRT, Canaval TG, Tortamano IP. Comparative analysis of preemptive analgesic effect of dexamethasone and diclofenac following third molar surgery. *Brazilian oral research*. 2013; 27(3): 266-71.
- 8 Al-Dajani M. Can preoperative intramuscular single-dose dexamethasone improve patient-centered outcomes following third molar surgery? *Journal of Oral and Maxillofacial Surgery*. 2017; 75(8):1616-26.
- 9 Pappalardo S, Puzzo S, Cappello V, Mastrangelo F, Adamo G, Caraffa A, *etal*. The efficacy of four ways of administering dexamethasone during surgical extraction of partially impacted lower third molars. *European Journal of Inflammation*. 2007; 5(3):151-8.
- 10 Deo SP, Shetty P. Effect of submucosal injection of dexamethasone on post-operative sequelae of third molar surgery. *Journal of the Nepal Medical Association*. 2011 Apr 1; 51(182).
- 11 Momeni E, Barati H, Arbabi MR, Jalali B, Moosavi MS. Low-level laser therapy using laser diode 940 nm in the mandibular impacted third molar surgery: double-blind randomized clinical trial. *BMC Oral Health*. 2021 Dec; 21(1):1-8.
- 12 Hupp JR. Principles of surgery In: Peterson LJ, Ellis E, Hupp JR, Tucker MR, editors. *Contemporary oral and maxillofacial Surgery*. 4th ed. India: Mosby; 2003:47.
- 13 Seymore AJ, *frame*. The comparative efficacy of aceclofenac and ibuprofen in post operative pain after third molar surgery. *BJOMS*, 1998; 36:375-79.
- 14 Majid OW, Mahmood WK. Effect of submucosal and intramuscular dexamethasone on postoperative sequelae after third molar surgery: comparative study. *British Journal of Oral and Maxillofacial Surgery*. 2011 Dec 1; 49(8):647-52.
- 15 Montgomery MT, Hogg JP, Roberts DL, Redding SW. The use of glucocorticosteroids to lessen the inflammatory sequelae following third molar surgery. *Journal of oral and maxillofacial surgery*. 1990 Feb 1; 48(2):179-87.
- 16 Graziani F, D'aiuto F, Arduino PG, Tonelli M, Gabriele M. Perioperative dexamethasone reduces post-surgical sequelae of wisdom tooth removal. A split-mouth randomized double-masked clinical trial. *International journal of oral and maxillofacial surgery*. 2006 Mar 1; 35(3):241-6.
- 17 Grossi GB, Maiorana C, Garramone RA, Borgonovo A, Beretta M, Farronato D, Santoro F. Effect of submucosal injection of dexamethasone on postoperative discomfort after third molar surgery: a prospective study. *Journal of oral and maxillofacial surgery*. 2007 Nov 1; 65(11):2218-26.



- 18 Alexander RE, Thronson RT. A review of perioperative corticosteroid use in dent alveolar surgery. *Oral Surg Oral Med Oral Pathol Oral Radiol Endod.* 2000; 90(4):406-15.
- 19 George PC. Adrenocorticosteroids and adrenocortical antagonist, In Katzung BG, editor. *Basic and Clinical pharmacology.* 11<sup>th</sup> ed. New Delhi: Tata McGraw Hill; 2009:681-97.
- 20 Markovic A, Todorovic LJ. Effectiveness of dexamethasone and low-power laser in minimizing edema after third molar surgery: a clinical trial. *Int J Oral Maxillofac Surg.* 2007; 36:226-9.
- 21 Klongnoi B, Kaewpradub P, Boonsiriseth K, Wongsirichat N. Effect of single dose preoperative intramuscular dexamethasone injection on lower impacted third molar surgery. *Int J Oral Maxillofac Surg* 2012; 41: 376-9.
- 22 Neupert III EA, Lee JW, Philput CB, Gordon JR. Evaluation of dexamethasone for reduction of postsurgical sequelae of third molar removal. *Journal of oral and maxillofacial surgery.* 1992 Nov 1; 50(11):1177-82.
- 23 Peterson LJ. Postoperative patient management. In: Peterson LJ, Ellis E, Hupp JR, Tucker MR, editors. *Contemporary oral and maxillofacial Surgery.* 4<sup>th</sup> ed. India: Mosby; 2003. P.215-9.
- 24 Esen E, Taşar F, Akhan O. Determination of the anti-inflammatory effects of methylprednisolone on the sequelae of third molar surgery. *Journal of oral and maxillofacial surgery.* 1999 Oct 1; 57(10):1201-6.
- 25 Gersema L, Baker K. Use of corticosteroids in oral surgery. *J Oral Maxillofac Surg* 1992; 50:270-7.
- 26 Filho JRL, Maurette PE, Allias M, Cotinho M, Fernandes C. Clinical comparative study of the effectiveness of two doses of dexamethasone to control postoperative swelling, trismus and pain after the surgical extraction of mandibular impacted third molars. *Med Oral Patol Oral Cir Bucal* 2008; 13(2): E129-32.
- 27 Yadav RK, Sah BP, Kumar P, Singh SN. Effectiveness of addition of Neostigmine or Dexamethasone to local anaesthetic in providing perioperative analgesia for brachial plexus block: A prospective, randomized, double blinded, controlled study. *Kathmandu University Medical Journal.* 2008; 6(3):302-9.
- 28 Colombo G, Padera R, Langer R, Kohane DS. Prolonged duration local anesthesia with lipid-protein-sugar particles containing bupivacaine and dexamethasone. *J Biomed Mater Res A.* 2005; 75(2):458-64.
- 29 Troullos ES, Hargreaves KM, Butler DP, Dionne RA. Comparison of nonsteroidal anti-inflammatory drugs, ibuprofen and flurbiprofen, with methylprednisolone and placebo for acute pain, swelling, and trismus. *J Oral Maxillofac Surg* 1990; 48:945-52.

\*\*\*\*\*