



Research Article

## LATE-ONSET CORONARY VASOSPASM FROM 5-FU CHEMOTHERAPY

Anand Prajapati\*, Harsh Patel and Shiv Ghodasara

Department of General Medicine, Geetanjali Medical College and Hospital, Udaipur

### ARTICLE INFO

#### Article History:

Received 10<sup>th</sup> September, 2022

Received in revised form 20<sup>th</sup> September, 2022

Accepted 15<sup>th</sup> October, 2022

Published online 28<sup>th</sup> October, 2022

### ABSTRACT

5-Fluorouracil (5-FU) is an antimetabolite chemotherapy used for a variety of solid tumors. It has the potential to cause a wide spectrum of Coronary vasospasm, cardiotoxicity, ranging from asymptomatic electrocardiographic changes to cardiomyopathy and subsequent cardiac failure. Main body of the abstract: We a case of new-onset severe coronary vasospasm induced by 5-FU.

#### Key words:

COVID-19, Depression, Anxiety

Copyright©2022 Anand Prajapati et al. This is an open access article distributed under the Creative Commons Attribution License, which permits unrestricted use, distribution, and reproduction in any medium, provided the original work is properly cited.

### INTRODUCTION

5-Fluorouracil (5-FU) based chemotherapy regimens have substantially improved colon cancer survival. 5-FU can cause immediate cardiac complications, including coronary thrombosis, coronary vasospasm, cardiomyopathy and cardiac arrest<sup>1</sup>. Here we report and discuss the rare case of a patient who underwent 5-FU chemotherapy and developed coronary vasospasm both during infusion and approximately 36 hours after discontinuation.

### CASE REPORT

A 50-year-old man with recently diagnosed metastatic sigmoid colon cancer initiated his first cycle of Folinic acid + 5-FU + Oxaliplatin (FOLFOX) chemotherapy. 24 hours into continuous home infusion of 5-FU, he developed substernal chest pain that radiated to his left shoulder. He took oxycodone with minimal relief; 5-FU infusion continued. 8 hours later symptoms worsened triggering 5-FU discontinuation and presentation to ED. Chest pain resolved within 10 minutes after 5-FU discontinuation. Upon arrival to the ED, EKG was performed that demonstrated diffuse repolarization changes and ST elevations in leads I and aVL, and mild elevations in leads II, III and aVF with T wave inversions (figure 1). Code STEMI was called, and coronary angiography performed with no evidence of obstructive coronary lesions but tortuous coronary anatomy. Transthoracic echocardiogram revealed new moderate to severe systolic dysfunction with global hypokinesis and a reduced ejection fraction (35%). Patient was placed on a beta-blocker, lisinopril, and Lasix and symptoms and EKG changes fully resolved. Approximately 36 hours after 5-FU discontinuation patient suddenly developed malaise and diaphoresis followed shortly thereafter by a ventricular tachycardia pulseless cardiac arrest

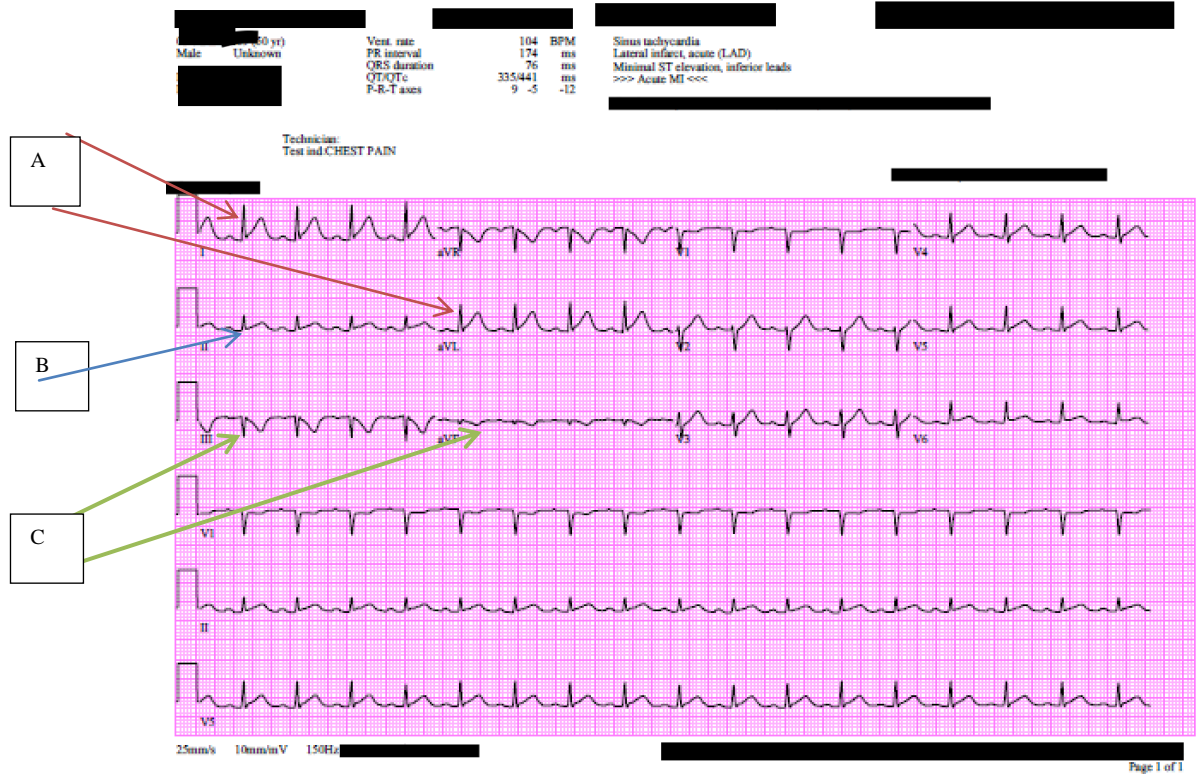
captured on telemetry monitoring. Code Blue was called, and CPR immediately initiated. Patient was successfully resuscitated and placed on amiodarone drip. EKG again demonstrated similar vasospastic changes as the presentation EKG, which subsequently resolved. The next morning, he complained of only chest tenderness from the CPR, but denied any dyspnea, palpitations or dizziness and was hemodynamically stable. He showed no significant changes in his symptoms or labs/imaging results for the next 5 days and was discharged home with a LifeVest (wearable defibrillator). Once recovered, he initiated alternate chemotherapy with partial remission. 3 months after the event, his ejection fraction returned to normal. He is now doing well more than 6 months later with no further cardiac events and return to full activities.

### DISCUSSION

The fluoropyrimidines, namely, 5-FU, is the third most commonly used chemotherapeutic agent for the treatment of solid tumors. 5-FU is a pyrimidine analog that inhibits thymidylate synthase, an enzyme involved in DNA replication. These agents function as S-phase antimetabolites, inducing double-strand DNA and single-strand DNA breaks and promote genomic instability; they interfere with DNA synthesis, repair, and elongation. 5-FU is the second most common agent after carboplatin which can cause cardiotoxicity. Risk factors for 5-FU cardiotoxicity include older age, preceding history of cardiac disease, and concomitant use of cardiotoxic medications. Vasospastic angina is characterized by episodes of chest "discomfort" at rest, nausea, diaphoresis, dizziness, dyspnea and palpitations and associated with transient ST-segment elevations on EKG. Coronary vasospasm is an uncommon but well described

\*Corresponding author: Anand Prajapati

Department of General Medicine, Geetanjali Medical College and Hospital, Udaipur



**Figure 1** EKG showing ST elevations in leads I and aVL (A), mild ST elevations in lead II (B), and mild ST elevations with T wave inversions in leads III and aVF

adverse consequence of 5-FU chemotherapy with unknown mechanism<sup>1</sup>. Physicians should be aware of this complication and advise patients to immediately stop infusional 5-FU and seek emergency care for any potential cardiac symptoms. 5-FU vasospasm has not previously been reported to recur >24 hours after treatment without re-challenge<sup>2,3</sup>. In the present case, patient being on telemetry monitoring with immediate CPR and cardioversion led to an excellent long-term outcome. Clinicians should consider observation on telemetry for 48-72 hours and/or short-term life vest use for appropriate patients who develop significant 5-FU vasospasm.

## CONCLUSION

Our case emphasizes the importance of early recognition of the rare complication of the commonly used chemotherapeutic agent. In the majority of cases, 5-FU-induced coronary vasospasm is reversible; however, in view of the potentially lethal profile and successful clinical outcomes associated with early detection and intervention, physicians should be aware of its existence.

## References

1. Kanduri, J., More, L. A., Godishala, A., & Asnani, A. (2019, November). Fluoropyrimidine-Associated Cardiotoxicity. *Cardiology Clinics*, 37(4), 399–405. <https://doi.org/10.1016/j.ccl.2019.07.004>
2. Redman, J. M. (n.d.). *Successful 5-fluorouracil (5-FU) infusion re-challenge in a metastatic colorectal cancer patient with coronary artery disease who experienced symptoms consistent with coronary vasospasm during first 5-FU infusion*. <https://jgo.amegroups.com>. Retrieved September 28, 2022, from <https://jgo.amegroups.com/article/view/30684/22520>
3. *Symptomatic Cardiotoxicity with High-Dose 5-Fluorouracil Infusion: A Prospective Study*. (1993, May 5). Abstract - *Oncology* 1993, Vol. 50, No. 6 - Karger Publishers. Retrieved September 28, 2022, from <https://www.karger.com/Article/Abstract/227226>

### How to cite this article:

Anand Prajapati *et al* (2022) 'Late-Onset Coronary Vasospasm From 5-Fu Chemotherapy', *International Journal of Current Advanced Research*, 11(10), pp. 1582-1583. DOI: <http://dx.doi.org/10.24327/ijcar.2022.1583.0353>