



GHOSAL HEMATO-DIAPHYSEAL DYSPLASIA PRESENTING AS HYPOPLASTIC MARROW: A CASE REPORT

Harveen Bhusari¹, Nishad Dhakate² and Rahul Arora³

¹Department of Pathology HCG-NCHRI Cancer Care Centre Nagpur

^{2,3}Department of Hematology and BMT HCG-NCHRI Cancer Care Centre Nagpur

ARTICLE INFO

Article History:

Received 13th May, 2022

Received in revised form 11th June, 2022

Accepted 8th July, 2022

Published online 28th August, 2022

ABSTRACT

Ghosal hematodiaphyseal dysplasia is a rare autosomal recessive disorder characterized by metadiaphyseal dysplasia of long bones and defective hematopoiesis due to fibrosis or sclerosis of bone marrow. The diagnosis of this syndrome with other sclerosing bone disorders is important as correct diagnosis helps in the treatment. We review the literature of this uncommon disorder and present a similar case for a 2 year old Indian female who presented with bicytopenia with no radiological abnormalities and was detected with the help of molecular diagnosis.

Keywords:

Anaemia, metadia physeal dysplasia, Caffey disease, Engelmann disease.

Copyright©2022 **Harveen Bhusari et al.** This is an open access article distributed under the Creative Commons Attribution License, which permits unrestricted use, distribution, and reproduction in any medium, provided the original work is properly cited.

INTRODUCTION

Ghosal hematodiaphyseal dysplasia syndrome is a rare autosomal recessive disease first described by Ghosal *et al* characterized by marked anaemia, long bone thickening and radiographic features of metaphyseal and diaphyseal dysplasia.[1] It is a rare inherited disorder seen in background of Middle east and India.[1,2] Mutation in gene *TBXAS1* on chromosome 7q33-q34 that encodes thromboxane synthase (TXAS) causing increased bone density and decreased erythroid precursors was identified.[3].

Here in we report a case of 2year old Indian girl presenting as bicytopenia and diagnosis was confirmed by mutation analysis. She was treated with steroids, to which she responded and is under follow up.

CASE REPORT

2year old female child presented with fever on and off, cold, cough and paleness since 15 days. Her birth history revealed that she was born with caesarean section, full term, low birth weight of 1.9kg, with history of developmental delay. Furthermore, her parents informed about her history of tripping while walking.

On admission she was afebrile, with heart rate 140/min, respiratory rate 34/min, maintaining saturation of 96% on room air. On examination, she was conscious, alert with

occasional wheezing. No organomegaly or lymphadenopathy noted.

She was worked up with following investigations: CBC showed, haemoglobin of 7.3g/dl, total leucocyte count was $6.3 \times 10^9/L$ with absolute neutrophil count of $1.49 \times 10^9/L$, platelet count of $55 \times 10^3/$. Her ESR was >140 , retic count was 1.3%. Her blood group is A positive. Her liver function tests, renal function tests, electrolytes, high performance liquid chromatography (Hb-HPLC) and urine routine/ microscopy was normal. Covid antibody, widal and mantoux tests were negative. Her ANA by IFA and ds DNA were negative. Blood culture was sterile.

Her X ray pelvis with both hip joint AP view reveals metadiaphyseal widening of the bilateral distal femur suggestive of metaphyseal flaring [Figure 1].

Her bone marrow examination revealed bony trabeculae with hypocellular marrow spaces [Figure 2]. Reticulin stain was negative [Figure 3].

In view of bicytopenia, X-Ray findings and bone marrow examination; her molecular studies were sent for further evaluation. Next Generation Sequencing (massively parallel sequencing) was done and revealed homozygous mutation in *TBXAS1* gene on exon 12 (variant nomenclature as c.1373G>A p.Arg458Gln) confirming Ghosal Hematodiaphyseal Syndrome.

*Corresponding author: **Harveen Bhusari**

Department of Pathology HCG-NCHRI Cancer Care Centre Nagpur

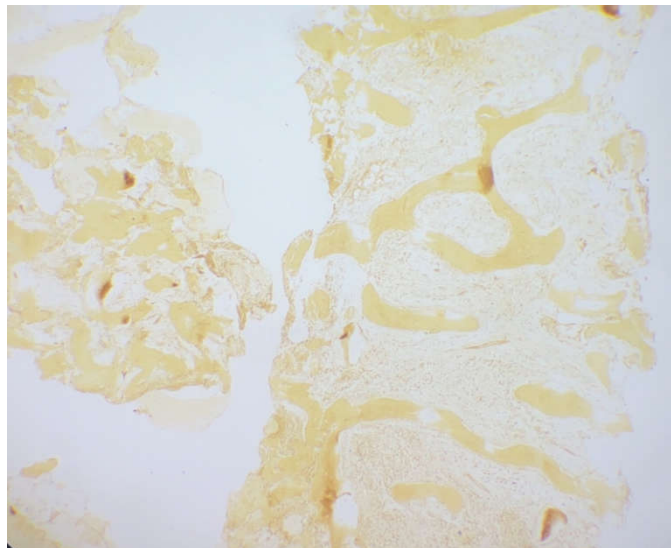


Figure 1 Metaphyseal Flaring (X Ray pelvis with B/L Hip)

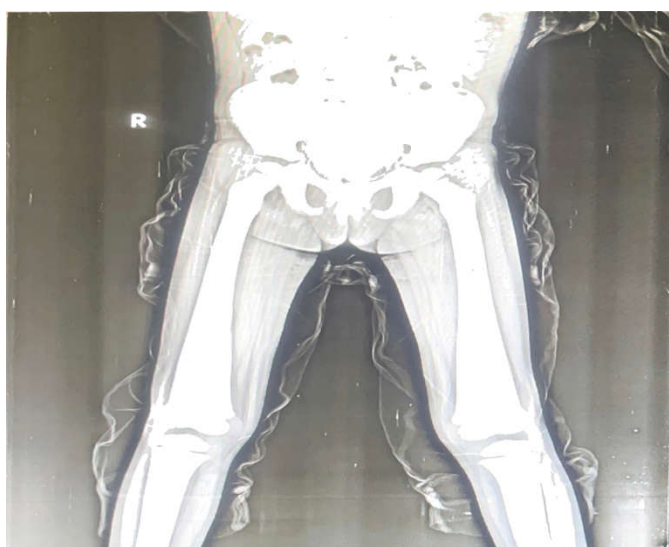

Figure 2 Hypocellular Marrow on Bone Marrow Biopsy (X100x, H&E stain)

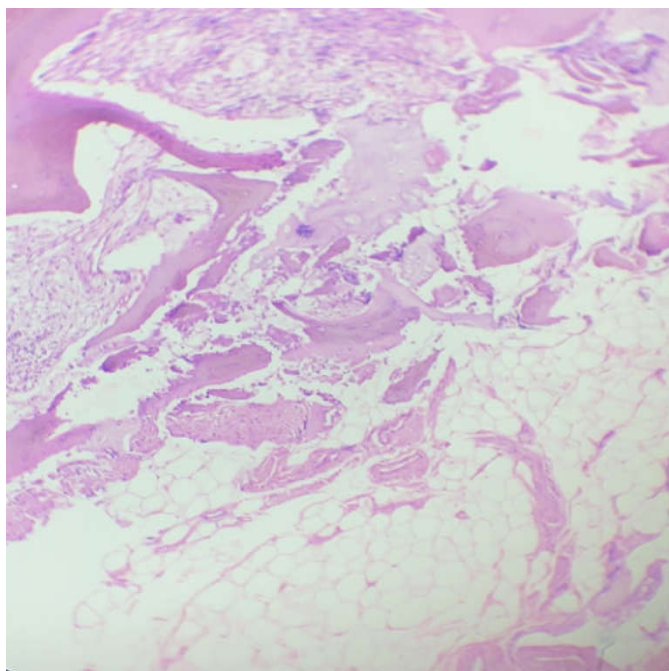


Figure 2 Hypocellular Marrow on Bone Marrow Biopsy (X100x, H&E stain)

She was treated with steroids (prednisolone) 1mg/kg to which she responded well. Her haemoglobin is improved to 10.1g/dl, total leucocyte count is $7.3 \times 10^9/L$ with absolute neutrophil count as $5.66 \times 10^9/L$, platelet count is $131 \times 10^3/$. She is under follow up.

DISCUSSION

Ghosal haematodiaphyseal disorder is a rare autosomal recessive disorder characterized by bone marrow dysfunction, increased bone density with metadiaphyseal dysplasia responsive to steroid therapy. [1,4].

Researches have shown mutation in *TBXAS1* gene on chromosome 7q33-34 which impairs thromboxane A synthase in arachdonic acid metabolism pathway leading to decreased thromboxane A2 (TXA2) and increase in prostaglandin E2 (PGE2). This suppresses erythroid precursor cells resulting in refractory anaemia. TXA2 also interferes with expression of TNFSF11 and TNFRSF11B which encode RANKL and osteoprotegerin in osteoblast leading to bone remodelling - bone resorption and formation. [3,4,5,6].

Clinically patient presents with variable features. On blood examination there is usually normocytic normochromic anaemia. Bone marrow examination reveals normocellular to hypocellular marrow with some degree of fibrosis. Radiographic abnormalities such as diaphyseal dysplasia, endosteal thickening and widening of long bones, Erlenmeyer flask deformity and base of skull sclerosis have been reported.[7,8,9]

Caffey disease, Camurati-Engelmann disease {Progressive diaphyseal dysplasia (PDD)} are close differential diagnosis to GHDD. Caffey disease is seen in early infancy presents with fever, soft tissue swelling, bony dysplasia with periosteal reaction progressing to sub periosteal new bone formation. Whereas PDD is rare autosomal dominant characterized by neuromuscular symptoms with endosteal and periosteal involvement. [4,10]

Steroids remain the mainstay for treatment of such cases with maintenance steroid therapy needed in most cases. [1]

In our case patient presented with bicytopenia, metadiaphyseal widening of bilateral distal femur on X-Ray and hypocellular marrow, which we diagnosed as Non Severe Aplastic Anaemia. Molecular study (Next Gene Sequencing) helped us to find the homozygous mutation in *TBXAS1* gene on exon 12 and label the patient as Ghosal Diaphyseal Disease.

Jeevan Amrit *et al* [2] presented a similar case where a patient presented with severe pallor, organomegaly, bicytopenia, increased cortical density with diaphyseal involvement and reactive bone marrow with prominence of mature lymphoid cells. GurudasKini *et al*[4] also presented a similar case with progressive pallor, bowing of lower extremities, bicytopenia, metadiaphyseal dysplasia and hypocellular bone marrow.

LIMITATION OF PRESENT CLINICAL SCENARIO AND CONCLUSION

Sometimes due to limited set ups and funds for molecular testing of mutations, these cases are generally misunderstood as Aplastic Anaemia where in the patient is mistreated and no significant positive results are noted. Hence reporting such cases place a vital role in unravelling the spectrum of molecular studies in diagnosis.

References

- Ghosal SP, Mukherjee AK, Mukherjee D, *et al.* Diaphyseal dysplasia associated with anemia. *J Pediatr.*1988; 113 (1 Pt 1):49-57.
- Jeevan *et al.* Ghosal Type Hematodiaphyseal Dysplasia. *Indian Pediatrics.*2016;53:347-348.
- Genevieve D, Proulle V, Isidor B, *et al.* Thromboxane synthase mutations in an increased bone density disorder (Ghosal syndrome). *Nat Genet.*2008;40(3):284-6.
- Kini P, Kumar S, Moideen A *et al.* Ghosal Hematodiaphyseal Dysplasia: A rare Variety of Hypoplastic Anemia with Good Response to Steroid Therapy. *Indian J Hematol Blood Transfusion.*2018;34(1):181-182.
- Sharma R, Sierra Potchant E, Schwartz JE, *et al.* Chronic steroid response pancytopenia and increased bone density due to thromboxane synthase deficiency. *Pediatr Blood Cancer.*2018;65(1):10.1002/pbc.26777.
- Isidor B, Dagoneau N, Huber C, *et al.* A gene responsible for Ghosal hemato-diaphyseal dysplasia maps to chromosome 7q33-34. *Hum Genet.*2007;121(2):269-73.
- Mazaheri P, Nadkarni G, Lowe E, *et al.* Ghosal hematodiaphyseal dysplasia: a rare cause of a myelophthisic anemia. *Pediatr Blood Cancer.*2010;55(6):1187-90.
- John RR, Boddu D, Chaudhary N, *et al.* Steroid responsive anemia in patients of Ghosal hematodiaphyseal dysplasia: simple to diagnose and easy to treat. *J pediatrHematol Oncol;*37(4):285-9.
- Arora R, Aggarwal S, Deme S. Ghosal hematodiaphyseal dysplasia-a concise review including an illustrative patient. *Skeletal Radiol.*2015;44(3):447-50.
- De Vernejoul MC, Kornak U. Heritable sclerosing bone disorders: presentation and new molecular mechanisms. *Ann N Y Acad Sci.*2010;1192:269-77.

How to cite this article:

Harveen Bhusari *et al* (2022) 'Ghosal hemato-Diaphyseal Dysplasia Presenting As Hypoplastic Marrow: A Case Report', *International Journal of Current Advanced Research*, 11(08), pp. 1449-1451.
DOI: <http://dx.doi.org/10.24327/ijcar.2022.1451.0321>
