

ECTOPIC TOOTH IN INFERIOR MEATUS OF NOSE: A CASE REPORT

Stuti Mahajan¹, Anupama Mahajan², Anukaran Mahajan³ and Karunesh Gupta⁴

¹ENT Hospital, GMC, Amritsar

²Anatomy Department, SGRDIMS, Amritsar

^{3,4}Chikitsa ENT Hospital, Amritsar

ARTICLE INFO

Article History:

Received 13th May, 2022

Received in revised form 11th June, 2022

Accepted 8th July, 2022

Published online 28th August, 2022

Keywords:

Nasal obstruction, nasal discharge, Ectopic tooth, Cone beam computerized tomography, Case report

ABSTRACT

Introduction: Ectopic eruption of tooth is defined as eruption of tooth into place other than tooth bearing region. Though ectopic eruption of tooth is rare, cases have been reported where ectopic eruption of tooth is seen in Nasal cavity, orbital floor, orbit, Mandibular condyle, palate, chin and maxillary sinus. The ectopic eruption of the teeth into the inferior meatus is a rare phenomenon. It is mostly found incidentally or with nasal symptoms.

Case presentation: A 54 year old female presented to the OPD of Chikitsa ENT Hospital at Amritsar, Punjab with the complaint of nasal obstruction and nasal discharge with facial heaviness on right side for the last one year. On diagnostic nasal endoscopy, premolar tooth was reported in inferior meatus. Non contrast computerized tomography (NCCT) of nose & of Paranasal sinuses (PNS) was done. Reports were suggestive of chronic rhinosinusitis of right maxillary and right ethmoid sinuses with a well defined irregular opacity in the right nasal cavity. Endoscopic removal of tooth along with associated soft tissue and the bony fragments were carried out under general anesthesia along with right maxillary antrostomy and ethmoidectomy. The patient tolerated the procedure very well with improvement in nasal symptoms.

Conclusion: Patient having ectopic tooth should be followed up regularly even if there is no sign and symptoms because odontogenic tumours and cysts can develop around it. Thus, crucial attention to the clinical, histopathological and radiological examination should be taken for more accurate diagnosis and early surgical intervention for removal of ectopic tooth by minimally invasive technique to prevent the development of unesthetic scar.

Copyright©2022 Stuti Mahajan et al. This is an open access article distributed under the Creative Commons Attribution License, which permits unrestricted use, distribution, and reproduction in any medium, provided the original work is properly cited.

INTRODUCTION

BACKGROUND

Ectopic tooth is the presence of a tooth in a non-dentate area, distant from its usual anatomical location. Abnormal interaction or tooth germ cells migrating to abnormal position caused by developmental disturbance, pathological process or iatrogenic activity during embryonic development may be the pathogenesis of ectopic tooth development [1,2]. Ectopic tooth can occur in different positions, such as maxillary sinus [3], nasal cavity [4], Nasal floor, Chin, orbit, Coronoid Process, Subcondylar region and Mandibular condyle [5]. We are reporting a case of ectopic tooth in inferior meatus of nose in a patient who visited Chikitsa ENT hospital at Amritsar, Punjab.

CASE REPORT

A 54 year old female visited Chikitsa hospital at Amritsar, Punjab with the complaint of nasal obstruction and nasal discharge with facial heaviness heaviness on right side. Clinically, deciduous premolar was over retained and

permanent premolar was missing in that quadrant. On diagnostic nasal endoscopy, premolar teeth was seen in inferior meatus.

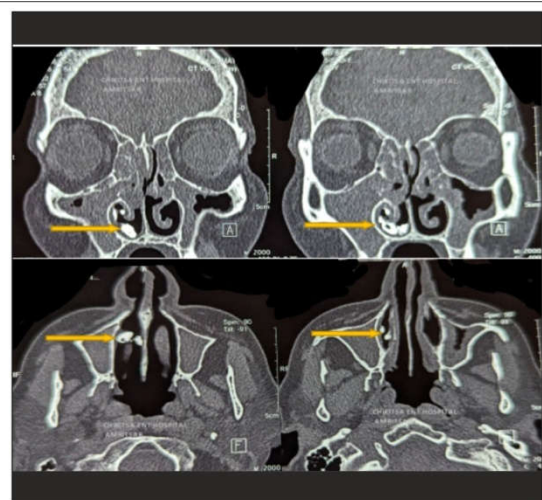
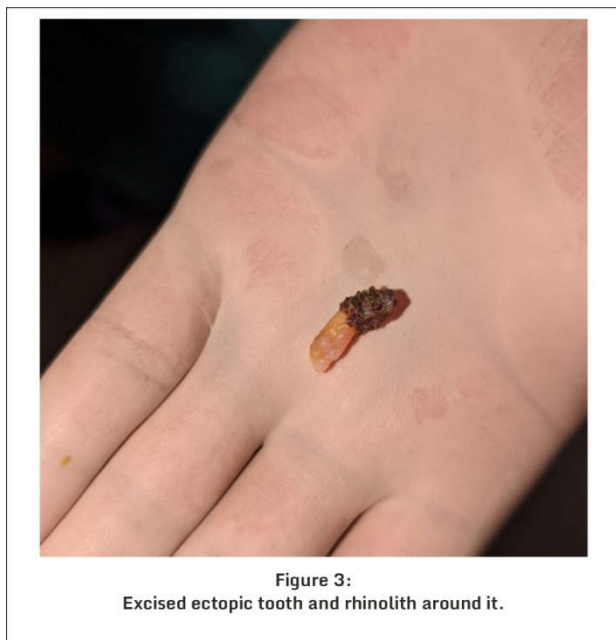
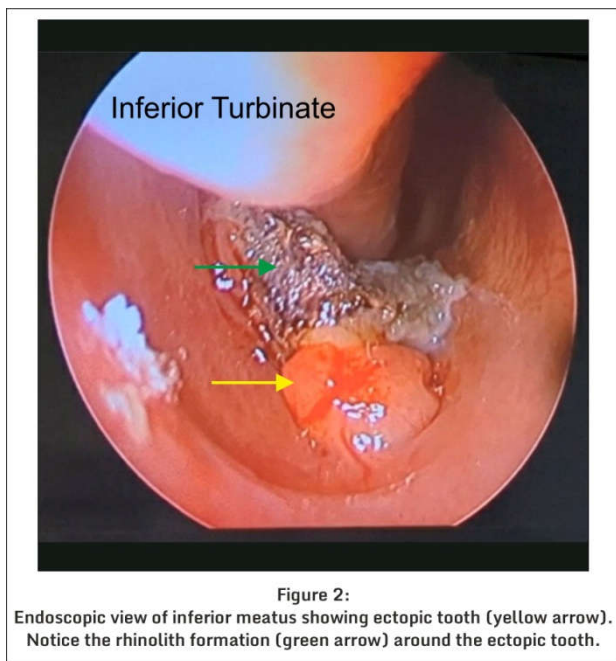


Figure1:
CT Scan showing ectopic tooth (yellow arrow) in the inferior meatus.
Notice the associated pan-sinusitis.



Non contrast computerized tomography (NCCT) nose and of Paranasal sinuses was suggestive of chronic rhinosinusitis of maxillary and ethmoid sinuses on right side with a well defined irregular opacity in the right nasal cavity. Operative procedure was done under general anesthesia. Endoscopic removal of the ectopic tooth along with associated soft tissue and the bony fragments was carried out along with right maxillary antrostomy and ethmoidectomy. No Post-operated complications were reported. Few months later during the follow up of the patient, it was noted that her nasal symptoms were improved remarkably.

DISCUSSION

The etiology of ectopic eruption can be correlated to abnormal development such as cleft palate, benign or malignant lesions, trauma, systemic factors such as osteoporosis, metabolic disorders such as rickets and Genetic disorders as Down syndrome, Patau syndrome that favour dental ectopic position[6] [7]. Ectopic eruption rarely happens in nasal

septum, in coronoid processes, in the palate, in condyle, and in the maxillary sinus due to difficulty for abnormal interaction of tissues during development. The higher prevalence of ectopic teeth is found in the third molar and the canines- teeth that normally take more time to erupt [8]. Ectopic teeth in maxillary sinus or nasal cavity may be asymptomatic or may induce headache, nasal obstruction, rhinorrhoea, pain, swelling, facial fullness, hypoaesthesia of infraorbital nerve, epiphora and fever [9]. The differential diagnosis of nasal teeth includes inflammatory lesions due to tuberculosis, syphilis, fungal infection with calcification, radiopaque foreign body, rhinolith, benign tumors as osteoma, calcified polyps and malignant tumors such as osteosarcoma & Chondrosarcoma [10]. The clinical and Radiologic Findings help in the diagnosis of ectopic tooth. Clinically, an intranasal tooth is seen as a white mass in the nasal cavity surrounded by granulation tissue and debris [11]. Panoramic radiograph, Water graphy, cone-beam computerized tomography (CBCT) and CT can be used in diagnosing ectopic tooth. The computed tomography (CT) findings of tooth-equivalent attenuation and a centrally located cavity are highly discriminating features that help to confirm the diagnosis[12]. So, CBCT and CT possess the advantage of clearly revealing the location and relationship between the tooth and peripheral anatomies. If patient presents no symptom then no treatment is needed but clinical follow-up is must. For symptomatic cases, surgery is the standard and necessary treatment for ectopic teeth. Follow-up with repeated nasal endoscopy and CT of PNS may confirm the proper healing process and resolution of the symptoms.

CONCLUSION

Tooth in Inferior meatus occur from the ectopic eruption of supernumerary teeth. Ectopic tooth is rarely seen anomaly in ENT practice. They are usually misdiagnosed because such teeth are surrounded by hypertrophic nasal mucosa or granulation tissue. However diagnosis of such cases is not difficult. If Patient is suffering from unusual referred pain to the ear, swelling intemporumandibular region, maxillary sinusitis, nasal discharge, lip paresthesia, trismus and preauricular fistula, then patient should be evaluated for diagnosis of ectopic tooth. CT scanning is helpful in planning their management.

List of abbreviations used

- CT (Computed Tomography)
- CBCT (Cone beam computerized Tomography)
- NCCT(Non Contrast Computerized Tomography)
- PNS (Paranasal sinus)

Competing Interests: None

Authors Contributions

1. Stuti Mahajan: Manuscript writing
2. Anupama Mahajan: Analysing the study findings
3. Anukaran Mahajan: Collecting the literature
4. Karunesh Gupta: Concept and Design of the study

Source of Funding: None

References

1. Srinivasaprasad T, Sujatha G, Niazi TM, Rajesh P. Dentigerous cyst associated with an ectopic third

- molar in the maxillary sinus: a rare entity. *Indian J Dent Res* 2007;18:141-3
2. Almomen A, Alkhudair B, Alkhatib A, Alazzah G. Ectopic maxillary tooth as a cause of recurrent maxillary sinusitis: a case report and review of the literature. *J Surg Case Rep* 2020;9:1-3
 3. Kumar V, Bhaskar A, Kapoor R, Malik P. Conservative surgical management of a supernumerary tooth in the nasal cavity. *BMJ Case Rep* 2020;13(7): 25
 4. Agrawal M, Khan TS, Gupta T, Khanna S. Intranasal tooth: ectopic eruption 1 year after maxillofacial trauma. *BMJ Case Rep* 2014;2014: 204432
 5. Akbas M, Karabiyik Z, Varol A. Ectopic tooth in Mandibular canal, Maxillary Sinus and Mandibular condyle. *Case Report* 2022;3118998 <https://doi.org/10.1155/2022/3118998>
 6. Buyukkurt CM, Omezli MM, Miloglu O. Dentigerous cyst associated with an ectopic tooth in the maxillary sinus: a report of 3 cases and review of the literature. *Oral Surgery, Oral medicine, Oral Pathology, Oral Radiology, Endodontology* 2010; 109(1):67-71.
 7. Levin M, Sommer D. Endoscopic removal of ectopic sinonasal teeth: a systematic review. *Journal of Otolaryngology –Head and Neck Surgery* 2019; 48(1): 1-9
 8. Dived C, Dived S, Chaturvedi T, Sharma N. Maxillary antral mucocoele caused by ectopic canine tooth in maxillary sinus. *Eur J Gen Dent* 2013;2:83-5
 9. Altun H, Teker AM, Ceran M. Ectopic molar tooth in the maxillary sinus. *Kulak burunbogaz ihtisderg Journal of ear, nose and throat* 2007;17 (4):237-8
 10. Kumar RA, Kumar PS. Maxillary permanent tooth in the nasal cavity. Report of two cases with different etiopathogenesis, management and review of the literature. *Internet J. Dent. Sci* 2009; 9(1): 767069
 11. Smith RA, Gordon NC, Luchi SF. Intranasal teeth: report of two cases and review of the literature. *Oral Surg Oral Med Oral Pathol* 1979; 47 : 120-122
 12. Alfayez N, Alhumaid SA, Alfayez A. Ectopic Nasal Tooth: A case Report. *International Journal of Surgery case reports* 2021;88:106459

How to cite this article:

Stuti Mahajan *et al* (2022) 'Ectopic Tooth in Inferior Meatus of Nose: A Case Report', *International Journal of Current Advanced Research*, 11(08), pp. 1446-1448. DOI: <http://dx.doi.org/10.24327/ijcar.2022.1448.0320>
