



THREE DIMENSIONAL EVALUATION OF DENS-ATLANTO-OCCIPITAL JOINT RELATION IN PATIENTS WITH TEMPOROMANDIBULAR JOINT DISORDER

Leema R K., Tatu Joy E., Rahul R., Suresh C S and Farakath Khan M

Department of Oral Medicine and Radiology, Sree Mookambika Institute of Dental Sciences, Kulasekharam, Pin code: 629161, Kanyakumari District, India

ARTICLE INFO

Article History:

Received 10th December, 2021

Received in revised form 2nd

January, 2022

Accepted 26th February, 2022

Published online 28th March, 2022

Key words:

Cranio-cervico-mandibular system; Dens-atlanto-occipital joint; Cranio-vertebral junction; Three-dimensional assessment; Temporomandibular joint disorders.

ABSTRACT

Objective: This study was designed to correlate the functional link between TMJ (Temporomandibular joint) dysfunction and altered Dens-Atlanto-Occipital joint relation in patients with temporomandibular disorders (TMDs).

Methods: Archival Cone-beam computed tomography (CBCT) images of 90 TMD patients and 30 healthy controls were subjected for secondary data analysis. The relationship between the Dens-Atlanto-Occipital joint and various grades of TMD were evaluated and statistically analyzed.

Results: TMD severity appeared to increase with the decrease in linear measurement between occipital condyle to dens and increase in both linear measurements between occipital condyle to the atlas, basion to the tip of dens on the symptomatic side. The findings were statistically significant in patients with TMD when compared with controls.

Conclusion: These findings indicate that radiographic evaluation of the Dens-Atlanto-Occipital joint is a reliable indicator of the presence and degree of TMD.

Copyright©2022 **Leema R K et al.** This is an open access article distributed under the Creative Commons Attribution License, which permits unrestricted use, distribution, and reproduction in any medium, provided the original work is properly cited.

INTRODUCTION

Over a long period of time the Stomatognathic System, also designated as Cranio-cervico-mandibular system, has been contemplated as a functionally based system that performs diverse functional tasks such as maintenance of postural control of the cervical region [1]. Alteration in any one of the four main components (Dento-periodontal, Neuromuscular, Osteo-basal, and TMJ) of the stomatognathic system leads to change in all other components as they are linked by a linear relationship.[2].

The TMJ is the fortunate joint in the body with an occlusal conclusive set point in corroborating the mandibular movement in relation to the maxilla as it determines the position of the condyle inside the articular fossa of the temporal bone. A change in the activity of head and neck muscles is brought about by an occlusal imbalance which can cede stress to the Cranio-vertebral Junction (CVJ), and the misalignment of the CVJ can cause stress to the occlusal complex [3].

An abnormal function of the muscles and joints of the cervical region can be a probable cause for the greater frequency of pain in the orofacial region due to the functional relationship between TMJ and Cranio-cervical regions, where movements of the atlanto-occipital and dens-occipital joints can occur concomitantly with the activation of masticatory muscles. Therefore, alterations of head posture in any form, ranging

from acute trauma to a chronic restricted airway could lead to the disruption of motor control of this region, compromising the normal mandibular function.

Since the prevalence of TMD (Temporomandibular disorder) is increasing day by day, the study of associated structures is mandatory to improve the clinical approach in understanding of the etiology and management strategies in patients with TMD. Various researchers have studied the association between TMD, neck pain and altered head posture, but there does not exist a consensus on these elements and the plausible relationships are far from explained. The concept of head posture and cervical column being predisposing factors as well as manifestations of/for TMDs is one marred with debate. Due to this lack of evidence about the causative factor of TMDs, the present study has been undertaken to investigate the functional link between the occurrence of TMJ dysfunction and altered relation of dens-atlanto-occipital joint including changes in angles and lengths of the physical relation of the occipital condyles, atlas and axis as well as to observe the effect of these changes on the severity of TMD. This study also proposes a new algorithm to emphasize the efficacy and potential of Cone beam computed tomography (CBCT) for the appraisal of Dens-Atlanto-Occipital joint relation in patients with TMD.

**Corresponding author: Leema R K*

Department of Oral Medicine and Radiology, Sree Mookambika Institute of Dental Sciences, Kulasekharam, Pin code: 629161, Kanyakumari District, India

MATERIALS AND METHODS

Study sample

This study was carried out at the Department of Oral Medicine and Radiology, Sree Mookambika Institute Of Dental Sciences, Kulasekharam, Kanyakumari district, India in association with Maxillofacial Diagnostics, Kochi. The study was approved by the Institutional Human Ethical Committee [Sree Mookambika Institute of Medical Sciences, Tamil Nadu, with reference number SMIMS/IHEC No: 1/Protocol No: 25/2019]. Informed consent was procured from all the subjects included in the study.

Based on clinical records, archival CBCT images of 120 subjects were collected as samples and divided into 4 groups in accordance with the Joy et al classification: Group I: 30 non-TMD patients, Group II-A: 30 Patients with mild TMD (TMJ disorder without any masticatory muscle tenderness or radiating pain to the shoulders), Group II-B: 30 Patients with moderate TMD (TMJ disorder with masticatory muscle tenderness and radiating pain to the shoulders), Group II-C: 30 Patients with severe TMD (TMJ disorder with masticatory muscle tenderness and radiating pain to shoulders, lower back and sleep disturbances) [4].

The inclusion criteria were as follows: Archival CBCT Images of patients between the age group of 15-50 years without TMD and of patients with detailed case records were divided as mild, moderate and severe TMD between the age group of 15-50 years. The exclusion criteria comprised of archival CBCT images of subjects with the presence of radiographically confirmed congenital /degenerative changes of the vertebrae and dens, acute/chronic musculoskeletal injury, neuropathy, history of protracted systemic medication or physiotherapy and spine surgery.

Parameters evaluated

CBCT was used in this study to visualize osseous structures of Cranio-vertebral junction, owing to its superior voxel resolution.

Coronal view: (Figure 1)

1. Distal, Middle, Mesial linear measurements (A, B, C) between occipital condyles to Atlas (Right and Left)
2. Distal, Middle, Mesial linear measurements (D, E, F) between atlas and axis (Right and Left)
3. Linear measurement (G) between the tip of dens to occipital condyles (Right and Left)
4. Angle measurement (H) between the long axis of the dens to occipital condyles (Right and Left)

Sagittal view: (Figure 2)

1. Linear measurement (I) between basion to the tip of dens
2. Angle measurement (J) between the long axis of dens to a horizontal line joining basion and opisthion (superior and inferior angles)
3. Linear measurement (K) between the tip of dens to opisthion

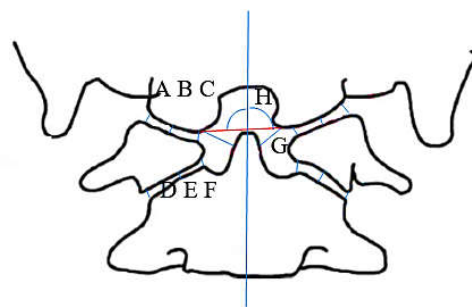


Figure 1 [A, B, C: Distal, Middle, Mesial linear measurements between occipital condyles to atlas; D, E, F: Distal, Middle, Mesial linear measurements between atlas and axis; G: Linear measurement between tip of dens to occipital condyles, H: Angle measurement between the long axis of the dens to occipital condyle;]

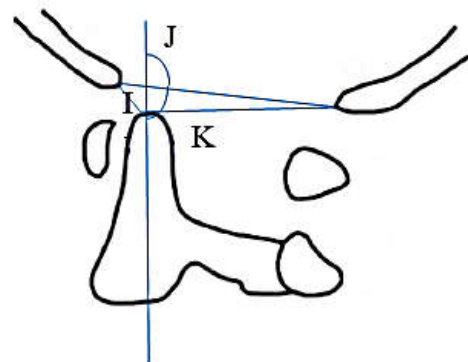


Figure 2 I: Linear measurement between basion to tip of dens; J: Angle measurement between long axis of dens to a horizontal line joining basion and opisthion; K: Linear measurement between tip of dens to opisthion]

Statistical analysis

All measurements were tabulated and data were analyzed using Statistical Package for Social Sciences version 21 (SPSS 21IBM Statistics, USA) windows program. The data are expressed as mean \pm standard deviation. Significant difference in means between the TMD and control groups were determined using post-hoc analysis of variance (ANOVA) with bonferroni tests. A p-value of less than 0.05 was considered as statistically significant at a 95% confidence interval.

RESULTS

Measurement between Occipital condyle to dens showed a statistical significant difference ($p < 0.05$) between groups. In left side TMD patients, the mean values (Figure 3) were as follows: 6.7857 ± 1.67945 in (group IIA) mild TMD patients, 6.6931 ± 1.44249 in (group IIB) moderate TMD patients, and 6.1065 ± 1.83150 in (group IIC) severe TMD patients. In right side TMD patients, the mean values were as follows: 6.3253 ± 2.43053 in (group IIA) mild TMD patients, 6.2931 ± 1.44249 in (group IIB) moderate TMD patients, and 6.13215 ± 0.97794 in (group IIC) severe TMD patients. While comparing these values, with Group I (control) which had a mean value of 7.4650 ± 1.57510 on left side and 6.8433 ± 1.65042 on right side. The result reveals that the measurement between the occipital condyle to dens decreases on the side of TMJ pain with the TMD severity increases.

Furthermore, mean values for the middle measurement between the occipital condyle to the atlas and length measurement between basion to tip of the dens were increasing on the side of TMJ pain and were statistically significant in patients with TMD when compared with controls. Mean values

for the middle measurement between the occipital condyle to the atlas on the left side were as follows: 1.4607±.44301 (Group I), 1.8286±.47555 (Group IIA), 1.7550±.47773 (Group IIB), 1.7159±.56655 (Group IIC). Mean values on the right side were (Figure 4) as follows: 1.3770±.41277 (Group I), 1.6727±.60319 (Group IIA), 1.7550±.47773 (Group IIB), and 1.4515±.36726 (Group IIC). Mean values for the length measurement between basion to tip of the dens on the left side were as follows: 4.9907±1.31112(Group I), 5.5829±1.05345 (Group IIA), 6.5694±2.30421 (Group IIB), 5.4082±1.51066 (Group IIC). Mean values for the length measurement between basion to tip of the dens on the right side (Figure 4) were as follows: 4.9907±1.31112 (Group I), 5.5260±2.08330 (Group IIA), 6.5694±2.30421 (Group IIB), 5.8854±2.40452 (Group IIC).

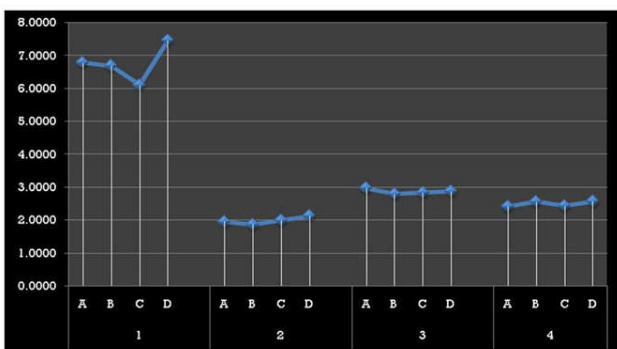


Figure 3 Left side linear measurements (1- measurement between occipital condyle to dens, 2- distal measurement between atlas and axis,3- middle measurement between atlas and axis,4- mesial measurement between atlas and axis,A- mild,B- moderate,C- severe,D-controls)

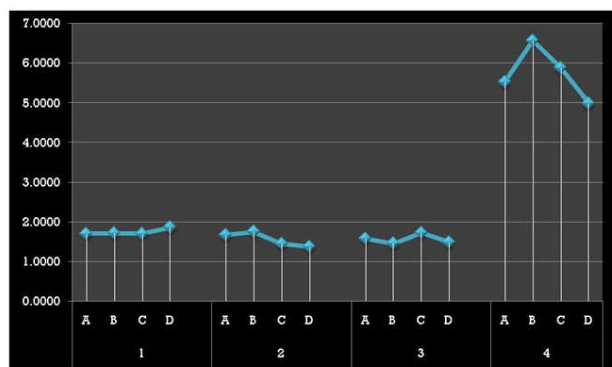


Figure 4 Right side linear measurements (1- mesial measurement between occipital condyle to atlas, 2-middle measurement between occipital condyle to atlas, 3- distal measurement between occipital condyle to atlas, 4- measurement between basion to tip of dens, A- mild, B - moderate, C -severe, D – controls)

Table 1 Comparison of measurement between occipital condyle to dens on left side between Group I and the other groups

		N	Mean	Standard Deviation	p-value
Measurement between basion to tip of dens	Mild	14	5.5829	1.05345	0.019*
	Moderate	16	6.5694	2.30421	
	Severe	17	5.4082	1.51066	
	Controls	30	4.9907	1.31112	

Table 2 Comparison of measurement from basion to tip of dens in left side TMD patients between Group I and the other groups

		N	Mean	Standard Deviation	p-value
Measurement between basion to tip of dens	Mild	14	5.5829	1.05345	0.019*
	Moderate	16	6.5694	2.30421	
	Severe	17	5.4082	1.51066	
	Controls	30	4.9907	1.31112	

Table 3 Comparison of middle measurement between occipital condyle to atlas on right side between Group I and the other groups

		N	Mean	Standard Deviation	p-value
Middle measurement between occipital condyle to atlas	Mild	15	1.6727	.60319	0.039*
	Moderate	16	1.7550	.47773	
	Severe	13	1.4515	.36726	
	Controls	30	1.3770	.41277	

DISCUSSION

When searching data regarding studies on the dens-atlanto-occipital joint, the authors found data that stated the importance of this link, but these were from a bygone era of projection imaging studies. Hence, the authors attempted a CBCT based study which produces images with submillimeter isotropic voxel resolution. The valid and precise methodology as well as standardization of parameters used in this study were specifically designed to focus and interrelate the physiological alteration in the position of Dens-Atlanto-Occipital joint and its significance on the severity of TMJ. This in turn would pave way to translate clinical data directly from a more objective evaluation of the complex anatomy.

The present study provides an unique insight into the field of neuromuscular dentistry by showing variation in the measurements between dens, atlas and occipital condyles in various TMD severity states and the mechanism underlying these data is well explained by the guidelines of the American academy of Orofacial pain, which states that the cervical spine is closely related to the masticatory system and cranium through definite joint articulations, vascular and neural innervations, muscle attachments and the postural balance relation among them is of central importance to perform the functions of the system created by these structures [5].

From the outcome of this study, it becomes evident that the presence of TMD can also exacerbate misalignment and morphometric changes in the position of atlas and occipital condyle with increase in middle measurement between the atlas and occipital condyle and this change in the physiological curve of the atlanto-occipital joint is explained by the compensatory changes in the spatial orientation of ligaments and tensegrity of muscles attached to it. This disruption in the biomechanics produces asymmetry in articulation of the atlanto-occipital joint on the affected side as a result of hypermobility of this joint. As a consequence of this, a higher amount of force is impelled on the cervical vertebrae which causes destruction of its articular facets on the account of excessive straining [6].

Based on the Quadrant Theorem of Guzay, the rotation axis of the mandible lies precisely at the dens which is a tooth-like protuberance from the second cervical vertebra/axis, around which the first vertebra/atlas rotates. In addition, the shape of the occipital condyles conform to the shape of the condyles of the mandible, and the retrusion of the Occipital condyles may coincide with the protrusion of the TMJs [7]. The study result demonstrates that the measurement between the tip of dens to occipital condyle decreases on the symptomatic side of TMJ as the severity of TMD increases and this alteration is because of the deviation from normal structure or function due to misuse of capabilities of the body which evolves into varying degrees of TMD or vice versa. As the distortion increases, there may be a concurrent reduction in the measurement between

occipital condyle to the tip of dens on the affected side. This is brought by deviation in the position of dens towards the affected side. Therefore, this parameter can be used as a reliable indicator to assess the side of the orofacial region which is affected by functional imbalance in varying degrees of TMD.

To minimize the patient's pain or discomfort in TMD, adaptations can occur in certain body structures which leads to deviation in normal body posture [8]. As forward head posture is mostly seen in patients with TMD, this study tried to verify this relationship radiographically by measuring the distance from the tip of dens to basion which is the midpoint on the anterior margin of the foramen magnum which indicates the position of the spine in relation to the head. An increase in the distance from basion to tip of dens is a sign of loss of Cranio-vertebral junction integrity and this is most commonly observed in patients with Cranio-vertebral junction injuries [9]. Similarly, this study also showed this variation as an incidental finding in patients with TMD and authors believe that this change can be due to a more anterior position of the foramen magnum with respect to dens as an adaptation for maintaining head balance.

In totality, there is a unilateral flexion of the atlanto-occipital joint and a latero-posterior tug at the dens in relation to the basion and occipital condyle. This change at the apex of the spinal structure would certainly send a rippling effect down to the spinal skeleton.

The findings of the present study unravel the hidden truth by showing alterations in the Dens-Atlanto-Occipital joint relation in patients with TMD and this rigorous study supports the cause-effect relationship. Moreover, this study is a frontrunner that demonstrates the need for evaluating the Dens-Atlanto-Occipital joint relation in TMD patients for formulating comprehensive treatment strategies. Overall, this study provides a final conclusion to affirm the direct relation between TMD and the Craniovertebral junction.

Nevertheless, as it was a transverse study the subjects were evaluated only once; therefore variation over time in each individual was not considered. This study was limited only to assess the changes in C₁ and C₂ spines and alterations in other cervical spines were not assessed. However, further studies are warranted to monitor modifications in the entire spinal column, ligaments, and muscles of the Cranio-cervicomandibular system and the changes once the neuromuscular/TMD corrections are completed. Surely these parameters will help as a clinical prognosticator and guide to healing in these patients.

CONCLUSION

In the recent epoch of evidence-based health care practice, reliability and objectivity are essential for the accomplishment of an effective treatment protocol.

This original study paves a way for qualitative, realistic as well as accurate three-dimensional assessment of Dens-atlanto-occipital joint in TMD patients. Adequate knowledge of complex anatomy, topographic relationships of Cranio-vertebral junction with respect to TMJ in association with appropriate clinical and radiological evaluation can provide a meaningful diagnosis.

Funding

Self-funded/No external funding

Disclosure Statement

No potential conflict of interest was reported by the authors.

References

1. Messina G. The tongue, mandible, hyoid system. *Eur J Transl myol.* 2017; 27 (1): 74-76.
2. Pacella E, Dari M, Giovannoni D, Caterini L, Mezio M. The relationship between occlusion and posture: a systematic review. *Webmed central.* 2017;8(10): 1-5.
3. Thomas NR, Thomas TD, Thomas NR. The Relationship between the Dental Occlusion, Upper Cervical spine and Temporomandibular Joints prior to and following TENS treatment in thirty-six patients suffering from Temporomandibular Disorder. *Int J Dent Oral Health.* 2019; 4(1):14-20.
4. Joy TE, Kiran M S, Jasmin SL S, Babu Kurra S. Evaluation of vertical facial height reduction and severity of temporomandibular joint disorders using Shimbashi number and cephalometric analysis. *Cranio.* 2019:1-7.
5. Matheus RA, Perez FM, Menezes AV, Ambrosano GM, Neto F, Boscolo FN, Almeida SM. The relationship between temporomandibular dysfunction and head and cervical posture. *J Appl Oral Sci.* 2009;17(3):204-8.
6. Joy TE, Tanuja S, Pillai RR, Dhas Manchil PR, Raveendranathan R. Assessment of Craniocervical posture in TMJ disorders using lateral radiographic view: A cross-sectional study. *Cranio.* 2019:1-7.
7. Glastier J. Temporomandibular dysfunction and systemic distress. *Int Dent J.* 2012;2(1):201276-80.
8. Saito ET, Akashi PM, Sacco ID. Global body posture evaluation in patients with the temporomandibular joint disorder. *Clinics (Sao Paulo).* 2009;64(1):35-9.
9. Singh AK, Fulton Z, Tiwari R, Zhang X, Lu L, Altmeyer WB, Tantiwongkosi B. Basion-Cartilaginous Dens Interval: An Imaging Parameter for Craniovertebral Junction Assessment in Children. *Am J Neuroradiol.* 2017;38(12):2380-4.

How to cite this article:

Leema R K *et al* (2022) 'Three Dimensional Evaluation of Dens-Atlanto-Occipital Joint Relation In Patients With Temporomandibular Joint Disorder', *International Journal of Current Advanced Research*, 11(03), pp. 397-400.
DOI: <http://dx.doi.org/10.24327/ijcar.2022.400.0089>
