



**Research Article**

## **CORRELATION OF CBCT MIDPALATAL SUTURE MORPHOLOGY WITH SECOND MOLAR CALCIFICATION, CVMI AND MP3 SKELETAL MATURITY INDICATORS**

**RevathiSomasundaram., Prashanth.C.S., Amarnath.B.C., Dharma.R.M, Akshaisetty.,  
Manjunath Hegde and Roopak Mathew David**

Department of Orthodontics, D.A.P.M.R.V Dental College, Bengaluru, Karnataka, India

### **ARTICLE INFO**

**Article History:**

Received 4<sup>th</sup> October, 2021

Received in revised form 25<sup>th</sup>

November, 2021

Accepted 18<sup>th</sup> December, 2021

Published online 28<sup>th</sup> January, 2022

**Key words:**

Midpalatal suture; Cervical Vertebrae; Second molar calcification; Middle Phalanx of third finger; Cone beam computed tomography.

### **ABSTRACT**

**Background:** Through assessment of the midpalatal suture morphology, it was found out that it is possible to minimize the failure of rapid maxillary expansion in adolescent and young adult patients. However, it is not possible to obtain routine CBCT of every patient, and especially those without any diagnostic need (e.g., impacted tooth, cyst). Hence the present study is taken up to correlate Angelieri et al CBCT classification of midpalatal suture morphology with routinely used various skeletal maturity indicators like Second molar calcification stages by Demirjian, CVMI stages by Hassel and Farman and MP3 stages by Hagg and Tarranger which are available as a part of the routinely obtained diagnostic records for patients requiring maxillary expansion.

**Methods:** The study was performed using CBCT of axial view of maxilla, Orthopantomograms, lateral cephalograms, Intra oral periapical radiographs of Middle phalanx of third finger obtained from 25 patients aged between 10 to 25 years seeking orthodontic treatment.

**Results:** The results showed that Correlation between Cervical vertebrae maturation stages and CBCT (midpalatal suture) stages values showed statistically highly significant correlation( $p < 0.001$ ). Correlation between middle phalanx of third finger stages and CBCT (midpalatal suture) stages values showed statistically highly significant correlation( $p < 0.001$ ). Correlation between second molar calcification stages and CBCT (midpalatal suture) stages values showed statistically significant correlation( $p < 0.008$ )

**Conclusion:** Among developmental age indices, CVMI and MP3 Showed highly significant correlation, suggesting that they can be useful in assessing maturation of the midpalatal suture.

Copyright©2022 *RevathiSomasundaram et al.* This is an open access article distributed under the Creative Commons Attribution License, which permits unrestricted use, distribution, and reproduction in any medium, provided the original work is properly cited.

### **INTRODUCTION**

Transverse growth of maxilla is the first to cease followed by anteroposterior and vertical dimensions, it stops when the first bridging of midpalatal suture begins. This usually means that by early adolescence, palatal width growth would normally end and to mechanically alter this later with appliance therapy, would require heavier forces. Hence it is important to know the patency of mid palatal suture.<sup>16</sup>

The increase in the maxillary arch transverse dimension by means of rapid maxillary expansion (RME) has been a routine treatment modality in present day orthodontic practice, it is an established and credible tool for treating maxillary transverse deficiency.<sup>21</sup>

Patency of midpalatal suture has been one of most important diagnostic criteria for the patients who undergo rapid maxillary expansion. There are conflicting views about the closure of midpalatal suture.<sup>21</sup>The chronological age does not seem to be

a reliable indicator of morphological status of the midpalatal suture.<sup>10</sup>

Melson (1975) analysed palatal growth and midpalatal suture morphology in humans from 0 to 18 years of age. The morphological development was divided into three stages. In the first stage suture was short, broad, and y shaped, in the second more sinuous and in the third heavy inter digitation occurred.<sup>10</sup>

In a histologic study, Person and Thilander (1977) investigated palatal suture from 15 to 35 years of age. It was demonstrated that palatal suture may show obliteration during the juvenile period but a marked degree of closure was rarely found until the third decade of life.<sup>4</sup>

Revelo and fishman proposed individual assessment of midpalatal suture morphology with occlusal radiographs before RME therapy.<sup>7</sup> However occlusal radiographs are not reliable for analysing midpalatal suture morphology because vomer and structures of external nose overlay the midpalatal

\*Corresponding author: **RevathiSomasundaram**

Department of Orthodontics, D.A.P.M.R.V Dental College,  
Bengaluru, Karnataka, India

area and thus might lead to false radiographic interpretation of midpalatal suture fusion.<sup>29</sup>

Cone-beam computed tomography (CBCT) provides 3-dimensional visualization of the oral and maxillofacial structures at relatively low cost, no superimposition of adjacent structures, easy accessibility, and low radiation exposure compared with multislice medical computed tomography.<sup>20</sup>

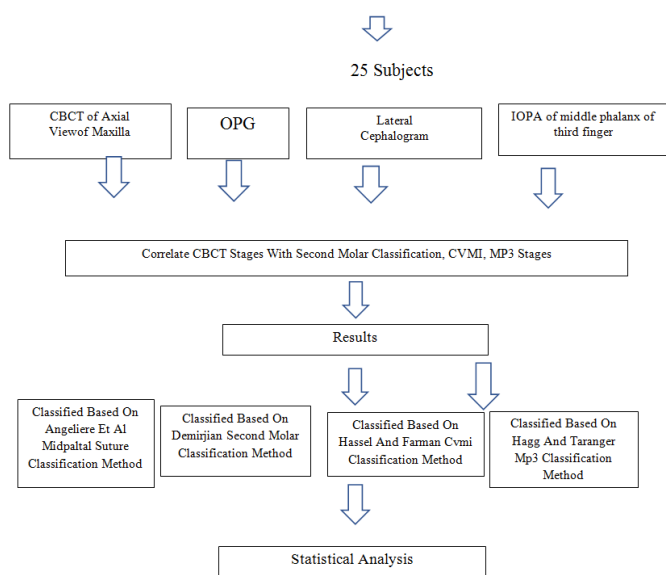
Angelieri et al proposed, an individual evaluation method of midpalatal suture with Cone beam computed tomography. By observing the images of the suture in different stages of calcification, 5 maturational stages were determined: A, B, C, D, and E. Among these, treatment with RME would have less resistance and consequently greater skeletal effect in stages A and B than in stage C, where ossification areas are already observed along the suture. For patients in stages D and E, surgically assisted expansion is better indicated because at these stages fusion of the palatal suture has already occurred partially or totally.<sup>29</sup>

Through assessment of the midpalatal suture morphology, it was found out that it is possible to minimize the failure of rapid maxillary expansion in adolescent and young adult patients. However, it is not possible to obtain routine CBCT of every patient, and especially those without any diagnostic need (e.g., impacted tooth, cyst, and skeletal asymmetry).<sup>36</sup>

Hence the present study was taken up to correlate Angelieri et al CBCT classification of midpalatal suture morphology<sup>29</sup> with routinely used various skeletal maturity indicators like Second molar calcification stages by Demirjian<sup>3</sup>, CVMI stages by Hassel and Farman<sup>8</sup> and MP3 stages by Hagg and Tarranger<sup>9</sup> which are available as a part of the routinely obtained diagnostic records for patients requiring maxillary expansion.

## MATERIALS AND METHODS

Outline of the study



### Sample Size

The sample consists of CBCT images of maxilla, radiographs of middle phalanx of third finger and routinely obtained panoramic radiographs, Lateral cephalograms of 25 patients aged between 10 to 25 years seeking orthodontic treatment.

### Inclusion Criteria

1. Chronological age ranging from 10 to 25 years
2. Normal overall growth and development

### Exclusion criteria

1. Disease or medicine intake affecting bone metabolism
2. Previous history of trauma
3. Poor quality images that are difficult to distinguish

## METHODOLOGY

The study was performed using CBCT of axial view of maxilla<sup>29</sup>, Orthopantomograms<sup>3</sup>, lateral cephalograms<sup>8</sup>, Intra oral periapical radiographs of Middle phalanx of third finger<sup>9</sup> obtained from 25 patients.

15 patients CBCT taken from CBCT machine -J MORITA'S VERAVIEW X 800. Software used IDIXEL, images were taken using the following parameters: 105 kVp, 9.4 seconds scan time and field-of-view 80×80mm. (FIG-1,2,3)

10 patients CBCT taken from CBCT machine-CARESTREAM 8100. Software used CARE STREAM IMAGING SOFTWARE, images were taken using the following parameters: 105 kVp, 10.8 seconds scan time and field-of-view 80×80mm.

Each subject was standing in an erect position with the Frankfort horizontal plane (superior aspect of the external auditory canal to the infraorbital rim line) parallel to the ground during scanning process. The images were converted to Digital Imaging and Communication in Medicine (DICOM) format. DICOM files were reconstructed into a three-dimensional image by multiplanar reformatting and volume rendering using imaging software.

Tracings were made from lateral cephalogram, opg and middle phalanx x ray on a matte acetate tracing sheet and 0.3mm micro lead pencil.

### Evaluation of midpalatal suture morphology using cone beam computerized tomography:

The evaluation of the mid palatal suture morphology using CBCT images were classified into five stages (stage A - E) as suggested by Angelieri et al<sup>29</sup>. (FIG-1)

### Evaluation of dental maturity using panoramic radiograph

Calcification of second molar were evaluated according to the index described by Demirjian et al (Demirjian index DI), in which one of the eight stages of calcification (A to H) was assigned to the tooth<sup>3</sup>. (FIG-2)

### Evaluation of skeletal maturity using Lateral Cephalogram

Cervical vertebrae maturity were evaluated by classifying C2, C3 and C4 into six groups depending on their maturation pattern on the lateral Cephalogram using the classification given by Hassel and Farman<sup>8</sup>. (FIG-3)

### Evaluation of skeletal maturity using radiograph of middle phalanx of the third finger

The ossification of middle phalanx of the third finger of the hand (MP3) were evaluated by using Hagg and Tarranger method of classification<sup>9</sup>. (FIG-4)

CBCT, CVMI, MP3 and second molar calcification stages were recorded by examiner 1 and it was re-evaluated by examiner 2 to eliminate inter examiner bias.

**RESULTS**

The present study was taken up to correlate Angelieri et al CBCT classification of midpalatal suture morphology with routinely used various skeletal maturity indicators like Second molar calcification stages by Demirjian, CVMI stages by Hassel and Farman and MP3 stages by Hagg and Tarranger in 25 patients aged between 10 to 25 years seeking orthodontic treatment.

**Demographics of the sample**

The distribution of the total sample and its gender related to each developmental age index according to CBCT stage (maturation of midpalatal suture) are presented. (Table 1, 2, 3)

**Table 1** Age and Gender Distribution among Study Subjects

Age and Gender Distribution among Study Subjects			
Variables	Category	n	%
Age	10-15 years	14	56%
	16-20 years	6	24%
	21-23 years	5	20%
Gender	Males	11	44%
	Females	14	56%

**Table 2** Demographics of The Sample Subjects

Demographics of the sample subjects of all Indices			
Indices	Stages	n	%
CVMI Stage	Stage 2	7	28%
	Stage 3	1	4%
	Stage 4	5	20%
	Stage 6	12	48%
II Molar Calcification Stage	Stage D	1	4%
	Stage E	2	8%
	Stage F	7	28%
	Stage G	6	24%
MP3 Stage	Stage H	9	36%
	Stage F	3	12%
	Stage FG	3	12%
	Stage G	2	8%
CBCT Mid Palatal Suture Stage	Stage H	5	20%
	Stage I	12	48%
	Stage A	2	8%
	Stage B	6	24%
	Stage C	11	44%
	Stage D	5	20%
		1	4%

**Table 3** Gender Based Comparison of Different Indices

Gender based comparison of different Indices using Chi Square Test							
Indices	Stages	Males		Females		$\chi^2$ Value	P-Value
		n	%	n	%		
CVMI Stage	Stage 2	4	36.4%	3	21.4%	2.959	0.39
	Stage 3	1	9.1%	0	0.0%		
	Stage 4	1	9.1%	4	28.6%		
	Stage 6	5	45.5%	7	50.0%		
II Molar Calcification Stage	Stage D	1	9.1%	0	0.0%	4.515	0.34
	Stage E	2	18.2%	0	0.0%		
	Stage F	3	27.3%	4	28.6%		
	Stage G	2	18.2%	4	28.6%		
MP3 Stage	Stage H	3	27.3%	6	42.9%	6.196	0.19
	Stage F	3	27.3%	0	0.0%		
	Stage FG	2	18.2%	1	7.1%		
	Stage G	1	9.1%	1	7.1%		
CBCT Mid Palatal Suture Stage	Stage H	1	9.1%	4	28.6%	0.945	0.92
	Stage I	4	36.4%	8	57.1%		
	Stage A	1	9.1%	1	7.1%		
	Stage B	3	27.3%	3	21.4%		
Suture Stage	Stage C	5	45.5%	6	42.9%		
	Stage D	2	18.2%	3	21.4%		
	Stage E	0	0.0%	1	7.1%		

**Correlation between indices using a rank order correlation analysis**

Correlation between Cervical vertebrae maturation stages and CBCT (mid palatal suture) stages were investigated. All values showed statistically significant correlation ( $p < 0.001$ ). The same analysis was performed according to gender. Statistically significant correlation was found in both male and female subjects ( $p < 0.001$ ). (Table 4)

**Table 4** Correlation between CVMI and CBCT Midpalatal Suture Morphology

Spearman's correlation statistics to assess the relationship between cvmi stages and CBCT Mid palatal suture stages								
Samples	CVMI Stage	CBCT Mid Palatal Suture Stage					rho Value	P-Value
		Stage A	Stage B	Stage C	Stage D	Stage E		
Overall	Stage 2	2	3	2	0	0	0.73	<0.001*
	Stage 3	0	0	1	0	0		
	Stage 4	0	3	2	0	0		
	Stage 6	0	0	6	5	1		
Males	Stage 2	1	2	1	0	0	0.73	<0.001*
	Stage 3	0	0	1	0	0		
	Stage 4	0	1	0	0	0		
	Stage 6	0	0	3	2	0		
Females	Stage 2	1	1	1	0	0	0.75	<0.001*
	Stage 3	0	0	0	0	0		
	Stage 4	0	2	2	0	0		
	Stage 6	0	0	3	3	1		

Correlation between middle phalanx of third finger stages and CBCT (mid palatal suture) stages were investigated. All values showed statistically significant correlation ( $p < 0.001$ ). The same analysis was performed according to gender. Statistically significant correlation was found in both males ( $p < 0.03$ ) and females ( $p < 0.04$ ). (Table 5)

**Table 5** Correlation between Mp3 and CBCT Midpalatal Suture Morphology

Spearman's Correlation Statistics to assess the relationship between MP3 Stages and CBCT Mid Palatal Suture Stages								
Samples	MP3 Stages	CBCT Mid Palatal Suture Stage					rho Value	P-Value
		Stage A	Stage B	Stage C	Stage D	Stage E		
Overall	Stage F	0	2	1	0	0	0.61	0.001*
	Stage FG	1	0	2	0	0		
	Stage G	0	2	0	0	0		
	Stage H	1	1	3	0	0		
	Stage I	0	1	5	5	1		
Males	Stage F	0	2	1	0	0	0.66	0.03*
	Stage FG	1	0	1	0	0		
	Stage G	0	1	0	0	0		
	Stage H	0	0	1	0	0		
	Stage I	0	0	2	2	0		
Females	Stage F	0	0	0	0	0	0.54	0.04*
	Stage FG	0	0	1	0	0		
	Stage G	0	1	0	0	0		
	Stage H	1	1	2	0	0		
	Stage I	0	1	3	3	1		

**Table 6** Correlation between II Molar Calcification Stages and CBCT Midpalatal Suture Morphology

Spearman's Correlation Statistics to assess the relationship between II Molar Calcification Stages and CBCT Mid Palatal Suture Stages								
Samples	II Molar Calcification	CBCT Mid Palatal Suture Stage					rho Value	P-Value
		Stage A	Stage B	Stage C	Stage D	Stage E		
Overall	Stage D	0	0	1	0	0	0.52	0.008*
	Stage E	1	1	0	0	0		
	Stage F	1	3	2	1	0		
	Stage G	0	1	4	1	0		
	Stage H	0	1	4	3	1		
Males	Stage D	0	0	1	0	0	0.62	0.04*
	Stage E	1	1	0	0	0		
	Stage F	0	2	1	0	0		
	Stage G	0	0	1	1	0		
	Stage H	0	0	2	1	0		
Females	Stage D	0	0	0	0	0	0.40	0.16
	Stage E	0	0	0	0	0		
	Stage F	1	1	1	1	0		
	Stage G	0	1	3	0	0		
	Stage H	0	1	2	2	1		

Correlation between second molar calcification stages and CBCT (mid palatal suture) stages were investigated. All values showed statistically significant correlation ( $p < 0.008$ ). The same

analysis was performed according to gender. Statistically significant correlation was found in males( $p<0.04$ ) and in females it is not significant .(Table 6)

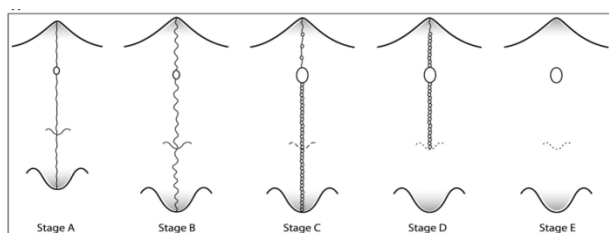
**Association between indices using contingency coefficients**

The results of crosstab analysis between CBCT stage and Second molar calcification stage,CVMI,MP3 stage are shown in table 7. All measurements showed significant correlation ( $p<0.001$ ).

**Table 7** Association between CBCT Stage and Maturation Indices

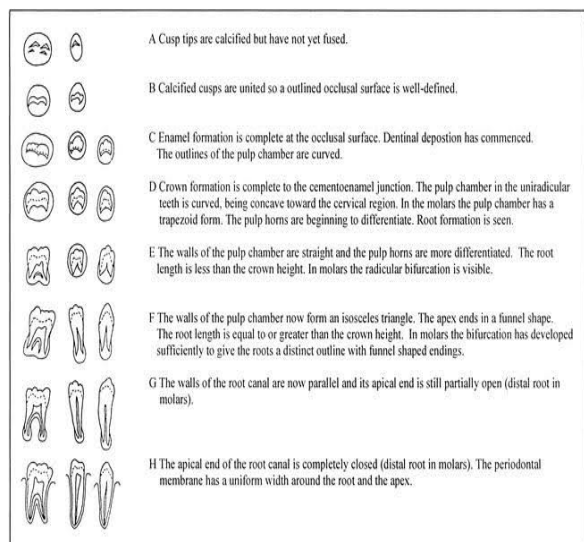
Analysis of associations between CBCT stage and maturation indices using crosstabs							
CBCT Stage	Other Indices	Total		Males		Females	
		$\gamma$	$\tau$ -b	$\gamma$	$\tau$ -b	$\gamma$	$\tau$ -b
Mid Palatal Suture Stages	CVMI	0.89	0.65	0.87	0.65	0.92	0.67
		<0.001*	<0.001*	<0.001*	<0.001*	<0.001*	<0.001*
	II Molar Calcification	0.61	0.45	0.66	0.52	0.50	0.36
		0.002*	0.002*	0.14	0.14	0.003*	0.003*
		0.69	0.51	0.71	0.56	0.67	0.46
MP3 Stages	<0.001*	<0.001*	<0.001*	<0.001*	0.002*	0.002*	

Cross tab analysis by contingency coefficients showed that CVMI and MP3 both showed significantly high correlation( $p<0.001$ ) but the MP3 values in female subjects( $p<0.002$ ) showed a slightly low correlation values compared to CVMI( $p<0.001$ ).

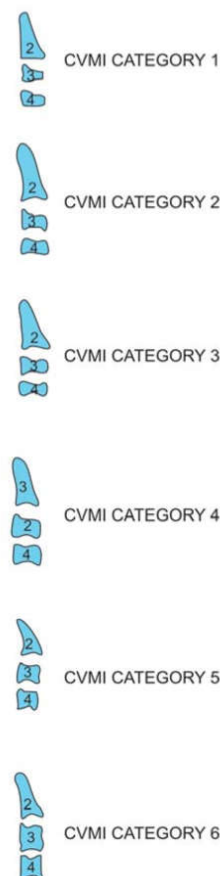


**Fig 1** Angeliere Et Al Cbct Classification of Midpalatal Suture Morphology (Stage A to E)

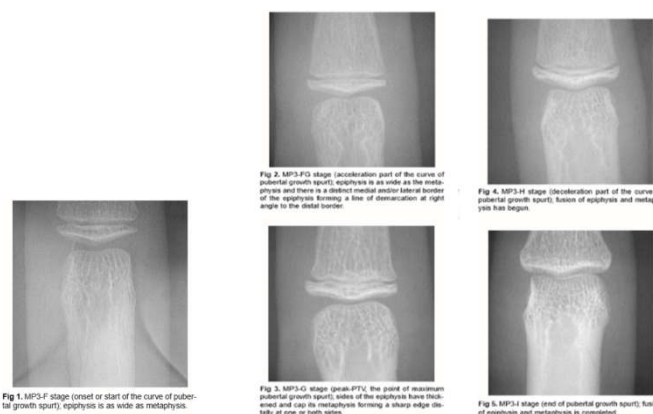
Stage A, straight high-density sutural line, with no or little interdigitation  
 Stage B, scalloped appearance of the high-density sutural line  
 Stage C, 2 parallel, scalloped, high-density lines that were close to each other, separated in some areas by small low-density space  
 Stage D, fusion completed in the palatine bone, with no evidence of a suture  
 Stage E, fusion anteriorly in the maxilla.



**Fig 2** Second Molar Calcification Stages By Demirjian



**Fig 9** CVMI Stages by Hassel and Farman



**Fig 11** Middle Phalanx of Third Finger Stages By Hagg Andतरanger

**DISCUSSION**

Transverse discrepancy of maxilla is one of the most common skeletal problems in the craniofacial region. It is characterised by presence of unilateral or bilateral posterior crossbite, deep or high arched palate, dental crowding, dark spaces in the buccal corridors etc<sup>30</sup>.

Maxillary transverse arch width deficiency normally do not present an orthodontic challenge if they are detected before or during the adolescent growth spurt. Correction of these deficiencies can be done with a maxillary rapid palatal expander<sup>12</sup>.

According to Proffit by the late teens interdigitation and areas of bony bridging across the suture develop to the point that maxillary expansion becomes impossible. The palatal suture reportedly close as when a patient reaches 12 to 13 years of age<sup>12</sup>.

Revelo and Fishman in their study on midpalatal suture ossification found that by the end of skeletal maturation only 50% of the midpalatal suture was ossified<sup>7</sup>.

According to Melson, response to orthopaedic maxillary expansion differ depending on the age and maturation of the patient. The interdigitation of the midpalatal suture increases as it matures, making skeletal expansion more difficult. As a result, expansion of maxilla leads to a tipping movement of teeth, which increases the risk of relapse because of dental expansion is greater than that of orthopaedic expansion. It is possible to expand the maxilla using a removable or fixed appliance such as HYRAX (Hygienic Rapid Palatal Expander) in young patients because structure of the suture is simple. However, with increased complexity of the suture, as occur in adults, different treatment methods such as surgically Assisted Rapid Palatal Expansion (SARPE) should be used. Recently a new method that can load orthopaedic pressure directly to the bone (i.e. Miniscrew Assisted Rapid Palatal Expansion) MARPE has been introduced in clinical practice<sup>36</sup>.

Assessing Patency of midpalatal suture has been one of most important diagnostic criteria for the patients who undergo rapid maxillary expansion. Angeliere et al presented a novel classification method for individual assessment of midpalatal suture morphology. Cone-beam computed tomography images from 140 subjects (ages, 5.6-58.4 years) were examined to define the radiographic stages of midpalatal suture maturation. Five stages of maturation of the midpalatal suture were identified and defined: stage A, straight high-density sutural line, with no or little interdigitation; stage B, scalloped appearance of the high-density sutural line; stage C, 2 parallel, scalloped, high-density lines that were close to each other, separated in some areas by small low-density spaces; stage D, fusion completed in the palatine bone, with no evidence of a suture; and stage E, fusion anteriorly in the maxilla<sup>29</sup>.

In the present study three different skeletal maturity indicators (Cervical Vertebrae Maturity Index (CVMI), Second molar calcification, MP3) were used to correlate them with midpalatal suture ossification as seen in CBCT, in subjects having transverse maxillary deficiency.

To evaluate the morphology of the midpalatal suture according to maturation, CBCT images were assessed according to classification done by Angeliere et al. In the study done by Angeliere et al, Stages A and B typically were observed up to 13 years of age, whereas stage C was noted primarily from 11 to 17 years but occasionally in younger and older age groups. Fusion of the palatine (stage D) and maxillary (stage E) regions of the midpalatal suture was completed after 11 years only in girls. From 14 to 17 years, 3 of 13 (23%) boys showed fusion only in the palatine bone (stage D)<sup>29</sup>. These results were similar to those in present study also. Stage A and B was observed mostly in ages 10 to 13 years. In this study fusion of midpalatal suture below age 11 was not seen; compared with Angeliere et al. Stage C had relatively more dense distribution from 10 years to 17 years.

The correlation analysis in this study showed statistical significance for all index values. Among them the CVMI and MP3 stage showed strong correlation with CBCT stage ( $p < 0.001$ ). This result was similar to the findings of other studies showing strong correlations between facial skeletal growth and skeletal age. Difference being, previous studies

evaluated facial size by linear growth of the mandible, but the current study evaluated maturation of the midpalatal suture.

The crosstab analysis using a contingency coefficient was performed additionally (Table 7). when crosstab analysis was performed with CBCT stages, the CVMI and MP3 showed higher significant values ( $p < 0.001$ ) than Second molar calcification stages. This means that maturation based on the morphology of the midpalatal suture was more consistent with skeletal age than with dental age. This further demonstrates that when predicting the morphology of midpalatal suture it can be expected that skeletal age (CVMI and MP3) is a more useful index than dental age.

A shortcoming that must be considered in maxillary expansion is other anatomical structures that resist expansion force. It is well known that resisting anatomical structures include not only the midpalatal suture, but also the zygomaticotemporal suture, zygomaticofrontal suture, and zygomaticomaxillary suture, among others.<sup>26</sup> Only the midpalatal suture was considered in this study<sup>29</sup>.

In the present study among developmental age indices, the CVMI and MP3 showed strong correlations and high associations with the maturation stage of the midpalatal suture on CBCT images

## CONCLUSION

In this study, we evaluated maturation stage based on the morphology of the midpalatal suture on CBCT images, and investigated correlations and associations between the maturation stage of the midpalatal suture and developmental age indices.

Among developmental age indices, the CVMI and MP3 showed strong correlations and high associations with the maturation stage of the midpalatal suture on CBCT images, meaning that these methods can be used to speculate on the maturation of the midpalatal suture according to its morphology.

## References

1. Davis WM, Kronman JH. Anatomical changes induced by splitting of the midpalatal suture. *The Angle Orthodontist*. 1969 Apr;39(2):126-32.
2. Latham RA. The development, structure and growth pattern of the human mid-palatal suture. *Journal of anatomy*. 1971 Jan;108(Pt 1):31.
3. Demirjian A, Goldstein H, Tanner JM. A new system of dental age assessment. *Human biology*. 1973 May 1:211-27.
4. Persson M, Thailander B. Palatal suture closure in man from 15 to 35 years of age. *American journal of orthodontics*. 1977 Jul 1;72(1):42-52.
5. FISHMAN LS. Chronological versus skeletal age, an evaluation of craniofacial growth. *The Angle Orthodontist*. 1979 Jul;49(3):181-9.
6. Fishman LS. Radiographic evaluation of skeletal maturation: a clinically oriented method based on hand-wrist films. *The Angle Orthodontist*. 1982 Apr;52(2):88-112.
7. Revelo B, Fishman LS. Maturational evaluation of ossification of the midpalatal suture. *American journal of orthodontics and dentofacial orthopaedics: official publication of the American Association of*

- Orthodontists, its constituent societies, and the American Board of Orthodontics. 1994 Mar;105(3):288.
8. Hassel B, Farman AG. Skeletal maturation evaluation using cervical vertebrae. *American Journal of Orthodontics and Dentofacial Orthopaedics*. 1995 Jan 1;107(1):58-66.
  9. Abdel-Kader HM. The reliability of dental x-ray film in assessment of MP3 stages of the pubertal growth spurt. *American journal of orthodontics and dentofacial orthopaedics*. 1998 Oct 1;114(4):427-9.
  10. Wehrbein H, Yildizhan F. The mid-palatal suture in young adults. A radiological-histological investigation. *The European Journal of Orthodontics*. 2001 Apr 1;23(2):105-14.
  11. Krailassiri S, Anuwongnukroh N, Dechkunakorn S. Relationships between dental calcification stages and skeletal maturity indicators in Thai individuals. *The Angle Orthodontist*. 2002 Apr;72(2):155-66.
  12. Stuart DA, Wiltshire WA. Rapid palatal expansion in the young adult: time for a paradigm shift?. *Journal-Canadian Dental Association*. 2003 Jun;69(6):374-7. Apr;72(2):155-66.
  13. Flores-Mir C, Nebbe B, Major PW. Use of skeletal maturation based on hand-wrist radiographic analysis as a predictor of facial growth: a systematic review. *The Angle Orthodontist*. 2004 Feb;74(1):118-24.
  14. Baccetti T, Franchi L, McNamara Jr JA. The cervical vertebral maturation (CVM) method for the assessment of optimal treatment timing in dentofacial orthopedics. In *Seminars in Orthodontics 2005 Sep 1 (Vol. 11, No. 3, pp. 119-129)*. WB Saunders.
  15. Flores-Mir C, Burgess CA, Champney M, Jensen RJ, Pitcher MR, Major PW. Correlation of skeletal maturation stages determined by cervical vertebrae and hand-wrist evaluations. *The Angle Orthodontist*. 2006 Jan;76(1):1-5.
  16. Proffit WR, Fields HW, Sarver DM. *Contemporary orthodontics*. 5<sup>th</sup> ed. St Louis: Elsevier/Mosby; 2013
  17. N'Guyen T, Gorse FC, Vacher C. Anatomical modifications of the mid palatal suture during ageing: a radiographic study. *Surgical and Radiologic Anatomy*. 2007 Apr 1;29(3):253-9.
  18. Korbmayer H, Schilling A, Püschel K, Amling M, Kahl-Nieke B. Age-dependent three-dimensional microcomputed tomography analysis of the human midpalatal suture. *Journal of Orofacial Orthopedics/Fortschritte der Kieferorthopädie*. 2007 Sep 1;68(5):364-76.
  19. Lione R, Ballanti F, Franchi L, Baccetti T, Cozza P. Treatment and posttreatment skeletal effects of rapid maxillary expansion studied with low dose computed tomography in growing subjects. *American journal of orthodontics and dentofacial orthopedics*. 2008 Sep 1;134(3):389-92.
  20. N'Guyen T, Ayril X, Vacher C. Radiographic and microscopic anatomy of the mid-palatal suture in the elderly. *Surgical and Radiologic Anatomy*. 2008 Feb 1;30(1):65-8.
  21. De Vos W, Casselman J, Swennen GR. Cone-beam computerized tomography (CBCT) imaging of the oral and maxillofacial region: a systematic review of the literature. *International journal of oral and maxillofacial surgery*. 2009 Jun 1;38(6):609.
  22. Thadani M, Shenoy U, Patle B, Kalra A, Goel S, Toshinawal N. Midpalatal suture ossification and skeletal maturation: a comparative computerized tomographic scan and roentgenographic study. *Journal of Indian Academy of Oral Medicine and Radiology*. 2010 Apr 1;22(2):81.
  23. Ghoneima A, Abdel-Fattah E, Hartsfield J, El-Bedwehi A, Kamel A, Kula K. Effects of rapid maxillary expansion on the cranial and circummaxillary sutures. *American Journal of Orthodontics and Dentofacial Orthopedics*. 2011 Oct 1;140(4):510-9.
  24. Primožič J, Perinetti G, Richmond S, Ovsenik M. Three-dimensional longitudinal evaluation of palatal vault changes in growing subjects. *The Angle Orthodontist*. 2011 Oct 19;82(4):632-6.
  25. Kumar S, Singla A, Sharma R, Viridi MS, Anupam A, Mittal B. Skeletal maturation evaluation using mandibular second molar calcification stages. *The Angle Orthodontist*. 2011 Sep 7;82(3):501-6.
  26. Fricke-Zech S, Gruber RM, Dullin C, Zapf A, Kramer FJ, Kubein-Meesenburg D, Hahn W. Measurement of the midpalatal suture width: A comparison of flat-panel volume computed tomography to histomorphometric analysis in a porcine model. *The Angle Orthodontist*. 2011 Aug 3;82(1):145-50.
  27. Santiago RC, de Miranda Costa LF, Vitral RW, Fraga MR, Bolognese AM, Maia LC. Cervical vertebral maturation as a biologic indicator of skeletal maturity. *Angle Orthod*. 2012;82:1123-31.
  28. Hegde DY, Baliga S, Yeluri R, Munshi AK. Digital radiograph of the middle phalanx of the third finger (MP3) region as a tool for skeletal maturity assessment. *Indian Journal of Dental Research*. 2012 Jul 1;23(4):447.
  29. Angelieri F, Cevidanes LH, Franchi L, Gonçalves JR, Benavides E, McNamara Jr JA. Midpalatal suture maturation: classification method for individual assessment before rapid maxillary expansion. *American Journal of Orthodontics and Dentofacial Orthopedics*. 2013 Nov 1;144(5):759-69.
  30. de Melo MD, Melo SL, Zanet TG, Fenyó-Pereira M. Digital radiographic evaluation of the midpalatal suture in patients submitted to rapid maxillary expansion. *Indian Journal of Dental Research*. 2013 Jan 1;24(1):76.
  31. Beit P, Peltomäki T, Schätzle M, Signorelli L, Patcas R. Evaluating the agreement of skeletal age assessment based on hand-wrist and cervical vertebrae radiography. *American Journal of Orthodontics and Dentofacial Orthopedics*. 2013 Dec 1;144(6):838.
  32. Sinha S, Umapathy D, Shashikanth MC, Misra N, Mehra A, Singh AK. Dental age estimation by Demirjian's and Nolla's method: A comparative study among children attending a dental college in Lucknow (UP). *Journal of Indian Academy of Oral Medicine and Radiology*. 2014 Jul 1;26(3):279.
  33. Angelieri F, Franchi L, Cevidanes LH, McNamara Jr JA. Diagnostic performance of skeletal maturity for the assessment of midpalatal suture maturation. *American Journal of Orthodontics and Dentofacial Orthopedics*. 2015 Dec 1;148(6):1010-6.
  34. Liu S, Xu T, Zou W. Effects of rapid maxillary expansion on the midpalatal suture: a systematic review.

- European journal of orthodontics.2015 Feb 20;37(6):651-5.
35. Angelieri F, Franchi L, Cevidanes LH, Bueno-Silva B, McNamara Jr JA. Prediction of rapid maxillary expansion by assessing the maturation of the midpalatal suture on cone beam CT. *Dental press journal of orthodontics*. 2016 Dec;21(6):115-25.
36. Jang HI, Kim SC, Chae JM, Kang KH, Cho JW, Chang NY, Lee KY, Cho JH. Relationship between maturation indices and morphology of the midpalatal suture obtained using cone-beam computed tomography images. *The Korean Journal of Orthodontics*. 2016 Nov 1;46(6):345-55.
37. Perinetti G, Sbardella V, Contardo L. Diagnostic reliability of the third finger middle phalanx maturation (MPM) method in the identification of the mandibular growth peak. *European journal of orthodontics*. 2017 Apr 1;39(2):194-201.
38. Tonello DL, de Miranda Ladewig V, Guedes FP, Conti AC, Almeida-Pedrin RR, Capelozza-Filho L. Midpalatal suture maturation in 11-to 15-year-olds: A cone-beam computed tomographic study. *American Journal of Orthodontics and Dentofacial Orthopedics*. 2017 Jul 1;152(1):42-8.
39. Grünheid T, Larson CE, Larson BE. Midpalatal suture density ratio: A novel predictor of skeletal response to rapid maxillary expansion. *American Journal of Orthodontics and Dentofacial Orthopedics*. 2017 Feb 1;151(2):267-76.
40. Angelieri F, Franchi L, Cevidanes LH, Gonçalves JR, Nieri M, Wolford LM, McNamara Jr JA. Cone beam computed tomography evaluation of midpalatal suture maturation in adults. *International journal of oral and maxillofacial surgery*. 2017 Dec 1;46(12):1557-61.

**How to cite this article:**

RevathiSomasundaram *et al* (2022) 'Correlation of CBCT Midpalatal Suture Morphology With Second Molar Calcification, CVMI and MP3 Skeletal Maturity Indicators', *International Journal of Current Advanced Research*, 11(01), pp. 156-162.  
DOI: <http://dx.doi.org/10.24327/ijcar.2022.162.0034>

\*\*\*\*\*