

**FORGED DEATH CERTIFICATE UNEARTHED THE RACKET OF CRIMINAL ABORTIONS FOR FETICIDE**

**Dheeraj Abhaykumar Binodkumar., Sandeep Kumar Giri., Rupyjoti Medhi and Pankaj Suresh Ghormade**

Dept. of Forensic Medicine, All India Institute of Medical Sciences, Raipur, Chhattisgarh.

**ARTICLE INFO**

**Article History:**

Received 14<sup>th</sup> July, 2021

Received in revised form 29<sup>th</sup>

August, 2021

Accepted 05<sup>th</sup> September, 2021

Published online 28<sup>th</sup> October, 2021

**Key words:**

Ectopic pregnancy, criminal abortion, medical certification of cause of death(MCCD), medical termination of Pregnancy (MTP) Act.

**ABSTRACT**

The incidence of maternal mortality in cases of ectopic pregnancy in developing countries is much higher as compared to the developed ones. Identifying and certifying the accurate cause of death is of paramount importance in these cases. Despite of liberal amendments in medical termination of Pregnancy (MTP) Act, the practice of illegal abortion in India has not yet been curtailed off. Sex selection of fetus in view of getting rid of unwanted female child is the main reason for such incidences.

We have encountered a case of death due to traumatic rupture of undiagnosed ectopic pregnancy during attempted criminal abortion. The alleged crime was unearthed due to improper illegal death certificate.

Copyright©2021 *Dheeraj Abhaykumar Binodkumar et al.* This is an open access article distributed under the Creative Commons Attribution License, which permits unrestricted use, distribution, and reproduction in any medium, provided the original work is properly cited.

**INTRODUCTION**

When a fertilised ovum implants outside the normal uterine cavity it is known as Ectopic Pregnancy. <sup>(1)</sup>In the developed world, between 1% to 2% of all reported pregnancies are ectopic. <sup>(2)</sup>In the developing world, it has been estimated that 10% of women admitted to hospital with a diagnosis of ectopic pregnancy ultimately die from the condition due to internal bleeding caused by spontaneous rupture. <sup>(3)</sup>


Abortion means premature expulsion of foetus from mother's womb at any time of pregnancy, before the term pregnancy is completed. Unlawfully induced destruction and expulsion of foetus from mother's womb is Criminal (Illegal) abortion. It is procured by either abortifacient drugs, general violence or local violence. The local violent methods include syringing, rupturing of membranes, dilatation of cervix, abortion stick, syringe aspiration etc. Illegal abortion can lead to various complications such as peritoneal hemorrhage, air embolism, peritonitis, perforation of uterus. <sup>(4)</sup>

In the age of modernized ultrasound, female feticide is still a social hazard of significance. As female feticide is still common in various parts of India. As per the National Crime Records Bureau (NCRB) 2019, there were 97 cases of

infanticide and 123 of feticide per 10 lakh population. <sup>(5)</sup> We had autopsied a tragic case of pregnant lady died during attempted criminal abortion done for feticide by unauthorised unskilled abortionist, findings of which are presented herewith.

**Case Description**

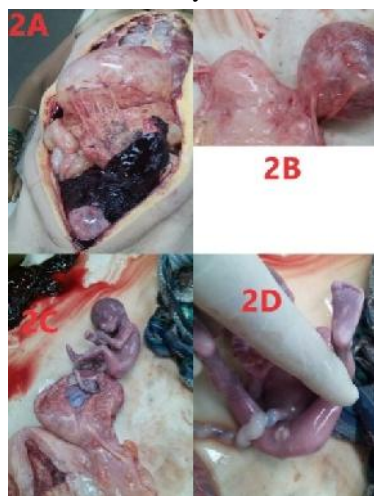In the month of March 2017, a person came to the department of casualty of district hospital requesting to keep the dead body of his wife in the cold storage facility. The husband was carrying a "cause of death" certificate issued by the physician who was treating his wife. The death certificate was not in the prescribed MCCD format. It was issued on a sheet of notebook signed by treating registered homeopathic practitioner from nearby suburb.(Image 1)



**Image 1**

\*Corresponding author: **Dheeraj Abhaykumar Binodkumar**  
Dept. of Forensic Medicine, All India Institute of Medical Sciences,  
Raipur, Chhattisgarh.

One of the on duty doctor rejected the above-mentioned cause of death certificate. Suspecting some foul play, this incidence was immediately reported to the concerned police station as medicolegal case requiring investigation by the police. Subsequently medico-legal postmortem examination was ordered by the investigation authority to confirm the cause and manner of death on the same day.



**Image** 2A-Peritoneal cavity showing blood clots and fluid blood. 2B- Showing puncture at left fallopian tube. 2C-Hemorrhagic clot in uterus and ectopic pregnancy. 2D-Fetal Genitalia.

### Autopsy Findings

Postmortem interval was 8 hours. The body of the adult female having BMI 20 was pale with gross distension of abdomen. No bodily injuries were noted on external examination. On dissection, the stomach and intestine were filled with gas. Abdominal cavity showed presence of blood clots weighing 900 grams and fluid blood measuring 1000 ml (Image 2A). The uterus was enlarged measuring 17cm x 12cm x 7cm on gross examination. The weight of the uterus with the fallopian tubes and ovaries was 657 gm. Uterine cavity had 100 ml of clotted blood. Surprisingly, a puncture mark measuring 0.2cm having hemorrhagic margins was noted at the left isthmus of the uterus on its antero-superior surface suggestive of some kind of intervention though intrauterine route (Image 2B).

On further dissection of the left fallopian tube, evidence of ectopic pregnancy was noted. A dead fetus measuring 23 cm in length and weighing 228 gm was found with intact umbilical cord, the placenta was attached to the antero-superior wall of the fallopian tube near the isthmus (Image 2C). On examination of fetus, eyes were identifiable, external ears well formed, nails of hands and feet identifiable and external genitalia was easily distinguished as male fetus (Image 2D). Findings in fetus were suggestive of gestational age of about 5 months. Remaining organs were unremarkable.

Chemical analysis did not reveal any intoxicant or drug in the body. Histopathological examination confirmed tubal pregnancy in isthmus region and rupture of the fallopian tube at the site of placental implantation. Thus the cause of death was opined as "Hemorrhagic shock due to traumatic intra-abdominal rupture of site of ectopic pregnancy in left fallopian tube".

Husband of the deceased pregnant female had intentionally concealed all the information regarding her pregnancy and alleged attempt of criminal abortion that eventually had fatal

outcome. No antenatal radiological reports were available diagnosing the tubal ectopic pregnancy.

### DISCUSSION

Criminal abortion is unlawful expulsion of products of conception from the uterus, outside the provisions of MTP Act, 1971. It may include (1) Abortion by unqualified personnel & at unregistered place; (2) Abortions for indications other than those mentioned in the act; (3) Abortion after prescribed period of pregnancy without any therapeutic indications.<sup>(9)</sup>

Post mortem findings in this case were indicative of illegal therapeutic intervention by unskilled abortionist for conducting criminal abortion through intrauterine route that led to fatal complications arising out of rupture at the site of undiagnosed tubal ectopic pregnancy. Abortionist was not qualified; hence he did not bother to confirm the location of pregnancy before attempting procedure. Abortionist physician tried to hide the crime by the way of issuing false and improper death certificate certifying cause of death. It was issued on a sheet of paper in a haphazard manner bearing merely the signature & name of the physician, which was hand written, no proper stamp of either the hospital or the physician was embossed. Hence, the forged death certificate raising doubt about cause of death immediately caught the attention of consultant on duty and therefore the post-mortem examination was conducted.

Instruction to implement MCCD have been issued in the year 2012 to all States/UTs, under Civil Registration System. As per Section 10(3) of Births and Deaths Registration Act, 1969 a cause of death certificate shall be obtained from the registered medical practitioner who attended the patient during his last illness. The certificate as to the cause of death required under sub-section (3) of Section 10 shall be issued in Form No.4 for institutional deaths and 4A for non-institutional deaths. The medical practitioner shall, issue such certificate without charging any fee, to the person required under this Act. Certificate shall be delivered by such person to the Registrar at the time of giving information concerning the death.<sup>(6)</sup>

However, MCCD scheme in India to streamline the nationwide mortality data is not strictly followed and facing hurdles as Ganasva AS *et al.* found that, out of total 1947 MCCD forms issued, only 21 certificates were completely filled. Whereas, 1877 were notably incomplete, 4 were slightly incomplete and 45 were grossly incomplete.<sup>(7)</sup>

Likewise, Lanjewar S *et al.* also observed that, out of all death certificates, 133 were completely filled of which 110 had mentioned accurate cause of death; while 23 had inaccurately filled cause of death.<sup>(8)</sup>

As per the rules, MCCD certificate can be issued and duly signed by any Registered Medical Practitioner (RMP) who is having a valid qualification as per Section 2 (h) of Indian Medical Council Act 1956.<sup>(9)</sup>

Punishment is prescribed for issuing false certificate that also includes medical certificate under section 197 of Indian Penal Code. We did not find a single case report even after an extensive literature search, in which fake MCCD certificate was used to hide crime of maternal death after attempted criminal abortion. This clearly shows under or no reporting of such incidences despite of the fact that authorities are trying hard for implementation of all the relevant acts.

In our case, the female was 3<sup>rd</sup> gravida with two living female children (G<sub>3</sub>P<sub>2</sub>A<sub>0</sub>). Hence, the couple desirous of knowing sex of the foetus, was misled by the abortionist about the sex of the foetus in her womb as female and forced her to go for illegal criminal abortion in his unauthorised clinic just for monetary gains.

Female feticide by means of illegal criminal abortion at unauthorised clinic violating rules of pre conception and prenatal diagnostic techniques act and MTP act is not infrequent in Indian set up, when the pregnancy reaches a stage at which determination of sex of foetus is possible by ultrasonography(USG). Similarly in our case, gestational age of foetus was about 5 months at which determination of sex is possible on USG and it seem that couple was aware of this fact and their desperation for sex determination of their foetus for the sake of having male child was further exploited by the physician.

With the help of evidences obtained from this crucial autopsy report, case was further investigated by the police and unearthed the shocking racket of illegal criminal abortions ran by the unskilled abortionist at his unauthorised centre. The motive of this racket was to lure pregnant female with the assurance of sex determination of foetus in womb to which the victim of this case fell prey too, and allegedly undergone criminal abortion believing that she was carrying a female foetus. Later on, many foetal remains were recovered from the premises of the hospital, where the deceased had undergone abortion and was issued death certificate to her husband. <sup>(10)</sup>

## CONCLUSION

The case highlights the rare incidence in which an attempt was made to hide the heinous crime of death due to criminal abortion by using forged MCCD certificate.

Due to prompt detection of forged improper death certificate and immediate action, it was possible to bust the humongous racket of illegal abortion for female feticide. This can be attributed to strict implementation of MCCD at our hospital. With this case, authors want to bring to notice about uniform implementation of MCCD scheme with proper surveillance and data monitoring for prevention of such incidences.

## References

1. Walker JJ. Ectopic pregnancy. ClinObstetGynecol 2007; 50:89–99.
2. Goldner TE, Lawson HW, Xia Z, *et al.* Surveillance for ectopic pregnancy – United States, 1970–1989. MMWR CDC SurveillSumm1993;42:73–85.
3. Leke RJ, Goyaux N, Matsuda T, *et al.* Ectopic pregnancy in Africa: a population-based study. ObstetGynecol2004;103:692–697.
4. Reddy KSN, Abortion, The Synopsis of Forensic Medicine and Toxicology, 28<sup>th</sup> edition, Jaypee brothers medical publishers, 2014: 211-18.
5. Crime in India 2019 Statistics Volume 1, National Crime Records Bureau, Ministry of Home Affairs, India.
6. Physicians' manual on medical certification medical certification of cause of death, New Delhi, India, 2012 Registrar General & Census Commissioner, India.
7. Ganasva A.S, Bariya B.R, Shringarpure K, Damor J.R. assesment of medical certificate of cause of death (mccd) in vadodara municipal corporation, gujarat, india, Int J Cur Res Rev 2015; 7(24):19-23.
8. Lanjewar S, Kubde S. Medical Certification of Cause of Death in a Tertiary Care Centre, A matter of concern?, Int J Sci, 2013;2(10):1-3.
9. Medical Termination of Pregnancy Act, 1971.India.
10. Agents of death: female foeticide in Maharashtra, 28/03/2017, 17:40 IST, The Hindu.

### How to cite this article:

Dheeraj Abhaykumar Binodkumar *et al* (2021) 'Forged Death Certificate Unearthed The Racket Of Criminal Abortions For Feticide', *International Journal of Current Advanced Research*, 10(10), pp. 25312-25314.  
DOI: <http://dx.doi.org/10.24327/ijcar.2021.25314.5051>

\*\*\*\*\*