



**A RARE CASE OF SEVERE THROMBOCYTOPENIA AS HARBINGER OF
BASEDOW'S DISEASE**

Vallish Shenoy* and Ravi K

Department of Medicine, Bangalore Medical College and Research Institute, KR Road, Bengaluru.
Karnataka, India

ARTICLE INFO

Article History:

Received 10th January, 2021

Received in revised form 2nd
February, 2021

Accepted 26th March, 2021

Published online 28th April, 2021

ABSTRACT

An association between thrombocytopenia and thyrotoxicosis has been reported but its mechanism is unclear. Graves' disease also known as Basedow's disease is an autoimmune form of primary hyperthyroidism. It presents with various clinical features like eye signs, tachycardia, weight loss, skin changes etc. However, initial presentation of Graves' disease with a haematological abnormality like thrombocytopenia is very rare. Here; we present the case of a 32-year-old male who presented with severe thrombocytopenia with unknown underlying Hyperthyroidism.

Key words:

Graves disease, Thrombocytopenia, ocular signs

Copyright©2021 Vallish Shenoy and Ravi K. This is an open access article distributed under the Creative Commons Attribution License, which permits unrestricted use, distribution, and reproduction in any medium, provided the original work is properly cited.

INTRODUCTION

Graves' disease is a complex syndrome which comprises of enlarged overactive thyroid gland, accelerated heart rate and ocular abnormalities. It is the most common cause of hyperthyroidism with an annual incidence of 20 to 50 cases per 100,000 persons.⁽¹⁾ Critical for our current understanding of this disease was the discovery of its autoimmune basis, which results from complex interactions between genetic and environmental factors⁽²⁾. Due to its autoimmune origin, hyperthyroidism seems to be associated with thrombocytopenia. Thrombocytopenia when unrecognized may present with severe manifestations such as bleeding from nasal mucosal vascular plexus (Epistaxis), gastrointestinal tract (Hematemesis, melena) and in the intracranial vault (Hemorrhagic stroke) which can be devastating if the cause is not recognized and treated early. Very few reports are available regarding the association between the two conditions. Here, we present a case of severe thrombocytopenia which presented to us with epistaxis and on evaluation was found to have underlying hyperthyroidism, which was eventually treated with good outcome, thus showing the importance of Graves' disease in the differential diagnosis of patients presenting with thrombocytopenia.

CASE REPORT

History

A 32 year old male, non-smoker, non-alcoholic, taxi driver by occupation with no co-morbidities presented to our out-patient department with complaints of fever, sore throat, dry skin, weight loss and fatigue since 6 weeks and epistaxis and pinpoint rash since 2 days. There was no history of blood transfusion or high risk behaviour or weight loss. There was no history of any joint pains preceding the illness.

There was no significant past history of any lung infections or any family history of rheumatological/connective tissue disorders or tuberculosis.

Examination

On general examination, the patient was emaciated, febrile, tachypneic with respiratory rate of 22/min, resting pulse of 115 beats/min which was regular, blood pressure of 130/84 mm Hg and oxygen saturation SpO₂ of 96% at room air. On further inspection, presence of conjunctival and nailbed pallor, bald glossy tongue, petechial rash over chest, abdomen and extremities; Von Graefe's sign (Lid lag on downgaze), Dalrymple's sign (Lid retraction), Joffroy's sign (Loss of forehead corrugation on upgaze), Stellwag's sign (Staring look with infrequent blinking) (Fig 1) and exophthalmos was confirmed using Hertel's Exophthalmometer, tremors on outstretched hands and thyroid swelling was noted on palpation.

*Corresponding author: **Vallish Shenoy**

Department of Medicine, Bangalore Medical College and Research Institute, KR Road, Bengaluru. Karnataka, India

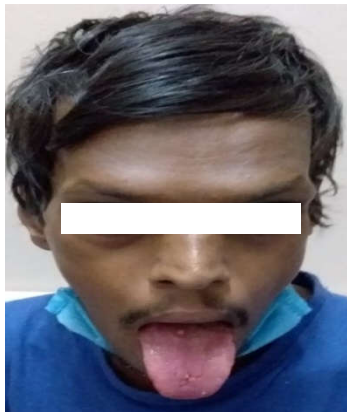

Fig 1 Ocular signs- Dalrymple's sign, Stellwag's sign, Exophthalmos and Bald furrowed tongue are seen.

On systemic examination, respiratory, neurological and per abdominal parameters were normal except an ejection systolic murmur in the pulmonic valve area on cardiovascular examination.

Investigations

Initial laboratory work up done in our hospital revealed haemoglobin of 9.1g/dl, total leukocyte count of 8,260 cells/cumm (normal differential count) and platelet count of 10,000 cells/cumm. Peripheral smear revealed microcytic hypochromic anaemia with reactive atypical lymphocytes and thrombocytopenia. (Fig 2). Erythrocyte sedimentation rate was 60 mm in first hour. Serum ferritin was 36.48 ng/ml. Coagulation profile was normal with PT/INR- 12.1/1.18, APTT-25.2 and D-dimer- 0.035mcg/mL. Reticulocyte count (corrected) was 1.08% and Mean platelet volume (MPV) was 10.0. Serum Vitamin B12 and Folate levels were normal. Direct and Indirect Coomb's test was negative. Rheumatoid factor and Antinuclear factor was negative, liver and kidney function tests were within normal limits. Ultrasonography of abdomen did not reveal any evidence of chronic liver disease or any mass lesion. Viral serology was negative. RT-PCR for COVID-19 was negative. Chest X-ray and HRCT thorax was unremarkable. In view of his emaciated condition, thyroid swelling, exophthalmos and resting tachycardia, thyroid function was requested. His was TSH 0.001mIU/ml (N: 0.5-5.5mIU/ml), total T3 320.05 ng/dl (N: 80-180ng/dl) and total T4 124.5 (N: 4.5-12.5mcg/dl). Ultrasonography of neck revealed bulky and altered echotexture of thyroid with increased vascularity suggestive of Graves' thyroiditis.

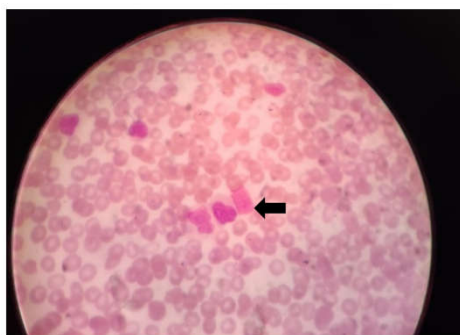


Fig 2 Peripheral smear showing microcytic, hypochromic anaemia with reactive lymphocytes (arrow) and thrombocytopenia

Treatment

Due to low platelet count and epistaxis, the patient underwent 12 units of platelet transfusion following which he was diagnosed with Graves' disease and started on oral carbimazole

30 mg per day along with propranolol tablet 20mg per day. As it was still not known whether his thrombocytopenia was related to Graves' disease, bone marrow study during follow up was planned if thrombocytopenia did not resolve. During follow up at one month his platelet count had gone up to 96,000cells/cumm. There had been no new bleeding episodes. His body-weight had also increased by 4.7 kg. He has been on anti-thyroid medication since last three months and has maintained platelet count of 150,000 to 200,000 cells/cumm. As a result of which, his thrombocytopenia seem to be related to Graves' disease.

DISCUSSION

Association of Grave's disease with severe thrombocytopenia is a rare condition with only a few case reports recorded where thrombocytopenia was seen as initial presentation of Graves' disease⁽³⁾. Thrombocytopenia in Graves disease can happen due to two different or co-existing mechanism such as increased destruction of the platelets due to elevated thyroid hormone levels leading to activation of the reticuloendothelial system and/or the autoimmune phenomenon affecting platelets. In our case we hypothesize that the thrombocytopenia seen in our patient was secondary to increase reticuloendothelial destruction stimulated by high thyroid hormone level rather than autoimmunity because autoimmune profile was negative and patient had good improvement on initiation of anti-thyroid medication without the need of steroid induction. In the work up of a case of thrombocytopenia, thyroid function test is not done unless the patient presents with florid signs like ophthalmopathy or goitre. In the absence of these signs, high degree of clinical suspicion is needed to diagnose the underlying Graves' disease⁽⁶⁾.The underlying pathophysiology of the association of the two conditions is not clear. Cordiano *et al.* found that approximately 80% patients with hyperthyroidism and thrombocytopenia had platelet autoantibodies⁽⁴⁾. In patients with Graves' disease presenting with thrombocytopenia, platelet count responds to anti-thyroid therapy.⁽⁵⁾ Our patient had a significant rise in platelet count following carbimazole therapy and became transfusion independent.

CONCLUSION

This case demonstrates the intriguing association of Graves' disease and thrombocytopenia requiring anti-thyroid medication for the reversal of thrombocytopenia and symptoms of hyperthyroidism. As a result, in a case of refractory thrombocytopenia when the usual secondary causes are negated, a thyroid profile may be of help in diagnosing Graves' disease. In this case, use of anti-thyroid medication corrected thrombocytopenia.

References

1. Zimmermann MB, Boelaert K. Iodine deficiency and thyroid disorders. *Lancet Diabetes Endocrinol* 2015; 3:286-95.
2. Tomer Y. Mechanisms of autoimmune thyroid diseases: from genetics to epigenetics. *Annu Rev Pathol* 2014; 9:147-56.
3. Marta GM, de Campos FP. Immune thrombocytopenia and autoimmune thyroid disease: a controversial overlap. *Autops Case Rep* 2015; 5:45 8.
4. Cordiano I, Betterle C, Spadaccino CA, Soini B, Girolami A, and Fabris F. Autoimmune

- thrombocytopenia (AITP) and thyroid autoimmune disease (TAD): overlapping syndromes? *Clinical and Experimental Immunology* 1998; 113:373-8.
5. Sugimoto K, Sasaki M, Isobe Y, Tamayose K, Hieda M, Oshimi K. Improvement of idiopathic thrombocytopenic purpura by antithyroid therapy. *Eur J Haematol* 2005; 74:73-4.
 6. Paul R, Rudrajit R *et al.* Thrombocytopenia as Harbinger of Graves' Disease: A Rare Presentation. *The Journal of the Association of Physicians of India* 2017; 65. 102.

How to cite this article:

Vallish Shenoy and Ravi K (2021) 'A rare case of Severe Thrombocytopenia As Harbinger of Basedow's Disease', *International Journal of Current Advanced Research*, 10(04), pp. 24159-24161.
DOI: <http://dx.doi.org/10.24327/ijcar.2021.24161.4788>
