

## **A VERSATILE MODIFICATION OF PALATAL FLAP FOR CLOSURE OF ORO ANTRAL FISTULA**

**Shallu Bansal<sup>1</sup> and Kaushal Charan Pahari<sup>2</sup>**

<sup>1</sup>Department of Oral & Maxillofacial Surgery Swargiya Dada Saheb Kalmegh Smruti Dental College & Hospital Nagpur, India

<sup>2</sup>Private Practitioner Kumar Nursing Home Bihar

### **ARTICLE INFO**

**Article History:**

Received 12<sup>th</sup> September, 2020

Received in revised form 23<sup>rd</sup>

October, 2020

Accepted 7<sup>th</sup> November, 2020

Published online 28<sup>th</sup> December, 2020

### **ABSTRACT**

The literature is full of various techniques to close oro antral communication. Various local and distant flaps are available with or without graft materials to treat the same. In local flaps we can use buccal flap, palatal flap or combination of both. In the present case, we modified the palatal advancement flap to close the oro-antral communication.

**Key words:**

Oroantral communication, palatal flap, modified palatal approach

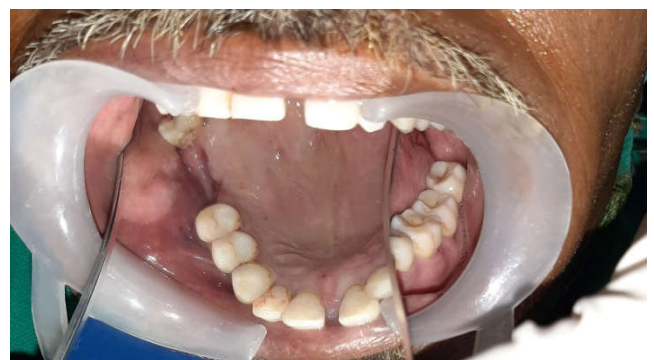*Copyright©2020 Shallu Bansal and Kaushal Charan Pahari. This is an open access article distributed under the Creative Commons Attribution License, which permits unrestricted use, distribution, and reproduction in any medium, provided the original work is properly cited.*

### **INTRODUCTION**

Oro antral communication is a well-known complication post trauma, post-surgery, after upper third molar disimpaction, extraction, radiation, infection, cyst or neoplasm.<sup>1</sup> The literature is full of various techniques to close oroantral communication. The choice of each of these procedures is influenced by size of the defect, location of the defect, any previous attempt and the condition of the tissue available for the repair.<sup>1</sup> Various local and distant flaps are available with or without graft materials to treat the same. In local flaps we can use buccal flap, palatal flap or combination of both. Palatal flap had been further classified as straight advancement, island flap, hinged flap, rotational advancement flap, submucosal connective tissue pedicle flap and submucosal island flap.<sup>4</sup> Palatal flap is less elastic, but they are thicker than buccal tissue, simple and versatile and mobility of the palatal flap is reasonable. The abundant blood supply to the palatal tissue promote satisfactory healing of the flap. The added advantage of the palatal flap is that they don't affect the buccal vestibule height and is associated with minimal discomfort during healing<sup>1, 2, 3, 4, .</sup> In the present case; we modified the palatal advancement flap to close the oro-antral communication (OAC).

### **CASE REPORT**

A 48 years old male reported to our department with a chief complaint of regurgitation of fluid through nose post extraction of right side upper first and second molar at a private dental clinic (figure 1).



**Figure 1** Intra oral pre- operative picture

Closure of OAC was done on the same day with buccal advancement flap and buccal pad of fat immediately after extraction, but patient was not relieved. Patient had been explained regarding the palatal rotation flap and the secondary healing area on the palate, but patient denied considering it. Considering the patient psychology, the decision was taken to use modified technique to reduce the post-operative discomfort and healing time. Patient was operated under local anaesthesia, the fistula was excised with the 11 no blade and the granular tissue was curated, crevicular incision was given at the palatal

**\*Corresponding author: Shallu Bansal**

Department of Oral & Maxillofacial Surgery Swargiya Dada Saheb Kalmegh Smruti Dental College & Hospital Nagpur, India

site and a parallel incision was given towards the midline beyond the greater palatine artery, full thickness mucoperiosteal flap elevation was done and the flap was tunnelled and repositioned buccally (figure 2 & 3).

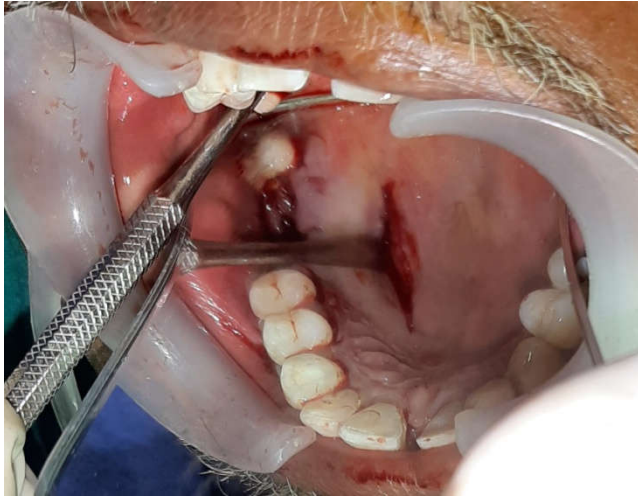


Figure 2 Intra operative picture showing the parallel incision towards the midline.

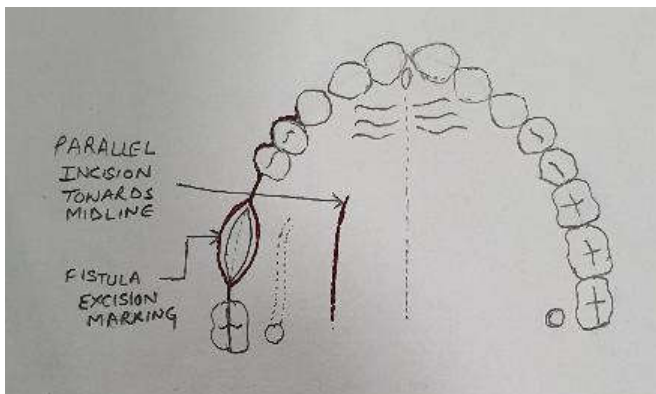


Figure 3 Diagrammatic presentation of incision

Vertical mattress sutures were given with 4-0 silk and the sutures were removed on 10<sup>th</sup> day post operatively. The patient was followed up for one month (figure 4).

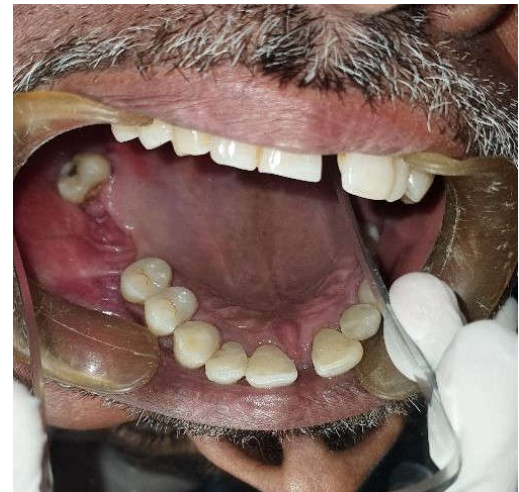


Figure 4 Intra oral one-month post-operative picture

## CONCLUSION

The above mentioned technique for closure of OAC is a modification of previous lateral sliding technique with satisfactory results.

## Acknowledgement

Author is thankful to Prof. Dr. Dinesh K Verma for his valuable suggestions in manuscript writing.

## Funding

No author received any material or financial gain or personal advancement in the production of this manuscript

## Conflict of interest

None

## Ethical approval

Not required

## Patient consent

Written consent was obtained prior to case.

## References

1. MN Awang. Closure of oro antral fistula. *Int J Oral Maxillofac Surg.* 1988; 17: 110-115.
2. P Puria, O Karina, S Robert, B Jurgens, S Frank, S Loutfi. Surgical option in oroantral fistula management: A narrative review. *Int J of Implant dent.* 2018; 4 (1):40.
3. Genden EM, Lee BB, Urken ML. The palatal island flap for reconstruction of palatal and retromolar trigone defects revisited. *Arch Otolaryngol Head Neck Surg.* 2001;127(7):837-841.
4. Salins PC, Kishore SK. Anteriorly based palatal flap for closure of large oroantral fistula. *Oral Surg Oral Med Oral Pathol Oral Radiol Endod.* 1996; 82:253-256.

### How to cite this article:

Shallu Bansal and Kaushal Charan Pahari (2020) 'A Versatile Modification of Palatal Flap for Closure of Oro antral fistula', *International Journal of Current Advanced Research*, 09(12), pp. 23430-23431.  
DOI: <http://dx.doi.org/10.24327/ijcar.2020.23431.4639>

\*\*\*\*\*